Table of Contents

Acknowledgements (iii)
List of figures, boxes, tables and graphs (v, vi)
Abstract 1
Introduction 3
CHAPTER 1: Background Information
1.1: Dental anatomy and physiology of the domestic rabbits 5
1.2: Dental disease in pet rabbits 25
1.3: Progressive syndrome of acquired dental disease in pet rabbits (PSADD) 34
1.4: General overview of calcium metabolism and metabolic bone disease 38
1.5: Aspects of calcium metabolism and metabolic bone disease in rabbits 44
1.6: The diet and husbandry of pet rabbits 47
CHAPTER 2: Investigation of the progressive syndrome of acquired dental disease (PSADD) in pet rabbits
2.1: Comparative study of morphological features of skulls of rabbits with and without dental disease 49
2.2: Comparative study of radiological features of skulls of rabbits with and without dental disease 55
2.3: Comparative study of the vertebral column of rabbits with and without dental disease 60
2.4: Data analysis of rabbits presented for veterinary treatment 61
2.5: Examination of the collection of rabbit skulls at the Natural History Museum 62
2.6: Other investigations 63
CHAPTER 3: Results
3.1: Results of morphological study of skulls of rabbits with and without dental disease 65
3.2: Summary of results of morphological examination of skulls 75
3.3: Results of comparative study of teeth from skulls of rabbits with and without dental disease 85
3.4: Results of the study of radiological features of dismembered prepared skulls and teeth of rabbits with and without dental disease 88
3.5: Results of radiological features of skulls of rabbits with and without dental disease 94
3.6: Summary of results of radiological features of skulls of rabbits with and without dental disease 110
3.7: Results of the comparative radiological study of the vertebral column of rabbits with and without dental disease 120
3.8: Results of data analysis of rabbits presented for veterinary treatment 122
3.9: Results of examination of skulls at Natural History Museum 126
CHAPTER 4: Discussion 128
Conclusion 145
Appendices
1: References 147
2: Glossary 148
3: Grading systems 161
4: Raw data 163
5: Supporting papers 174

Acknowledgements

The illustration on the title page was drawn by John Naylor, a client and wildlife artist, who also drew a peregrine falcon for my husband Nigel's FRCVS thesis in 1994. John Naylor can be contacted at Langarth Cottage, Ratten Row, Langtoft, Driffield, E.Yorks.

The preparation and writing of this thesis has largely been a solitary process but I am grateful to many people who have offered their encouragement and support. Firstly I would like to thank my tutor, Dr Allison Gleadhill, for her advice and assistance.

I would also like to thank the nursing staff at the practice; Marlene Alderson, Lise Seiersen, Donna Marie McCooke, Julia Heaton, Anna Thornhill and Ciara Coyle. These people have tolerated my studies, often at unsociable hours, with forbearance and patience.

I am indebted to Professor Wim Weijs of the Department of Veterinary Anatomy at the University of Utrecht. He has published widely on rabbit mastication and his discussions with me were very helpful. I also appreciated access to his library and his literature.

I am grateful to Daphne Hills and Richard Sabin of the Mammal Section of the Natural History Museum in London for their help and advice during my visit to examine the collection of skulls of *Oryctolagus cuniculus.*

My eldest daughter, Kate, has helped me enormously. She has listened to my problems and offered solutions. She has performed statistical analyses and guided me through the complexities of computer programs, such as Adobe Illustrator, to lay out and label the images. The layout of the illustrations is based on the pictures of foraminifera that are included in Kate's own PhD thesis. My other children, Tom, Georgina and Sally also deserve thanks for their tolerance of my preoccupation and absences from family life during the production of this thesis.

Lastly, and most importantly, I thank my husband, Nigel. He has goaded and encouraged me to follow the same path that he trod a decade ago when he produced his own Fellowship thesis. I would and could not have completed this task without him.

FIGURES

Figure 1: Dentition of the domestic rabbit (*Oryctolagus cuniculus*) 7
Figure 2: Course of the trigeminal nerve in the domestic rabbit (*Oryctolagus cuniculus)* 9
Figure 3: Transverse section through a maxillary cheek tooth (a) and mandibular cheek tooth (b) 10
Figure 4: Diagram of the structure of a premolar of a rabbit 11
Figure 5: Dental wear 13
Figure 6: The occlusal relationship of the cheek teeth 14
Figure 7: Cheek teeth of the domestic rabbit (*Oryctolagus cuniculus)* 15
Figure 8: Resting occlusal position of the cheek teeth 16
Figure 9: Biting action of the incisors 17
Figure 10: Interlocking mechanism between upper and lower ridges of the cheek teeth during mastication in the domestic rabbit (*Oryctolagus cuniculus*) 18
Figure 11: Jaw movement during the (Type II) chewing cycle of the domestic rabbit (*Oryctolagus cuniculus*) 19
Figure 12: Dorsoventral views of mandibular positions at start (dashed outline) and end of crushing (A) and shearing (B) power strokes 20
Figure 13: Vertical component of the trajectory of the incisors during cheek tooth mastication 21
Figure 14: Anatomical features of the skull of the domestic rabbit (*Oryctolagus cuniculus*)
14a: Lateral aspect of left mandible 22
14a: Lateral aspect of the skull 22
14a: Ventral aspect of the skull 23
14a: Dorsal aspect of the skull 24
Figure 15: Anatomy of nasolacrimal duct 24
Figure 16: Examples of abnormalities of the incisors that may be detected during clinical examination 27
Figure 17: Examples of abnormalities of the cheek teeth 29
Figure 18: Typical sites on the skull of bone penetration by elongated tooth roots 30
Figure 19: Facial abscesses 31
Figure 20: Clinical conditions associated with underlying dental disease 33
Figure 21: Some causes of dental disease in pet rabbits 35
Figure 22: 'Flopsy Nicholls'. Case report to show progression of acquired dental disease 37
Figure 23: Calcium circulation in rabbits 46
Figure 24: Classification of incisor occlusion 51
Figure 25: Measurement .parameters of hemimandibles from wild rabbits 52
Figure 26: Difficulties associated with measuring crown length 53
Figure 27: Radiological features of the lateral view of a skull of a clinically healthy (Grade 1) rabbit 57
Figure 28: Radiological features of the dorsoventral view of a skull of a clinically healthy (Grade 1) rabbit 59
Figure 29: Examples of morphological changes of the exposed crowns of the teeth in prepared skulls of pet rabbits 67
Figure 30: Examples of morphological changes in the apices of the roots of the teeth in prepared skulls of pet rabbits 69
Figure 31: Examples of grades of incisor occlusion and variations in the appearance of the bones of prepared skulls from pet rabbits 71
Figure 32: Assessment of the thickness of the bone of prepared skulls of pet rabbits 73
Figure 33: Examples of abnormal foramina, porous appearance of parietal bone and the hole in the mandibular ramus 75
Figure 34: Examples of skulls from Grade 1 rabbits 77
Figure 35: Examples of skulls from Grade 2 rabbits 79
Figure 36: Examples of skulls from Grade 3 rabbits 81
Figure 37: Examples of skulls from Grade 4 rabbits 83
Figure 38: Examples of skulls from Grade 5 rabbits 85

Figure 39: Examples of teeth from skulls of each grade 87
Figure 40: Examples of lateral view prepared hemimandibles after removal of teeth 89
Figure 41: Examples of dorsoventral view of maxillae after removal of teeth 91
Figure 42: Radiographic appearance of teeth 93
Figure 43: Variations in skull shape of adult rabbits of various breeds 95
Figure 44: Examples of radiographic changes in the incisors and classes of incisor occlusion 97
Figure 45: Examples of radiographic changes of cheek teeth 99
Figure 46: Examples of radiographic changes in the roots of the cheek teeth 101
Figure 47: Examples of radiographic changes to alveolar bulla and signs of reduced bone density 103
Figure 48: Radiographic signs of osteopaenia 105
Figure 49: Examples of radiographic appearance of upper first premolar on dorsoventral view 107
Figure 50: Radiographic appearance of periapical abscesses 109
Figure 51: Examples of radiographs of skulls of Grade 1 rabbits 111
Figure 52: Examples of radiographs of skulls of Grade 2 rabbits 113
Figure 53: Examples of radiographs of skulls of Grade 3 rabbits 115
Figure 54: Examples of radiographs of skulls of Grade 4 rabbits 117
Figure 55: Examples of radiographs of skulls of Grade 5 rabbits 119
Figure 56: Examples of the lumbar vertebrae of rabbits with and without dental disease 121
Figure 57: Examples of skulls held at Natural History Museum, London 127
Figure 58: A proposed mechanism for development of acquired dental disease due to lack of dental wear and abnormal chewing patterns 130
Figure 59: Differing descriptions of resting occlusion 131
Figure 60: Radiographs of hemimandibles of laboratory rabbits suffering from rickets 135
Figure 61: Proposed mechanism for development of acquired dental disease due to metabolic bone disease 139
Figure 62: Treatment of rabbits with PSADD 141
Figure 63: Different approaches to removing spurs from cheek teeth 142
Figure 64: Prognosis for rabbits with PSADD 143

BOXES

Box 1: Grading the progression of acquired dental disease in rabbits 36
Box 2: Calcium absorption from the small intestine 38
Box 3: Causes of osteopaenia in animals 40
Box 4 : Comparison of Dwarf breeds with non Dwarf breeds of rabbits with and without dental disease from which skulls were prepared 65

TABLES

Table 1: History of dental treatment of rabbits with periapical abscesses 108
Table 2: Gender of rabbits with and without dental disease 125

GRAPHS

Graph 1: Age distribution of rabbits with and without dental disease from which skulls were prepared (excluding wild rabbits) 65

Graph 2: Gender distribution of rabbits from which skulls were prepared (excluding wild rabbits) 65

Graph 3: Comparative changes in the exposed crowns of the cheek teeth in rabbits of different grades 66

Graph 4: Ribbing of incisors in skulls of rabbits of different grades 66

Graph 5: Changes to the apices of the tooth roots in skulls of different grades 68

Graph 6: Incidence of changes in individual teeth 68

Graph 7: Class of incisor occlusion in skulls of rabbits of different grades 70

Graph 8: Appearance of bone of skulls of rabbits of different grades of dental disease 70

Graph 9: Changes in structure and thickness of bones of skulls of rabbits of different grades of dental disease 72

Graph 10: Porous appearance and presence of hole near angular process of mandible 74

Graph 11: Incidence of abscesses in skulls of rabbits of each grade 74

Graph 12: Incidence of morphological changes in 36 skulls from Grade 1 rabbits 76

Graph 13: Incidence of morphological changes in 40 skulls from Grade 2 rabbits 78

Graph 14: Incidence of morphological changes in 23 skulls from Grade 3 rabbits 80

Graph 15: Incidence of morphological changes in 33 skulls from Grade 4 rabbits 82

Graph 16: Incidence of morphological changes in 21 skulls from Grade 5 rabbits 84

Graph 17: Number of radiographs showing 'convergance' in rabbits of each grade 94

Graph 18: Changes in the shape and structure of the incisors 96

Graph 19: Class of incisor occlusion of rabbits of different grades- assessed from radiographs 96

Graph 20: Changes in crowns of cheek teeth on lateral views of the skull of rabbits in each grade 98

Graph 21: Appearance of mesial surface of upper premolar on lateral view of the skull 98

Graph 22: Changes in cheek teeth roots on lateral skull radiographs of rabbits in each grade 100

Graph 23: Changes in alveolar bulla on lateral skull radiographs 102

Graph 24: Radiolucency at apex of lower fourth cheek tooth on skull radiographs of rabbits of each grade 102

Graph 25: Percentage of rabbits in each grade showing radiographic evidence of osteopaenia on lateral and dorsoventral skull radiographs 104

Graph 26: Appearance of upper premolar on dorsoventral view 106

Graph 27: Incidence and distribution of abscesses on lateral skull radiographs 108

Graph 28: Radiological features of the skulls of 49 Grade 1 rabbits 110

Graph 29: Radiological features of the skulls of 82 Grade 2 rabbits 112

Graph 30: Radiological features of the skulls of 49 Grade 3 rabbits 114

Graph 31: Radiological features of the skulls of 73 Grade 4 rabbits 116

Graph 32: Radiological features of the skulls of 41 Grade 5 rabbits 118

Graph 33: Breed distribution of 1254 rabbits presented for veterinary treatment 122

Graph 34: Comparison of breed distribution of rabbits requiring and not requiring dental treatment

34a: Breed distribution of 465/1254 rabbits requiring dental treatment 123

34b: Breed distribution of 789/1254 rabbits not requiring dental treatment 123

Graph 35: Comparison of incidence of dental disease in Dwarf and non-Dwarf breeds 124

Graph 36: Relative proportions of rabbits of five most popular breeds with and without dental disease 124

Graph 37: Gender distribution of rabbits with and without dental disease 125

METABOLIC BONE DISEASE AS A POSSIBLE CAUSE OF DENTAL DISEASE IN PET RABBITS

Frances Margaret Harcourt-Brown

Abstract

Dental disease is common in pet rabbits. Although it can be caused by prognathism, neoplasia or trauma to the teeth or jaws, most case of dental disease in pet rabbits do not appear to be related to these causes. Instead the teeth deteriorate in a progressive pattern that is characterised by a change in shape, structure and position of the teeth and culminates in cessation of tooth growth, crown loss and root resorption. Abscesses are common. The aetiology of this syndrome is not clear. The most popular theories are (i) lack of dental wear, (ii) genetic predisposition or (iii) underlying metabolic bone disease due to calcium and/or vitamin D deficiency.

This thesis gives a detailed description of the dental anatomy and physiology of the domestic rabbit (*Oryctolagus cuniculus*); a species with continually growing teeth. The clinical manifestations of dental disease in pet rabbits are described. Existing literature relating to dentition, dental disease, calcium metabolism and metabolic bone disease in rabbits is reviewed. The main body of the thesis is an in-depth study of the radiological and morphological features of 172 prepared skulls and 315 skull radiographs of pet rabbits. A comparison is made between the prepared skulls of pet rabbits and the collection of rabbit skulls that is held at the Natural History Museum in London. In addition to the examination of skulls and radiographs, gender and breed details of 1254 pet rabbits presented for veterinary treatment are analysed. Of these rabbits, 465 required dental treatment.

The detailed morphological and radiological study showed a progressive deterioration in the structure of the teeth and bones with visible and radiological evidence of bone loss throughout the skull, including alveolar bone surrounding the teeth. Loss of alveolar bone is known to be a feature of metabolic bone disease in other species. Loss of alveolar bone and elongation of the tooth roots was the first change to be apparent on visual examination of the skulls and radiological examination clinical cases. This preceded changes in the shape or structure of the crowns.

The morphological and radiological study showed a wide breed variation in the shape and size of the heads pet rabbits. Despite this variation, there was no statistically significant relationship between breed and dental disease. Acquired dental disease occurred in all breeds including those with a head shape similar to wild rabbits. However, there was a statistically significant relationship between gender and dental disease. Seventy percent of the rabbits with acquired dental disease were male. Of the rabbits without dental disease, there was an equal split between the genders.

The potential causes of dental disease in pet rabbits are discussed. The conclusion of the thesis is that metabolic bone disease plays a major role in the development of dental disease in pet rabbits. This conclusion has important welfare implications for the diet and husbandry of pet rabbits. It is also affects the prognosis and treatment of rabbits with the progressive syndrome of acquired dental disease (PSADD).

© Frances Harcourt-Brown 2006

© Frances Harcourt-Brown 2006

Introduction

The domestic rabbit (*Oryctolagus cuniculus)* has teeth that continually erupt and grow throughout life. The shape of the occlusal surfaces are maintained by wear against the opposing teeth. Any abnormality in the shape, structure or relative position of the teeth leads to malocclusion, which is a recognised health problem in rabbits. Incisor malocclusion in rabbits is usually considered to be inherited. For example, in *The Biology of the Laboratory Rabbit, 2nd Edition* (1994) Lindsey and Fox cite mandibular prognathism as the cause of incisor malocclusion and describe it as "*the most common of the known inherited diseases in the rabbit, as few laboratory or commercial breeding stocks are free of the problem*". But incisor malocclusion is not the only dental disease that occurs in rabbits. Cheek teeth problems can also occur. Pollock (1951) reported that weight loss, salivation, anorexia and mandibular abscesses could be attributed to problems with the cheek teeth.

In pet rabbits, dental disease is a common reason for presentation for veterinary treatment. It is described in book chapters, conference proceedings and review articles but a only a few papers that relate to dental disease in pet rabbits can be found in scientific journals (Lobprise and Wiggs, 1991, Brown, 1992, Crossley 1995, Harcourt-Brown, 1995*, Harcourt-Brown 1996*, Steenkamp and Crossley 1999, Harcourt-Brown and Baker, 2001*). The author of this thesis began her investigations of dental disease in pet rabbits in 1992. This was the result of an observation that many pet rabbits had dull, ribbed incisors with little or no enamel. In some of these rabbits, the teeth would grow without ribs if a mineral and vitamin supplement was added to the diet. Many of the diseases of pet rabbits presented to the author's practice were related to problems with their teeth. At that time, apart from descriptions of incisor malocclusion, there was a paucity of information on dental problems in pet rabbits. This was surprising as rabbits have been kept as pets for many years. Older clients often comment that they do not remember so many dental problems in rabbits they owned in their childhood. Many of these rabbits lived for several years. In those days, pet rabbits were mostly fed on hay, freshly picked grass and weeds plus discarded vegetables or parts of vegetables from the kitchen or garden. Some rabbits may have been given a 'warm bran mash' as a treat. It is only in recent years that 'rabbit food' has been available from pet shops and supermarkets. This has dramatically changed the diet of rabbits kept as pets and appears to coincide with the increased incidence of dental problems.

In order to learn more about dental disease in rabbits and their relationship with facial abscesses, in 1992 the author started to collect, prepare and examine skulls from rabbits. Skull radiographs of rabbits were taken whenever possible. In 1995, the findings of these investigations were published in the *Veterinary Record* in a paper entitled "A review of clinical conditions in pet rabbits associated with their teeth" (Harcourt-Brown 1995*).This article included a study of 20 prepared skulls from rabbits. The most striking finding of this study was the appearance of the bone of the skulls of the rabbits with dental problems. The bone was thin and translucent and did not appear to be as calcified as the bones of the skulls from wild rabbits. The appearance of the skulls, in conjunction with deformed defective teeth, led the author to conduct further investigations to explore the possibility that the appearance of the bone may be linked with metabolic bone disease. These investigations included diet analysis and haematological, biochemical and parathyroid hormone assays. The results of these investigations have been published (Harcourt-Brown 1996*, Harcourt-Brown and Baker, 2001*).

Since 1992, the author's 'special interest' in diseases of rabbits, especially dental disease, has resulted in a large pet rabbit caseload on a first opinion, second opinion and referral basis. This caseload rose from 10% to 80 % between 1995 and 2000 and reached over 90% in 2004. In 2000, this translated as approximately 30-40 rabbit consultations/ operations per week including 6-10 new cases. Details of diet, appetite and husbandry are always established during consultations.

© Frances Harcourt-Brown 2006

This large caseload has permitted a detailed observation of the clinical characteristics of dental disease in pet rabbits and the outcome of their treatment. Many of the rabbits have undergone skull radiography and several cases have been followed for many years. Some owners have consented to post-mortem examination, which has included skull preparation, at the end of their pet's life. Examination of the skulls has facilitated radiological interpretation.

The author's clinical and radiological findings, in conjunction with examination of skulls of pet rabbits have demonstrated a progressive sequence of changes that affect the teeth and bones of the skull, hence the term 'progressive syndrome of acquired dental disease' (PSADD). In the author's practice, the majority of pet rabbits with dental problems appear to be affected by this syndrome. Only those rabbits with congenital prognathism, neoplasia or traumatic injuries to the skull and/or teeth do not follow the same pattern although the course of the disease is influenced by dental treatment, dietary modification and/or changes in husbandry. The purpose of this thesis is to investigate the possibility that PSADD is caused by metabolic bone disease.

© Frances Harcourt-Brown 2006

CHAPTER 1: BACKGROUND INFORMATION

Section 1.1: Dental anatomy and physiology of the domestic rabbit (*Oryctolagus cuniculus*)

Terminology

The first investigations of odontology were devoted to the study of the dentition of man. Anatomists and dentists introduced precise technical terms to describe human teeth. Unfortunately, this terminology can be inadequate for other animals (Peyer, 1968). The standard description of a tooth divides it into three parts; the crown, the neck and the root. Some teeth have more than one root. The term 'crown' refers to the part of the tooth that protrudes into the mouth. In humans, this part of the tooth is covered in enamel. The neck is the intermediate part between the crown and the root or roots. The root of the tooth is embedded in the jaw and, in humans, this is not covered in enamel so the root and the crown may be distinguished by the presence or absence of enamel. The roots of human and many other mammalian teeth are cone shaped, so the term 'apex' aptly describes their pointed end. The definition of apex is given as '*the pointed end of a cone shaped part'* by Blood and Studdert (1999).

The teeth of rabbits are very different from human teeth. This has resulted in some esoteric terminology. All the teeth of rabbits grow continuously. They are cylindrical in shape and enamel is continually formed at the end of the tooth that is buried in the jaw. The buried section of the tooth is eventually exposed as the tooth continually erupts and grows. Enamel covers both the exposed and buried parts of the tooth so there is no distinguishable root and crown and there is no neck. These features have led to the use of alternative terminology to describe the parts of lagomorph teeth. 'Root' and 'crown' are often considered incorrect. Instead, the terms 'exposed' or 'clinical' crown are used for the supragingival section of the tooth, and 'reserve crown', 'submerged crown' or 'clinical root' for the subgingival section of the tooth. Confusingly, because both the submerged and exposed sections of the lagomorph teeth are covered in enamel, the term 'anatomical crown' can be used to describe the whole tooth, including the part that is buried in the jaw (Wiggs and Lobprise 1995, Crossley 2003a). Although the word 'root' is considered unacceptable for lagomorph teeth, both Wiggs and Lobprise (1995) and Crossley (2003a) resort to the use of the term 'root' in illustrations in their book chapters. So, for simplicity and to avoid confusion, the word 'root' will be used in this thesis to describe to '*that part of the tooth that is buried in the tissues*'. This is the definition given in 'Saunders Comprehensive Veterinary Dictionary' (Blood and Studdert, 1999). The term ' crown' will be used to describe '*the exposed part of the tooth within the mouth*'.

Despite the opposition to the use of the terms 'crown' and 'root' in relation to lagomorph teeth, the term 'apex' seems to be acceptable. Yet, strictly speaking, the teeth of rabbits do not have an apex because they are cylindrical rather than cone shaped. In other species, the terms 'apex', is understood to refer to the pointed end of the tooth that is embedded in the jaw. It is difficult to find another term to describe this area of the tooth in the rabbit. So, for the purposes of this thesis, the term 'apex of the root' will be used to describe the end of the tooth that is embedded in the jaw. The adjectives 'apical' and 'periapical' will be used to in relation to this end of the tooth and the area that immediately surrounds it.

The classification of lagomorph teeth is also confusing. Wiggs and Lobprise (1995) classify lagomorph teeth as 'aridacular hypsodont'. Aridacular means open rooted. 'Hypsodont' is defined in 'Saunders Comprehensive Veterinary Dictionary' is '*having teeth all the same height'*. Yet, Crossley (2003b) defines hypsodont as '*long crowned',* which is a slightly different definition. Wiggs and Lobprise also describe lagomorph dentition as '*heterodont (having varying tooth shape* '.

© Frances Harcourt-Brown 2006

Elodont' is another term that is often used to describe lagomorph teeth (Crossley 2003a, Crossley 2003b). This was a term introduced by Kertesz (1993) and is defined by Blood and Studdert in '*Saunders Comprehensive Veterinary Dictionary'* (1999) as '*a tooth that increases in length throughout life'*. But, again, this is a term with more than one definition. Crossley (2003b) defines 'elodont' as '*continuously growing and erupting',* which aptly describes the dentition of lagomorphs. To avoid confusion, the term 'continuously growing and erupting' will be used in this thesis rather than 'aridacular hypsodont' or elodont.

Lagomorph dentition

The domestic rabbit *Oryctolagus cuniculus* belongs to the order of lagomorphs, which includes rabbits, hares and pikas. The dentition of lagomorphs is intermediate between ungulates and rodents. Rabbits are often misguidedly considered to be rodents. For many years lagomorphs were classified as rodents (Owen, 1868) until a distinction was made between '*Rodentia simplidentata'* i.e. rodents with a one pair of incisors and *'Rodentia duplidentes'* i.e. rodents with two pairs of incisors i.e. lagomorphs (Peyer, 1968). Eventually the dentition of lagomorphs was found to be so different from rodents that they were classified as a separate order.

There are also differences in jaw movement between rabbits and rodents. These differences in dentition and jaw movement reflect differences in diet. Although grass is the preferred diet of wild rabbits, they will eat a variety of plants (Bhadresa, 1977) and their masticatory system of rabbits has evolved to utilise a range of foods so they can survive in a range of habitats throughout the year (Weijs and Dantuma, 1981). Lagomorphs are obligate herbivores whereas many rodent species are omnivorous and can utilise a wide range of foods. Rodents often need to gnaw in order to collect and reduce food. The gape of rodents is wider than lagomorphs. For example, the gape of rat is 40 º and a hamster 60 º whereas the maximum gape of a rabbit is only 20-25º. It is limited by the elastic forces of the jaw closing muscles (Weijs and others, 1989).

The roots of the incisors of rabbits are shorter than rodents although, like rodents, the incisors are open rooted and grow continually.

A characteristic of lagomorphs is the presence of a second set of small incisors or 'peg teeth' situated just behind the large upper first incisors (Figure 1). Within the lagomorph order, there is little variation in dentition, although the teeth of hares (*Lepus* spp.) can be distinguished from *Oryctolagus cuniculus* by minor differences in the grooves on the third premolars, lower third molar and upper incisors (Hillson, 1986). Like rodents, lagomorphs have no canines and the cheek teeth are separated from the incisors by a broad diastema. Hairy folds of the upper lip fit into this diastema.

The teeth of rabbits have the same structural components as other animals i.e. dentine, enamel, cementum and pulp. Each tooth socket is surrounded by a *lamina dura* (Figure 1). This is a layer of '*dental alveolar bone containing more than usual amounts of highly calcified cementing substance, associated with periodontal fibres in the bone; causing lines of increased radiodensity on dental radiographs'* (Blood and Studdert, 1999).

Enamel and dentine are continually formed by ameloblasts and odontoblasts. There is a rhythm to amelogenesis that is represented by microscopic striations in the enamel. The pattern of the crystalline structure of enamel varies with species. Lagomorph and rodent enamel shares its pattern with Cercopithecoidea (a family of non-human primates) and marsupials (Hillson, 1986)

© Frances Harcourt-Brown 2006

Figure 1:
Dentition of the domestic rabbit (*Oryctolagus cuniculus)*

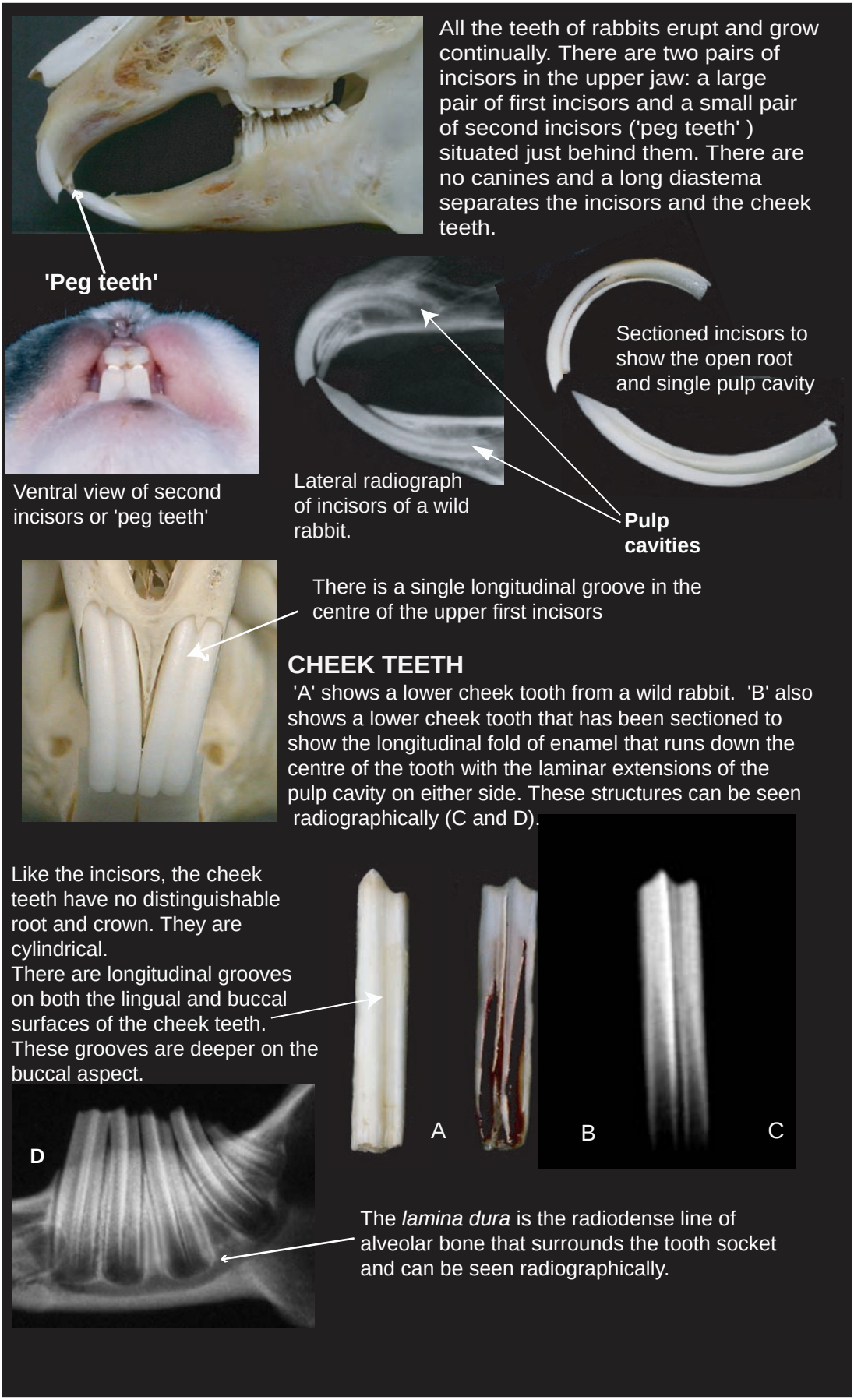

Dental formula

Rabbits have two sets of teeth. A deciduous set is present in foetal rabbits and is shed just before or just after birth (Horowitz and others, 1973). The deciduous set comprises:

$$\frac{\text{I: 2}}{1}\ \frac{\text{C:0}}{0}\ \frac{\text{P: 3}}{2}\ \frac{\text{M: 0}}{0} = 16$$

The permanent set of teeth erupts during the first 5 weeks of life and comprises:

$$\frac{\text{I: 2}}{1}\ \frac{\text{C:0}}{0}\ \frac{\text{P: 3}}{2}\ \frac{\text{M:3}}{3} = 28$$

Incisors

On the upper jaw, there is a large pair of maxillary incisor teeth (first maxillary incisors) with the second incisors situated immediately caudal to them. On the lower jaw, there is a single pair of large mandibular incisors. The upper first incisors have a single deep groove on the labial aspect that runs longitudinally along the length of the tooth (Figure 1). The large upper first incisors have a thick layer of enamel on the labial aspect but none on the lingual side. The upper second incisors nd the lower incisors have enamel on both the labial and lingual aspects. This distribution of enamel permits the formation of sharp cutting edges to the tips of the teeth (Hirschfield and others, 1973).

The incisors are primarily used for biting through vegetation, although they are also used for gnawing, fighting, grooming and gripping objects to move them.

Cheek teeth

Like cattle and horses, in rabbits the maxillary arcade is wider than the mandibular arcade (Figure 8), whereas rodents have a wider mandibular arcade. The mandibular cheek teeth are arranged in a straight line. The maxillary cheek teeth are similarly arranged, except that the intermediate premolars and molars are wider than the first premolar and the last molar giving the buccal side of the alignment a convex shape (Figures 6 and 7). The circumference of the cheek teeth exhibit deep longitudinal grooves or embrasures, which are deep on the buccal aspect and fit into a corresponding groove in the alveolar wall. There is also a longitudinal fold of enamel that runs down the centre of each tooth (Figures 1, 3, 4 and 6). At the occlusal surface, the softer cementum and dentine wear faster than the harder enamel fold, which survives as a sharp edge, both at the circumference and across the centre of the tooth. This gives the molar and premolars an effective shredding surface (Michaeli and others, 1980).

Like histricomorphs, such as guinea pigs and chinchillas, the cheek teeth of lagomorphs grow continually throughout life. In contrast, gnawing rodents, such as rats, mice and hamsters have a permanent set of cheek teeth that do not grow continually.

Wild rabbits and those pet rabbits that eat grass and natural vegetation sometimes have brown staining on the supragingival crowns of the teeth, especially the cheek teeth. Brown staining on the teeth of herbivores is caused by chlorophyll and porphyrin pigments from the herbage (Jubb and others, 1985a).

© Frances Harcourt-Brown 2006

Innervation of the teeth

Although species with continually erupting teeth, have smaller and fewer axons in the dentine than animals with permanent dentition (Byers, 1984), rabbits' teeth are innervated. The nerve supply is from the trigeminal nerve (Figure 2).

Figure 2: Course of the trigeminal nerve in the domestic rabbit (*Oryctolagus cuniculus)*

From: *Atlas d'anatomie du lapin (Barone and others, 1973). Reproduced with permission from the author.*

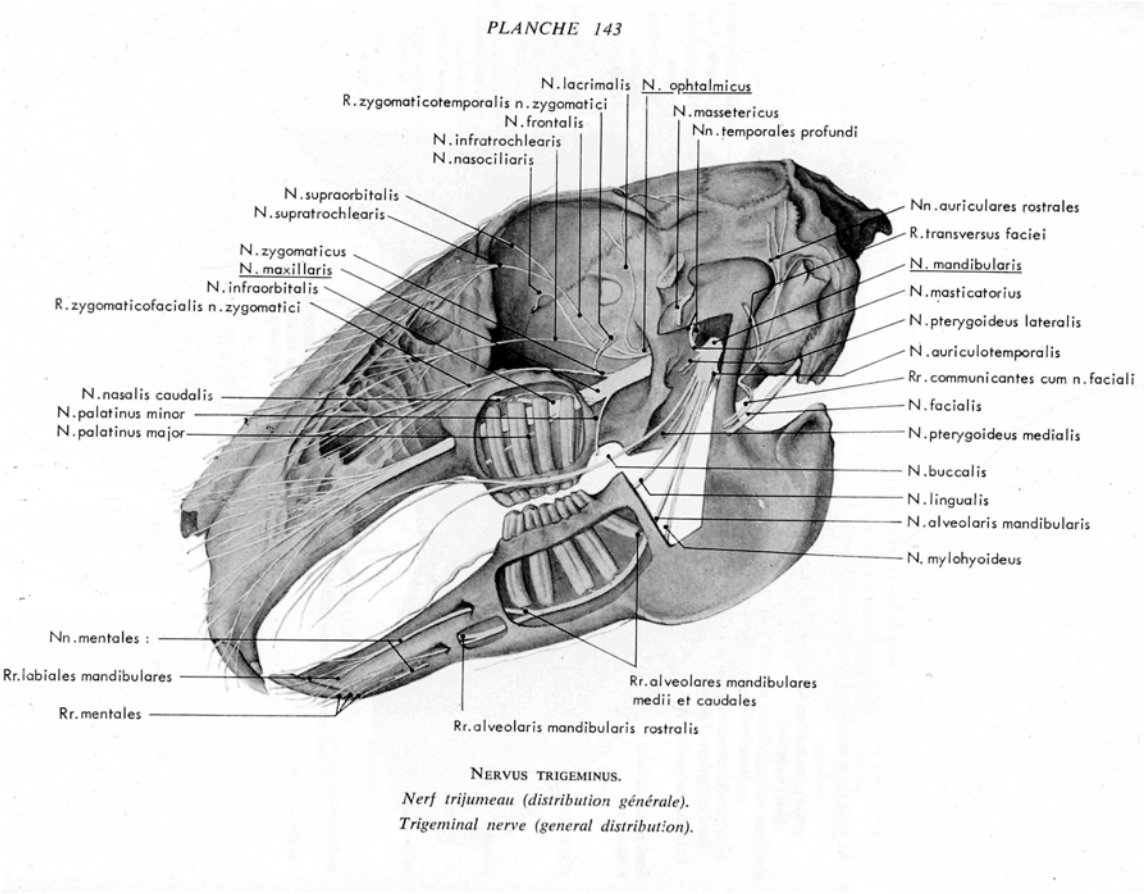

Bishop (1995) describes the innervation of the cheek teeth of rabbits: '*A mixed population of myelinated and unmyelinated nerve fibres enter the tooth through the apical foramen and pass through the vascular pulp, branching on the way to form a plexus beneath the odontoblastic layer. Nerve fibres from this plexus extend into and through the odontoblastic layer and terminate in tubules in the dentine. Atubular tissue protects the nerve fibres at the occlusal surface of the teeth. Myelinated fibres are found towards the apex of the root with an increasing proportion of unmyelinated fibres towards the occlusal end. These fibres are believed to be nociceptive'.*

© Frances Harcourt-Brown 2006

*Structure of the teeth of the domestic rabbit (*Oryctolagus cuniculus*)*

Examination of transverse sections along the long axis of the incisors shows a single pulp cavity that is conical in shape and tapers towards the occlusal end of the tooth (Figure 1). Examination of transverse sections across the long axis of the cheek teeth shows two laminar extensions of the pulp cavity that converge at the apex of the tooth to form a single pulp chamber (Figures 1, 3 and 4). The pulp cavities contain a range of differentiated and undifferentiated cells, a blood supply and a nerve supply (Michaeli and others, 1980).

Figure 3: Transverse section through a maxillary cheek tooth (a) and mandibular cheek tooth (b)

From*: Harcourt-Brown (2001), Textbook of Rabbit Medicine. Drawings by Nigel Harcourt-Brown based on sectioned teeth of wild rabbits examined under a dissecting microscope using Michaeli and others(1980) as a reference source..*

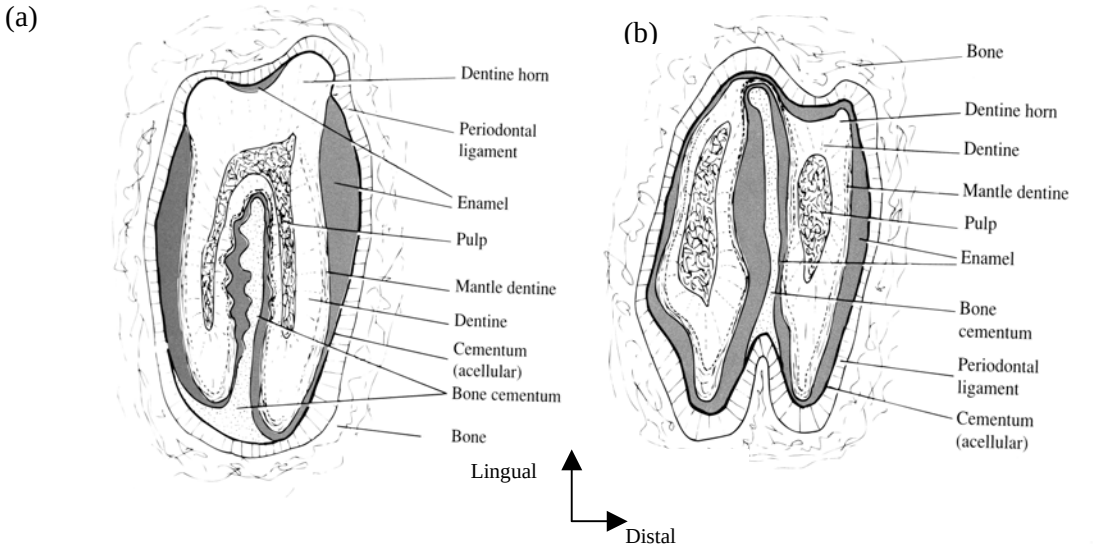

The microanatomy of rabbit premolars and molars has been described by Bishop (1995) and is illustrated in Figure 4. The following description is based on Bishop's observations and the work of Listgarten and Kamin (1969) and Michaeli and others (1980):

"Each mandibular tooth consists of 2 laminae aligned mesially and distally. For most of the length of the tooth the dentine encloses a separate pulp chamber but the 2 chambers merge towards the apical or formative end. Some long thin horns arise from the pulp and extend horizontally towards the periphery of the tooth. On the occlusal surface the dentine is exposed but most of the rest of it is covered by enamel. The 2 laminae are separated by a large groove which is lined by enamel and contains cellular cement. Most of the remaining enamel is covered by acellular cement. The 2 laminae are joined on the buccal aspect by a narrow bridge of dentine near the occlusal end and this bridge encloses pulp more apically. In the apical region the pulp is wide and displays a range of development from undifferentiated cells and no dentine through preodontoblasts forming mantle dentin to mature secretory odontoblasts producing tubular dentine.

Each pulp chamber tapers towards the occlusal end. Most of the dentine is tubular but near the occlusal end the odontoblasts appear to transform into postodontoblasts which deposit an atubular tissue. The postodontoblasts then degenerate and with other pulpal contents seem to be incorporated into the atubular hard tissue at the occlusal end."

© Frances Harcourt-Brown 2006

Figure 4: Diagram of the structure of a premolar of a rabbit

From: Is rabbit dentine innervated? (Bishop, 1995). Reproduced with permission from Journal of Anatomy.

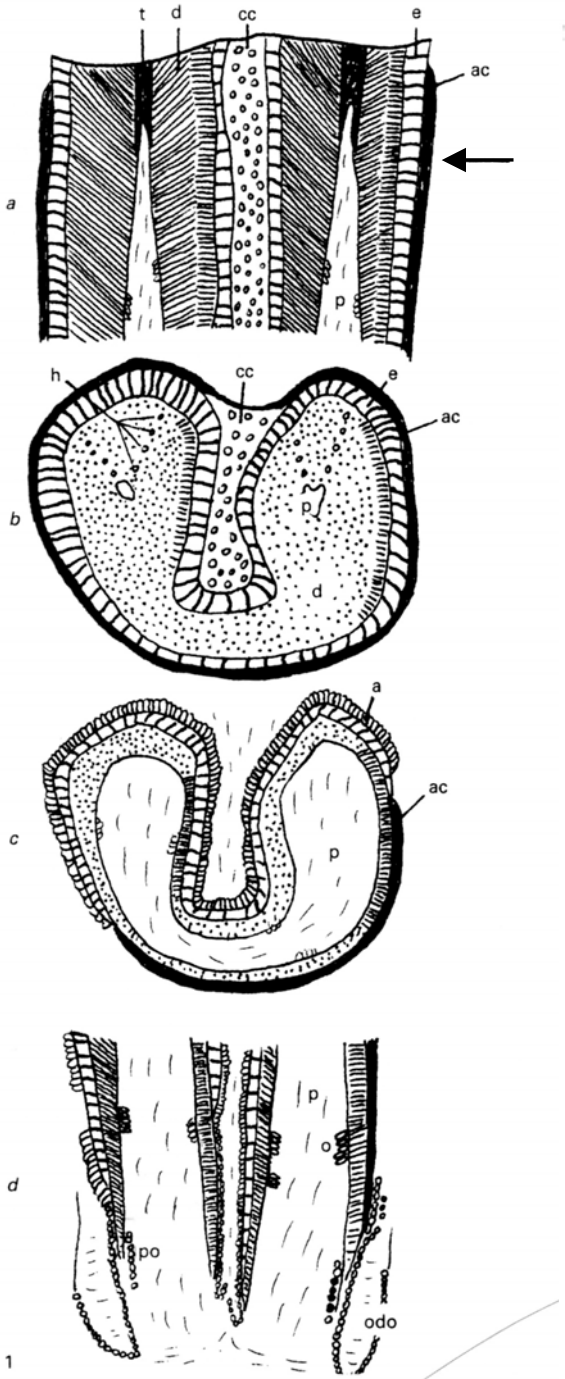

Diagram of rabbit premolar showing occlusal end (*a*) and transverse section (*b)* near the occlusal end at the level indicated by the arrow.

Transverse section *(c*) taken at the occlusal end of the apical (formative) end of the premolar shown in (*d)*

Key:

a: ameloblasts

ac: acellular cementum

cc: cellular cementum

d: dentine

e: enamel

h: pulp horn

odo: odontogenic organ

po: preodontoblast

p: pulp

t: atubular tissue

Magnification X 15

© Frances Harcourt-Brown 2006

Dental wear

Rabbit's teeth erupt and grow continuously. Hamidur Rahman and others (1983) recorded a rate of approximately five inches (12.7cm) per year in the upper incisors and eight inches (20.3cm) per year in the lower incisors. These findings are similar to those of Shadle (1936) who recorded a growth rate of approximately 2mm per week for the upper incisors and 2.4mm per week for lower ones. The speed at which crowns grow is determined by the rate of eruption and the rate that dental tissue is worn away. It is also influenced by occlusal force. Taking teeth out of occlusion hastens the rate of eruption. In a study by Ness (1956), shortening the mandibular incisors and taking them out of occlusion increased the eruption rate from 280µ/day (0.28mm/day) to 700µ/day (0.7mm/day).

The constant process of growth and dental wear demands a continual supply of calcium and other minerals and nutrients for the formation of dentine and enamel. The rate of growth of the teeth is influenced by pregnancy, age and diet. (Shadle 1936, Ness 1956, Lowe 1998).

Rabbit's teeth are kept in shape by the continual processes of growth, attrition and abrasion. Attrition is defined in *Saunders Comprehensive Veterinary Dictionary* (Blood and Studdert, 1999) as '*the physiological wearing away of a substance or structure in the course of normal use'*. Dental attrition is defined as '*the occlusal wear of a tooth, as a result of tooth to tooth contact as in mastication; physiological rather than pathological'*. In rabbits, contact with food contributes to the process of attrition because the natural diet of rabbits is abrasive diet due to the presence of lignin, cellulose and silicate phytoliths in grass and other plants. However, dental wear from abrasive foods is not the same as dental abrasion. Dental abrasion is defined in *Saunders Comprehensive Veterinary Dictionary* (Blood and Studdert, 1999) as '*abnormal wearing away of tooth substance caused by mechanical process such as chewing rocks or cage bars'*. Abrasion occurs outside the occlusal zone and in teeth that do not meet during chewing. It is characterised by scratches and irregularities in the surface of the tooth whereas attrition from tooth to tooth contact results in the formation of well-defined smooth facets where the teeth meet.

Rabbits are destructive creatures that strip bark off trees and chew through tree roots in addition to grazing and browsing. This fibrous diet blunts the teeth. Deliberate planing movements are necessary to maintain the sharp edges of the teeth. Tooth-to-tooth contact is evident from the smooth facets on the occlusal surfaces of the teeth. Planing movements were described by Schadle (1936) who noticed that rabbits can be seen periodically grinding their teeth. This behaviour is a characteristic of rodents and lagomorphs and has been called 'thegosis' (Colyer, 1990). Early zoologists believed that rabbits were animals that chewed cud, a characteristic that included them in the Jewish list of unclean meats. The phrase "*....as the camel and the hare and the coney for they chew the cud but divide not the hoof, therefore they are unclean to you*" appears in the bible (Deuteronomy XIV, v.7). According to Wiggs and Lobprise (1995), there is evidence of dental wear from bruxism on the non-functional deciduous teeth of neonatal rabbits. The authors cite a German reference by Keil (1949). In adults, planing movements can be seen when rabbits are relaxed and at rest when spontaneous lateral jaw movements take place in the absence of food (Harcourt-Brown, personal observation). This type of bruxism (tooth grinding) is very different from the tooth grinding that occurs when rabbits are suffering from a painful abdominal condition such as mucoid enteropathy. Tooth grinding due to pain is audible and does not occur when the rabbit is in a relaxed state. It is associated with restlessness.

The shape of the tips of the incisors is also maintained by planing movements. Periodically rabbits will protrude the mandible bringing the labial surface of the mandibular incisor in contact with the tip of the first maxillary incisor as the mouth closes (Figure 5). This movement is often preceded by protrusion of the tongue and licking of the lips (Harcourt-Brown, personal observation). These jaw movements usually occur after a period of rest when the rabbit rises and yawns.

© Frances Harcourt-Brown 2006

Figure 5:
Dental wear



Studies into the dietary habits of wild rabbits show that they are able to utilise a remarkable diversity of foods throughout the year and in a variety of habitats. Although rabbits prefer tender shoots of various plants (especially grasses) they are able to feed on bark and leaves and stems of trees and shrubs.

Examination of bark that has been gnawed by rabbits show imprints of the incisor teeth that are used for gnawing.





Grass, bark, stems and other fibrous or lignefied food material tend to blunt the teeth. Deliberate planing jaw movements are used to sharpen and maintain the shape of the teeth. Evidence of tooth to tooth contact between the teeth can be see in the smooth facets on the occlusal surfaces. Tooth grinding movements can be seen in rabbits when they are at rest.

The lower incisors are sharpened by protruding the lower jaw to bring the tips of the upper first incisors in contact with the lingual surface of the lower incisors. Smooth wear facets can be seen as a result of these planing jaw movements.





Occlusal relationship of the teeth of the domestic rabbit (Oryctolagus cuniculus).

At rest, the cutting edges of the lower incisor teeth are situated just caudal to the upper first incisors. They are in contact with, or just separated from the small pair of second incisors (Figure 1)

The resting occlusal relationship of the cheek teeth is with the enamel ridge across the centre of the occlusal surface of each tooth interlocking with the opposing interdental space (Figures 6 and 7). This results in a rostrocaudal succession of transverse ridges and valleys. Upper ridges are reciprocal with lower valleys and *vice versa*, which gives a characteristic zigzag pattern on lateral skull radiographs. The longitudinal enamel folds can be seen as radiodense lines on lateral radiographs of the skull (Figure 7).

Figure 6: The occlusal relationship of the cheek teeth

From: *Textbook of Rabbit Medicine (Harcourt-Brown, 2001). Drawings by Nigel Harcourt-Brown based on prepared skulls of wild rabbits examined under a dissecting microscope.*

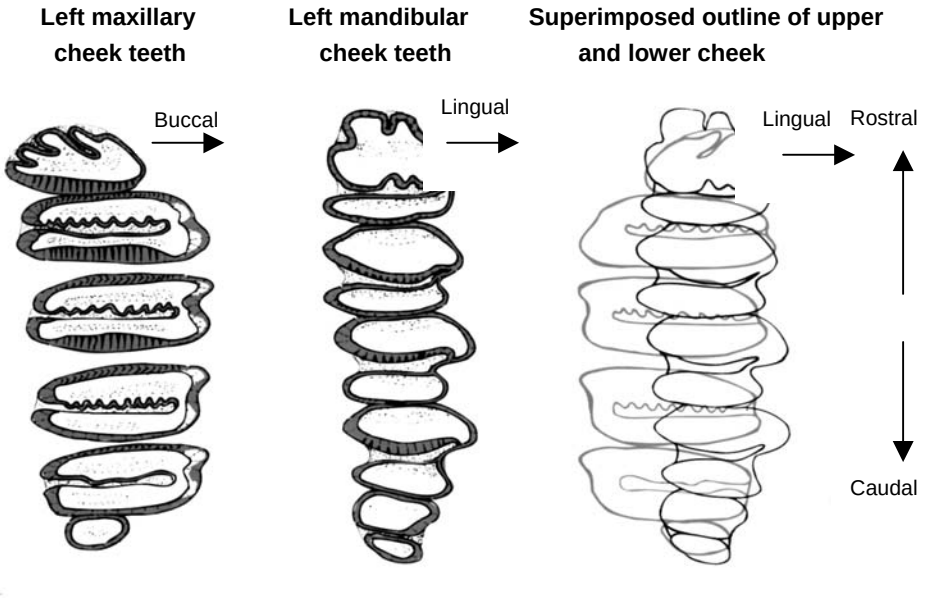

© Frances Harcourt-Brown 2006

Figure 7:
Cheek teeth of the domestic rabbit (*Oryctolagus cuniculus*)

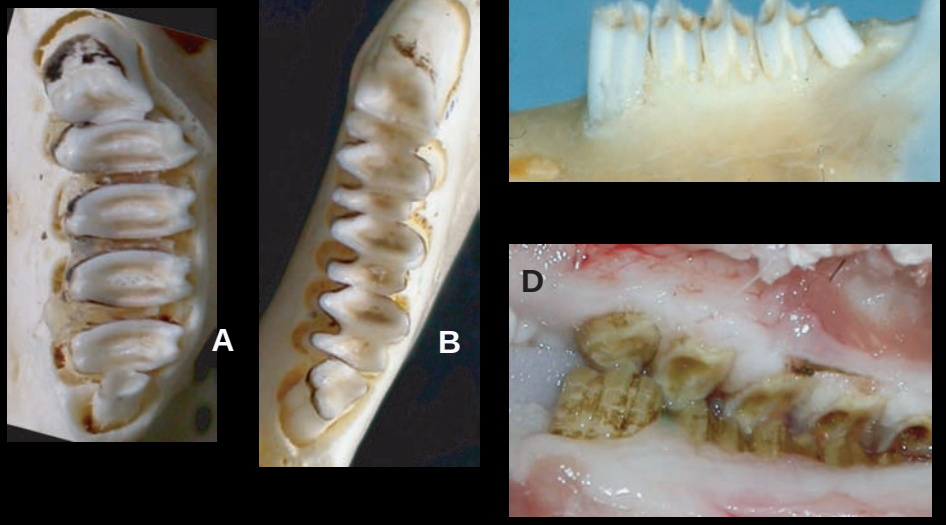

The longitiudinal central enamel fold in the upper (A) and lower (B) cheek teeth is not worn away as fast as the surrounding dentine and cementum. The enamel survives as a sharp enamel ridge across the occlusal surface, which forms a vertical point at the lingual edge (C). The ridges across the occlusal surface interlock with the valleys on the opposing teeth (D). This arrangements forms a characteristic zigzag occlusal line on lateral skull radiographs (E).

The central enamel fold may be seen as a vertical line running down the centre of each cheek tooth (F).

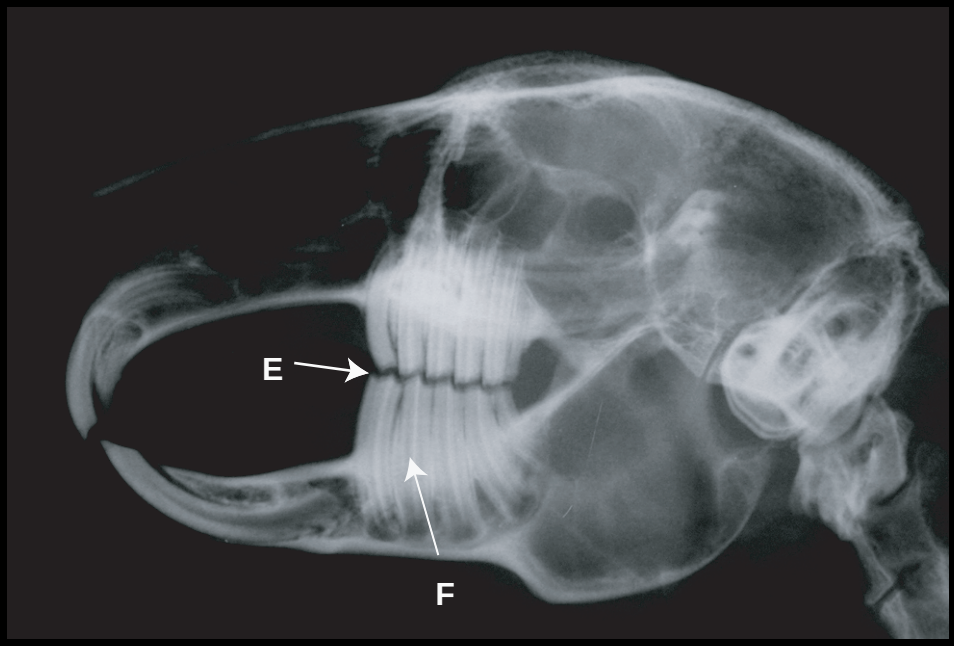

Lateral skull radiograph of a 6 yr old Dutch female pet rabbit

Figure 8: Resting occlusal position of the cheek teeth

Drawing from: *A radiographic analysis of mastication and swallowing in the domestic rabbit: (Oryctolagus cuniculus). (Ardran and Kemp, 1958) Reproduced with permission from Zoological Society of London.*

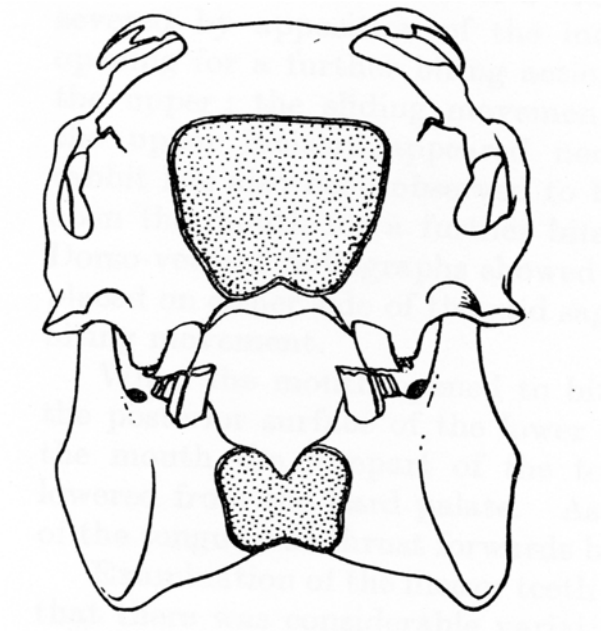

There are several anatomical descriptions of resting occlusion in the rabbit. These are supported by dissections and/or cinematoradiographic studies (Ardran and Kemp, 1958, Hirschfield and others, 1973, Weijs and Dantuma, 1981). These studies show that, at rest, the cheek teeth are positioned so that the transverse ridges on the maxillary teeth are in line with the valleys of the mandibular teeth (Figures 6, 7 and 8). The mandibular arcade is narrower than the maxillary arcade, so the lingual edges of the maxillary cheek teeth occlude with the buccal edges of the mandibular cheek teeth. The occlusal surfaces are tilted at about 15º to the horizontal plane (Weijs and Dantuma 1981). A different description of resting occlusion is given in the *Journal of Veterinary Dentistry* (Crossley, 1995), which states that '*the structure of the rabbit's temporomandibular joint is such that a minor degree of rostro-caudal movement shifts the mandibular condyle up or down a step in the temporal joint surface. In the caudal position, the cheek teeth are in alignment and the incisors are separated.....If both temporomandibular joints are positioned on the temporal step, the cheek teeth are separated slightly and the incisors are brought into occlusion This is the normal resting position'* i.e. the incisors and the cheek teeth do not occlude at the same time. This description of resting occlusion appears in several book chapters (Crossley and others 1998, Crossley 2000, 2000a, 2003a, 2003b) that are illustrated either with computer generated diagrams or with photographs of a prepared skull from a wild rabbit. Crossley's description of resting occlusion is illustrated in Figure 59.

© Frances Harcourt-Brown 2006

Jaw movement during mastication

There have been several studies of mastication in rabbits. Some authors have used cinematoradiography (Ardran and Kemp 1958, Weijs and Dantuma 1981) to monitor jaw movement. Others have used electromagnetic sensors placed at various sites on the head (Schwartz and others 1989, Yamada and Yamamura 1996). During mastication of grass, it has been shown there may be 300-380 chewing cycles per minute (Ardran and Kemp, 1958).

During each type of masticatory cycle, there are three types of jaw movement:

Type 1: This is a preparatory phase when food is cut into pieces of manageable size, i.e. biting.

Type 11: During this phase, pieces of food are ground between the cheek teeth i.e. chewing.

Type 111: This is the preswallowing sequence of jaw movements.

Type 1 sequence of jaw movement (biting):

This preparatory masticatory sequence has two phases: a jaw opening phase and jaw closing phase. During this sequence, the incisors cut through food to reduce it to manageable pieces that are transported by the tongue to the molariform teeth for reduction. The action of the incisors of rabbits during biting was analysed by Ardran and Kemp (1958) who trained rabbits to feed in the presence of photographic or radiographic apparatus. Their studies showed that, during grazing, if the grass is less than two inches long, the stems are taken into the mouth and cut between the incisors. During this biting action, the lower jaw moves forward so the incisors meet edge to edge (Figure 9). If tough stems are eaten, they may be detached by gripping the stem between the incisors and pulling. If long stems are eaten, the rabbit will cut off a length approximately two inches long by cutting it between the incisors. The stem is then turned so one end projects from the mouth while the other end is ground between the cheek teeth.

After sectioning stems between the tips of the incisors, the lower incisors slide along the caudal surface of the upper first incisor as the mouth closes. This sliding movement can also used to take bites out of solid food such as a carrot or to gnaw hard material such as bark. A characteristic pattern of parallel furrows can be seen in wood that has been gnawed by rabbits (Hillson, 1986) (Figure 5).

Figure 9: Biting action of the incisors

From: *A radiographic analysis of mastication and swallowing in the domestic rabbit (Ardran and Kemp, 1958). Reproduced with permission from the Zoological Society of London*

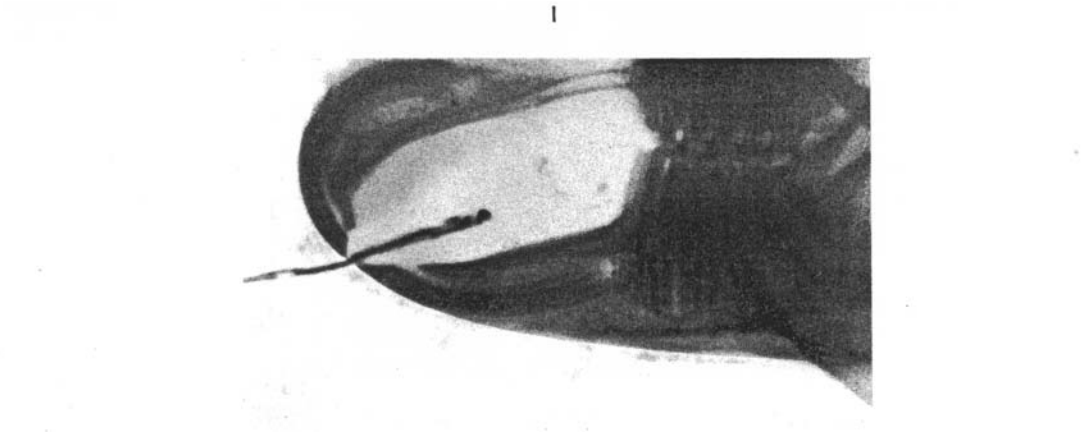

© Frances Harcourt-Brown 2006

In a paper that appeared in the *Journal of Veterinary Dentistry*, Crossley (1995) says *'Rabbits primarily use their incisor teeth in a lateral slicing action, whereas rodents use their incisors in a dorso-ventral gnawing action. Although rabbits are capable of gnawing, they only appear to do this when cheek tooth problems interfere with the normal lateral chewing action'* . This statement was unreferenced and is unsound. Cinematoradiographic studies by Ardran and Kemp (1958) show that, during biting, jaw movement is not a lateral slicing action. Instead, the movement is predominantly in the sagittal plane with small lateral excursions away from the midline. It is also untrue that rabbits only gnaw when they have cheek teeth problems. Gnawing is a natural activity of rabbits. Throughout the countryside, there is evidence of gnawing by wild rabbits (Figure 5), especially during the winter when bark may be the only food source that is available.

Type II sequence of jaw movement (chewing):

This is the reduction sequence of masticatory movements that occurs when food is ground between the cheek teeth. During Type II mastication, chewing can only take place on one side of the mouth. Lateral excursion is wide and the jaw follows a unidirectional crescent shaped movement throughout the chewing cycle. There are three phases in the Type II masticatory sequence, a jaw opening phase, a fast closing phase and a slow closing phase during which food is crushed between the teeth. The third phase of Type II jaw movement is a power stroke that crushes food between the teeth (Yamada and Yamamura, 1996). At the start of this power stroke, the buccal edges of the lower molars are opposite or just lingual to the buccal edges of the upper molars. The anatomy of the mandible and the site of the temporomandibular joint make the lower jaw an effective lever so considerable force is applied between the interlocked transverse upper and lower ridges of the cheek teeth during the power stroke (Weijs and Dantuma, 1981). This force has a vertical and backward component (Figure 10).

Figure 10: Interlocking mechanism that occurs between upper and lower ridges of the cheek teeth during mastication in the domestic rabbit (*Oryctolagus cuniculus*)

Drawing modified from: Functional anatomy of the masticatory apparatus in the rabbit (Oryctolagus cuniculus) Weijs and Dantuma, (1981) reproduced with permission from the author.

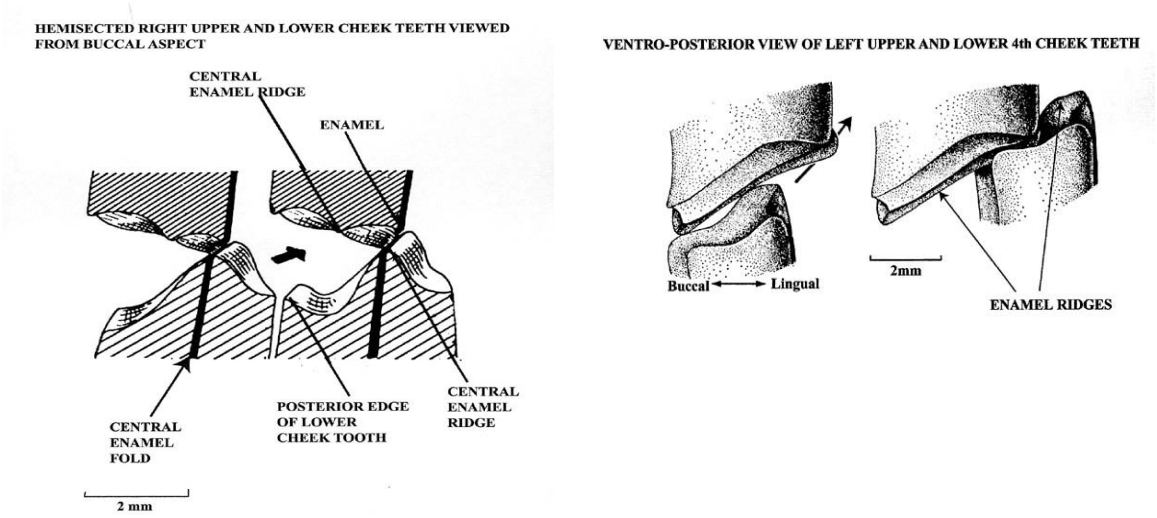

The sequence of jaw movements that take place during the Type II masticatory cycle are illustrated in Figure 11. The trajectory of the incisors during Type II mastication is illustrated in Figure 13.

© Frances Harcourt-Brown 2006

Figure 11: Jaw movement during the (Type II) chewing cycle of the domestic rabbit (*Oryctolagus cuniculus*)

From: Harcourt-Brown (2001), Textbook of Rabbit Medicine. Drawings by Nigel Harcourt-Brown based on papers by Schwartz and others (1989) and Yamada and Yamamura (1996) who plotted jaw movement during Type II mastication using electromagnetic sensors placed at various sites on the head.

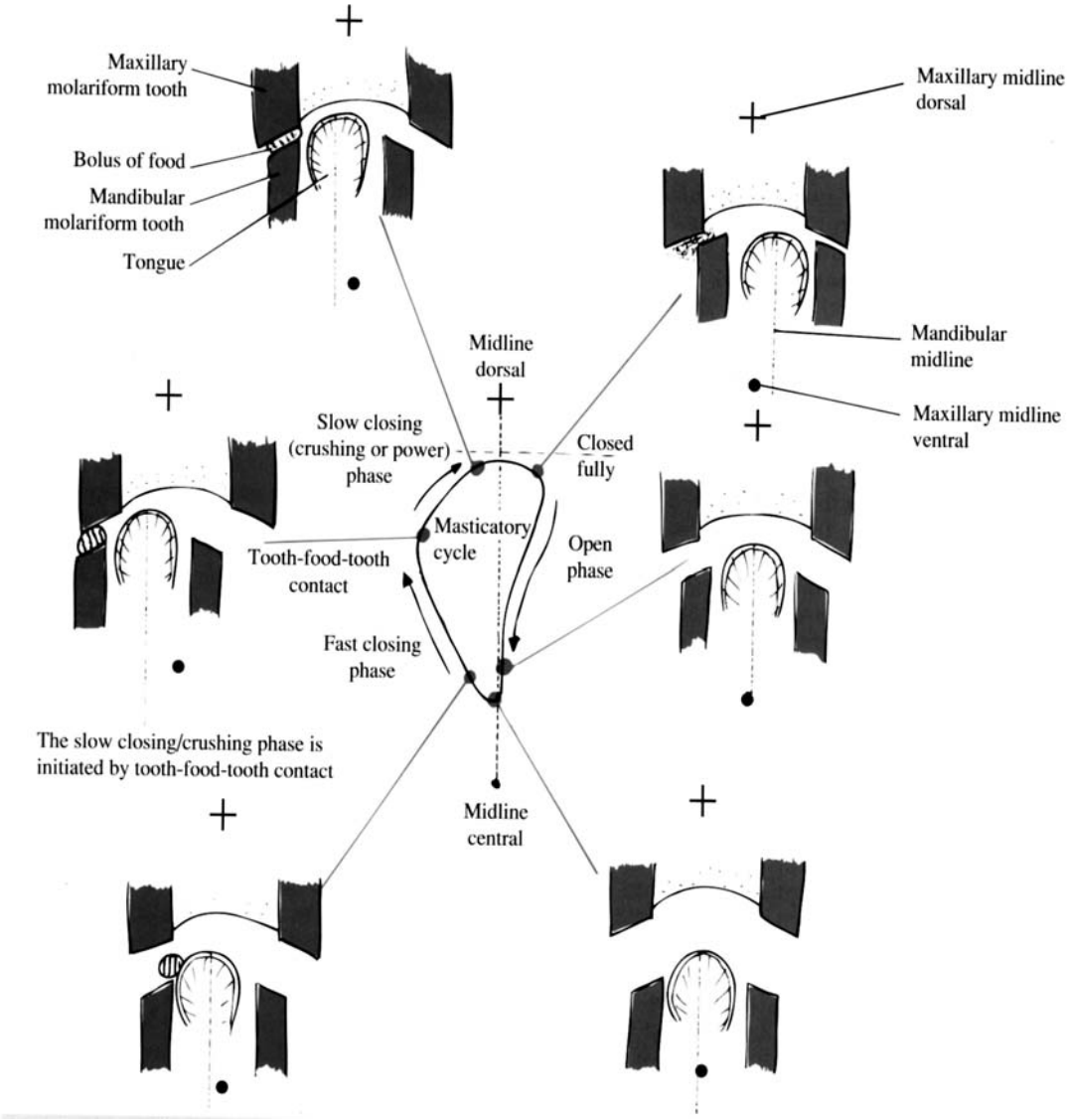

During the lateral jaw movements that occur during chewing, the tips of the lower incisors are swept transversely across the upper second incisors (peg teeth) (Ardran and Kemp, 1958).

© Frances Harcourt-Brown 2006

Effect of food texture on Type II mastication (chewing)

The basic chewing rhythm is not affected by the food texture (Yamada and Yamamura, 1996) although the force that is applied by the teeth during crushing increases in proportion to the hardness of the food. Sensory input to the feedback mechanism comes from receptors in the periodontal ligament and muscle spindles in the muscles of mastication.

Although the basic chewing rhythm is unaffected by food texture, the jaw movement does vary with the type of food that is ingested. Weijs and Dantuma (1981) compared the jaw movements of rabbits eating hay, pellets and carrots. They measured maximum gapes of 6-12º in rabbits eating hay, 7-16º in rabbits eating pellets and 11-17º in rabbits eating carrots. The lateral excursion of the mandible also varied with the diet. Lateral excursion towards the working side was found to be 4-6º in rabbits eating hay and 2-4º in rabbits eating carrots. Weijs and Dantuma (1981) also identified two types of power stroke that varied with diet. The first type is a shearing stroke in which the mandibular cheek teeth are moved lingually and rostrally (Figure 12) with minimum vertical and maximum transverse jaw excursion. This shearing action prevails during hay mastication. It occurs sometimes in pellet mastication but never in carrot mastication.

The second type of power stroke involves a lingually directed movement of the cheek teeth without the rostro-medial shearing action. There is maximum vertical gape and the result is a crushing action that is always seen in carrot mastication, sometimes in pellet mastication but never in hay mastication. These powerful shearing and crushing actions of the cheek teeth give rabbits a versatility that enables them to utilise a wide range of foods.

Figure 12: Dorsoventral views of mandibular positions at start (dashed outline) and end of crushing (A) and shearing (B) power strokes

*Drawing from: Functional anatomy of the masticatory apparatus in the rabbit (*Oryctolagus cuniculus*) Weijs and Dantuma, (1981) reproduced with permission from the auth*

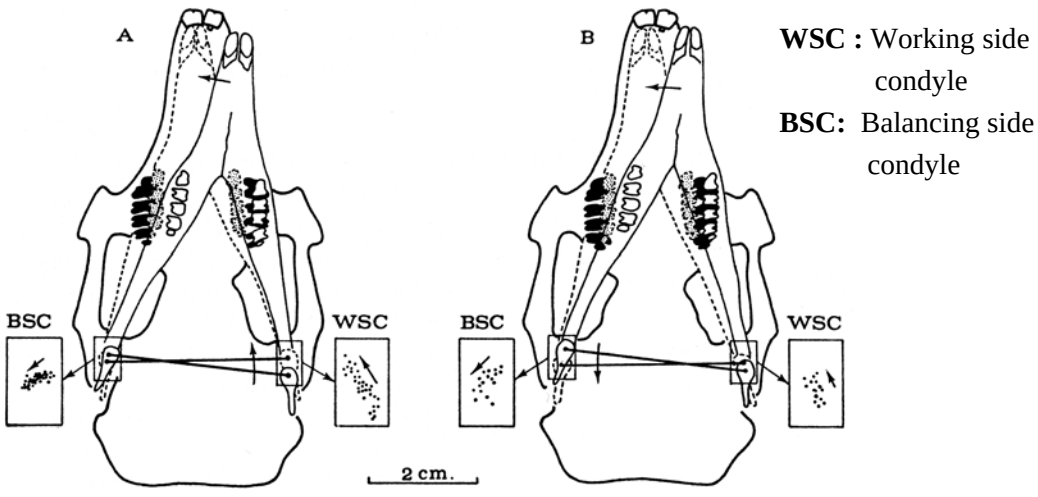

© Frances Harcourt-Brown 2006

The crushing or shearing actions of the cheek teeth during Type II mastication (chewing) affect the vertical trajectory of the jaw. This vertical component has been plotted by Weijs and Dantuma (1981) and is illustrated in Figure 13.

Figure 13: Vertical component of the trajectory of the incisors during cheek tooth mastication

From: *Functional anatomy of the masticatory apparatus in the rabbit (Oryctolagus cuniculus) (Weijs and Dantuma, 1981). Reproduced with permission from the author.*

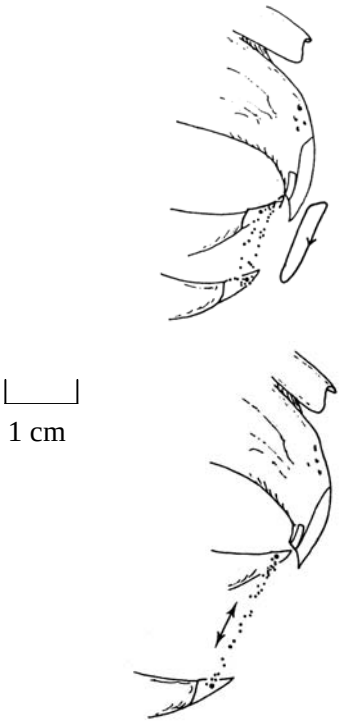

Vertical component of the trajectory of lower incisor when hay is chewed between the cheek teeth.

The trajectory is marked by the series of spots. These represent tooth markers in the upper and lower incisors. When hay is chewed, the incisor tips move forward till they touch the edge of the wear facet of the upper incisors.

Vertical component of the trajectory of lower incisor when carrots are chewed between the cheek teeth.

When the cheek teeth are crushing, rather than shearing food, the trajectory is arcuate rather than orbital as in hay mastication

© Frances Harcourt-Brown 2006

Anatomy of the skull

Figure 14: Anatomical features of the skull of the domestic rabbit (Oryctolagus cuniculus)

14a) Lateral aspect of the left mandible

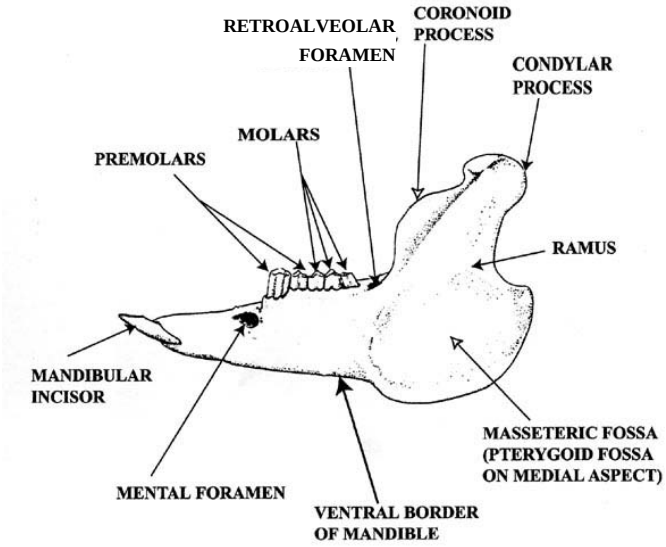

At the mandibular symphysis, the rami of the mandible are joined by strong ligaments, interconnecting bony shelves and a fibrocartilagenous pad.

Symphyseal movement is minimal and the joint is resistant to vertical shear and bending forces (Weijs and Dantuma, 1981).

14b) Lateral aspect of the skull

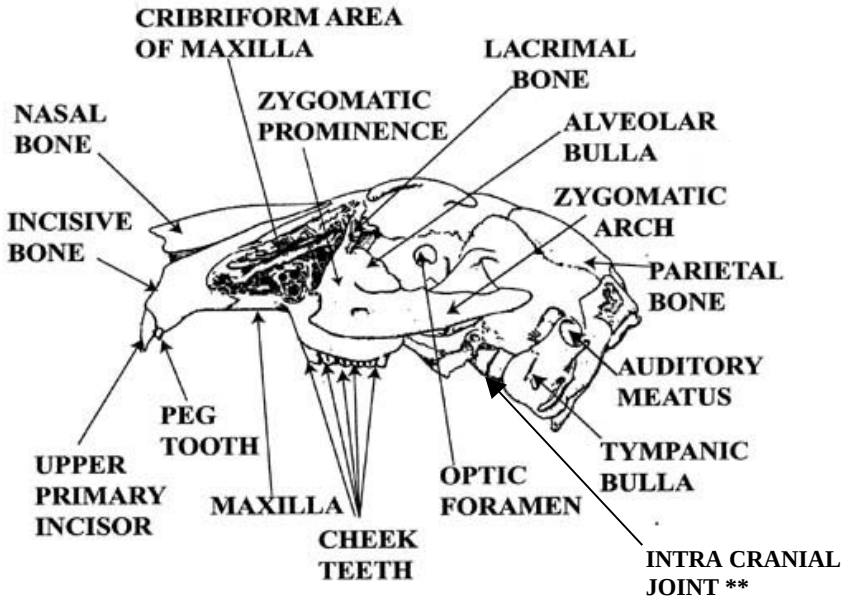

** In rabbits and hares, a suture between regions of the foetal braincase remains open in the adult, forming an intracranial joint (Kardong, 1995). This joint is seen on radiographs of the skull (Figures 27 and 28).

© Frances Harcourt-Brown 2006

14c): Ventral aspect of the skull

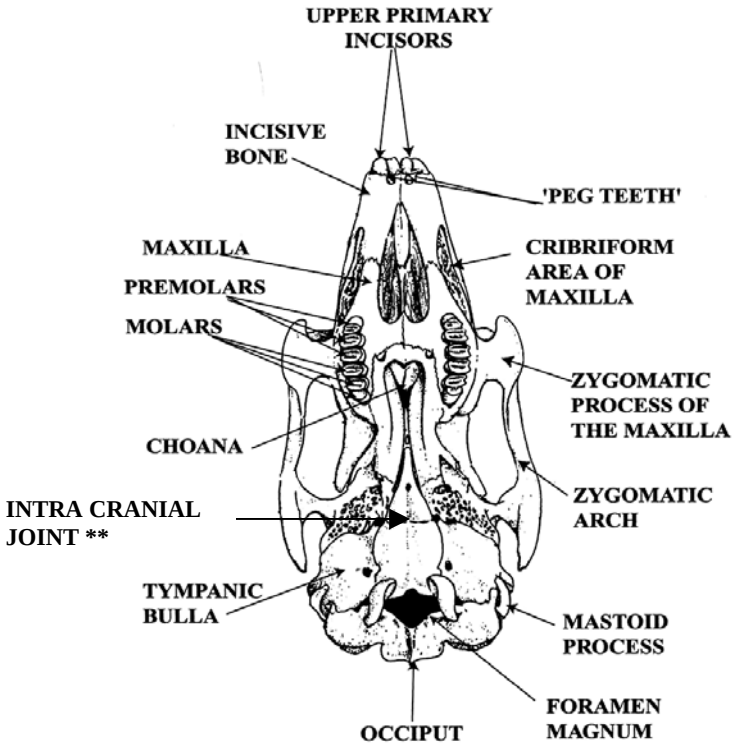

14d) Dorsal aspect of the skull

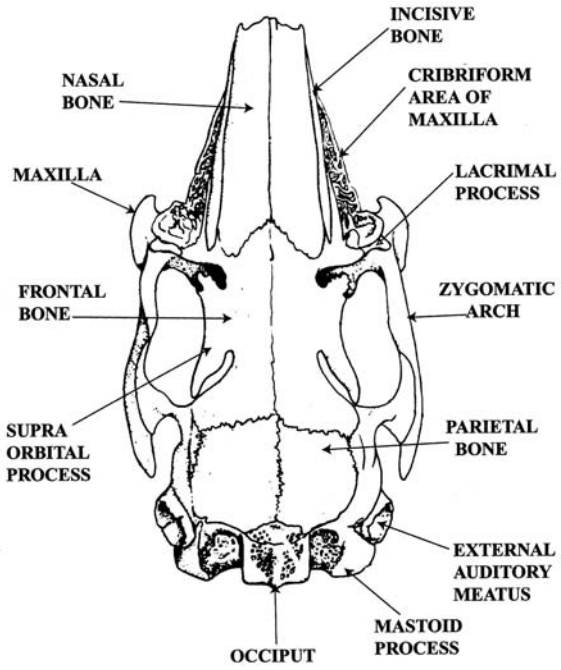

a

© Frances Harcourt-Brown 2006

Anatomy of the nasolacrimal duct of the domestic rabbit (Oryctolagus cuniculus)

There is a single aperture to the nasolacrimal duct, the *punctum lacrimale*, which is situated in the anteromedial aspect of the lower eyelid. The punctum opens into a short (2mm) canaliculus that opens into a dilation of the duct or lacrimal sac. The nasolacrimal duct leaves the lacrimal sac through a small aperture in the lacrimal bone (the lacrimal foramen) into the maxilla where it is encases in the bony lacrimal canal. This section of the nasolacrimal duct runs rostrally and medially until it reaches the root of the primary maxillary incisor (Figure 15). At this point, the duct makes an abrupt mediodorsal bend and the diameter is reduced from approximately 2mm to 1mm (Burling and others, 1991). At this point, the duct is compressed between the alveolar bone surrounding the root of the primary maxillary incisor and the nasal cartilage. The duct then courses medially, alongside the incisor tooth root and emerges in the nasal cavity at the ventromedial aspect of the alar fold, a few millimetres inside the mucocutaneous junction.

Figure 15: Anatomy of the nasolacrimal duct (NLD)

From: *Textbook of Rabbit Medicine (Harcourt-Brown, 2001). Drawings by Nigel Harcourt-Brown based on examination of prepared skulls and dissections of decalcified skulls of wild rabbits.*

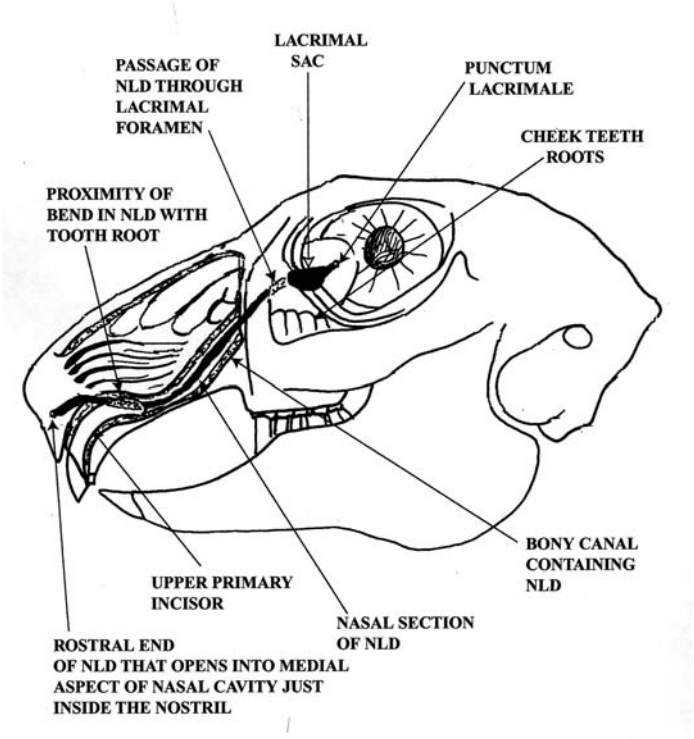

© Frances Harcourt-Brown 2006

Section 1.2: Dental disease in pet rabbits

There are only a few references to dental disease in pet rabbits in peer-reviewed literature (Lobprise and Wiggs, 1991, Brown, 1992, Crossley 1995, Harcourt-Brown, 1995*, Harcourt-Brown 1996*, Steenkamp and Crossley 1999, Harcourt-Brown, 2000*) although dental disease in rabbits is included in several review articles of dental problems of rabbits and rodents (Westerhof and Lumeij 1987, Bohmer and Kostlin 1988, Emily, 1991, Harcourt-Brown 1997*, Van Foreest, 1998, Legendre, 2002). Descriptions of dental disease in pet rabbits can be found in book chapters (Wiggs and Lobprise 1995, Wiggs and Lobprise 1995a, Crossley 1998, Crossley 2000, Crossley 2000a, Crossley 2003, Crossley 2003a, Crossley 2003b, Meredith and Crossley 2002, Harcourt-Brown 2001). Articles can also be found in publications such as *Veterinary Times*, in conference proceedings or on the Internet, although, like book chapters, this information is not peer-reviewed.

The following description of dental disease in pet rabbits is based the author's clinical experience in general practice with a large rabbit caseload. Every rabbit that visits the surgery, including those for vaccination, claw clipping or neutering, is examined for signs of dental problems.

© Frances Harcourt-Brown 2006

Dental abnormalities of that may be detected during clinical examination:

Incisor abnormalities

Some examples of abnormalities of the incisors are shown in Figure 16.

Ribbed Incisors

In a healthy rabbit, the upper first incisors have a clear vertical groove running longitudinally down the labial aspect. The enamel on the incisors is smooth and shiny (Figure 1). A common clinical finding in pet rabbits is the presence of horizontal ridges on the upper incisors giving the teeth a ribbed or 'washboard' appearance. These ridges may be found on incisors of normal shape and length

Discoloured incisors

The smooth enamel of the incisors of rabbits is normally white, cream or slightly yellow. Diseased incisors may be off-white, beige or slightly brown. This discoloration is usually seen in conjunction with ribbed enamel. There may be brown staining on the teeth

Enamel erosions

Areas of eroded enamel can sometimes be seen at the gingival margin of the upper first incisors. The defect may be filled with pink granulation tissue.

Abnormal incisor length or shape

In some rabbits, the exposed crowns of the upper or lower incisors may appear long, even though they occlude with opposing teeth. Short crowns can also be found, especially if they are opposed by long crowns. The shape of the incisors is influenced by the chewing pattern of the cheek teeth and a diagonal occlusal line indicates a long standing painful lesion on one side of the mouth (K in Figure 16).

Incisor Malocclusion

The normal occlusion of the incisors is with the cutting edges of the lower incisor teeth resting against the peg teeth just caudal to the upper first incisors. It is abnormal for the tips of the upper first incisors to rest against the tips of the lower incisors. In more severe cases of incisor malocclusion, the crowns become long and, in some cases, do not occlude at all with the opposing teeth. This type of incisor malocclusion is a common reason for presentation for veterinary treatment. Typically, the upper incisors curl outwards and the lower incisors grow forwards like tusks. The abnormality is visually obvious to the owner but there may be surprisingly few clinical signs. Affected rabbits learn to prehend food despite elongated incisors. Sometimes the teeth become so long that they catch on the cage bars or water bottles. Hair can become entwined on the elongated mandibular incisors. The curled crowns of the maxillary incisors sometimes grow into the lips or gums and damage the soft tissue.

Broken incisors

The exposed crowns of the incisors can be fractured as the result of a fall, face first, on to a hard surface. Rabbits that pull on cage bars, usually entire males, can also break their upper first incisors along the subgingival section. But most cases of broken incisors in pet rabbits are not the result of trauma. The crowns break spontaneously, often in association with dull ribbed teeth. So the absence of incisors does not always signify previous surgical removal. The crowns can break off altogether, leaving roots that are seen on lateral skull radiographs.

Gum abnormalities.

There may be areas of inflammation in the gums surrounding the incisors. Sometimes there is periodontal pus.

Absence of upper secondary incisors

Occasionally the upper second incisors or 'peg teeth' are absent (Figure 21). This is a congenital abnormality.

© Frances Harcourt-Brown 2006

Figure 16: Examples of abnormalities of the incisors that may be detected during clinical examination.



Examination of the incisors may show abnormalities of the structure, shape and occlusion of the teeth. The upper first incisors may show horizontal ribs across the enamel without any abnormality in shape or occlusion (A). However, ribbed incisors are usually an abnormal shape with abnormal occlusion (B).

Sometimes there are erosions in the enamel at the gingival margin. These may be filled with pink granulation tissue (arrow in picture C)



Abnormalities in the shape and position of the incisors result in malocclusion. The incisors may be long (D, E and F) or short (H and J). The crowns may be broken (arrow in F, G). Areas of inflammation may be seen in the gingiva (arrow 'x' in F).
Pus may be present in the socket (arrow in D).



Remnants of the incisors are usually a dull off-white colour. They may be stained brown. Some crowns may be absent altogether. The upper first incisors are missing in (H).
Not all the incisors show the same changes. 'J' show s a single healthy lower incisor among others ahowing abnormalities.
The shape of the incisors can also reflect the chewing pattern. A diagonal occlusal line (K) indicates a problem that is preventing chewing on one side of the mouth.

Abnormalities of the cheek teeth

During the course of a clinical examination, it is possible to examine the cheek teeth with the aid of illumination and magnification provided by an auriscope. This examination is limited by the small opening to the mouth relative to the long oral cavity. There may be resistance by the rabbit and the tongue can obscure the view. However, in the author's experience, it is possible to rule out dental disease by auriscopic examination of the oral cavity in a conscious rabbit, especially if the rabbit is known to be eating well. A reasonable view of the occlusal surfaces of the cheek teeth can be seen by sliding the auriscope down each side of the mouth and moving the mandible to one side to separate the upper and lower teeth (Figure 17). Some abnormalities of the cheek teeth are also illustrated in Figure 17.

Examination of the cheek teeth

In some rabbits, the exposed crowns of the upper or lower cheek teeth may vary in height. There is a corresponding variation on height in the teeth on the opposing arcade with short teeth opposing long ones. Food may be impacted between the teeth, indicating a widening of the interdental space. Pus may be seen in the periodontal pocket.

Mobile cheek teeth

Under general anaesthesia, it is possible to assess the mobility of the cheek teeth. It is not uncommon to find that cheek teeth of abnormal shape or structure are also mobile. Sometimes the exposed crown is so mobile that it pulls out easily. This is associated with a fracture of the tooth just below the gingival margin. This appears to be a spontaneous event.

Discoloured cheek teeth

The exposed crowns of the cheek teeth may be a dull beige or brown colour. This is seen in association with other abnormalities.

Defective cheek teeth

The cheek teeth may show defects such as erosions.

Absent cheek teeth crowns

In some cases, the crowns of some of the cheek teeth may be absent altogether with the gum healed across the site where the crowns should be. This is most frequently found on the lower arcade. It can occur in rabbits that have not received any dental treatment.

Soft tissue abnormalities

The tongue may show lacerations from sharp spurs on the lower cheek teeth or may show evidence of previous damage, such as scars or swellings (Figure 17). There may be areas of inflammation in the gums surrounding the cheek teeth. Sometimes the mucosa between the lingual aspect of the cheek teeth and the tongue can be hypertrophied so that it forms a flap (Figure 17). If the crowns of the teeth are short, this flap may be trapped between the teeth during chewing so that it becomes even more hypertrophied and prone to injury.

© Frances Harcourt-Brown 2006

Figure 17:
Examples of abnormalities of the cheek teeth



It is possible to examine the cheek teeth of a conscious rabbit with the aid of an auriscope to provide illumination and maginification. General anesthesia is needed for a thorough examination.

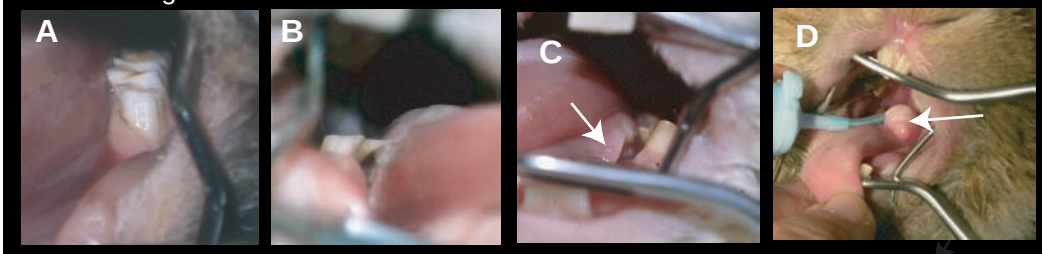

Abnormalities of the cheek teeth vary from minor variations of the height and shape of the crowns (A) to sharp spurs (B, F, G). On the lower arcade, these spurs are usually seen on the third or fourth cheek teeth and they are usually (but not always) directed towards the tongue. They may lacerate the tongue or impinge on the mucosa, which can become hypertrophied (C). As a result of these injuries, the tongue can become scarred and distorted (D).

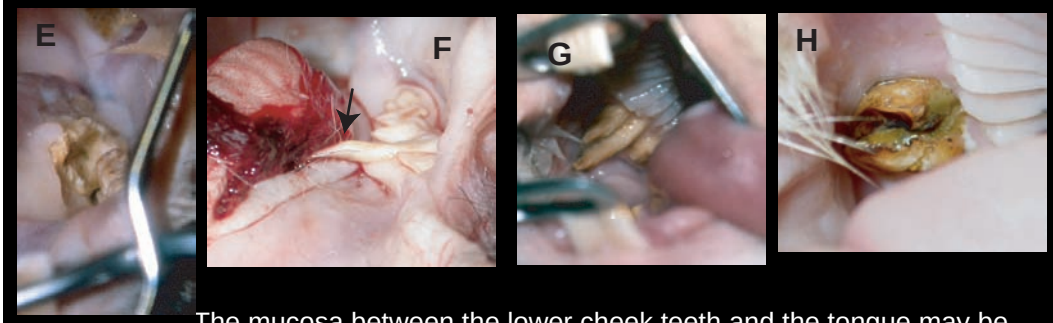

The mucosa between the lower cheek teeth and the tongue may be ulcerated because hypertrophied gum flaps (C) that are caught between the teeth during chewing. This occurs when the crowns have broken off or have been removed to leave short exposed remnants. Iatrogenic injury from dental drills can also inflict damage to this area (E) and other parts of the mouth. But it is long spurs that usually cause soft tissue damage. The spur on the lower third cheek tooth in 'F' has perforated the lingual artery. The rabbit was found dead.
On the upper jaw, spurs are found on the first and second cheek teeth and are always directed towards the cheek (G).They can penetrate the mucosa and introduce infection. Defective and discoloured (H) crowns may be detected during oral examination or the exposed crowns may be absent altogether.

Abnormalities of the face, due to dental disease, that may be detected during clinical examination

Palpable swellings along the ventral border of the mandible

A feature of dental disease in pet rabbits is elongation of the 'roots' of the teeth (i.e. the subgingival section of the tooth). Palpable, hard bony swellings along the ventral border of the mandible indicate elongated roots of the lower cheek teeth.

Facial abscesses

Facial abscesses are commonly associated with dental abnormalities. Abscesses are often found in association with periapical infection at sites where the elongated roots have penetrated the bone. Bone penetration by elongated roots occurs at typical sites around the skull (Harcourt-Brown, 1995). These are illustrated in Figure 18. Not all facial abscesses in rabbits are due to periapical infection. Bite wounds, fractured teeth and penetrating injuries from elongated sharp crowns can also cause abscesses.

Figure 18: Typical sites of bone penetration by elongated roots

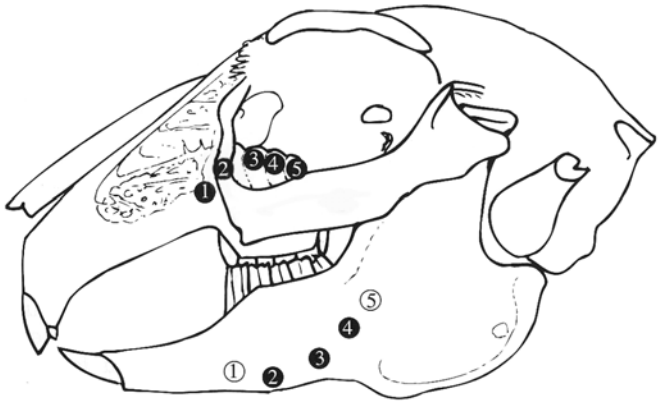

Solid circles indicate roots that curve and penetrate the lateral aspect of the skull. Empty circles indicate roots that curve medially and penetrate the medial aspect of the mandible

© Frances Harcourt-Brown 2006

Figure 19:
Facial abscesses

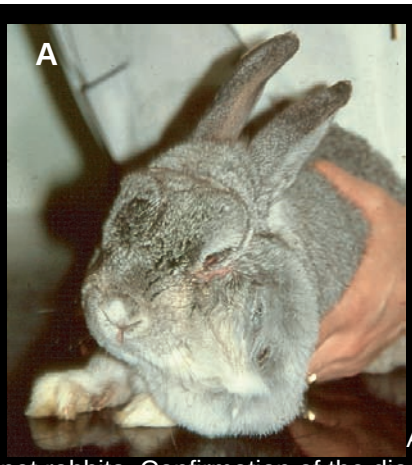



Abscesses around the face and jaws are common in pet rabbits. Confirmation of the diagnosis can be made by aspirating pus. These abscesses are often associated with underlying dental disease. Skull radiography, surgical exploration or even post-mortem examination may be needed to determine the relationship between an abscess and dental disease, especially if the abscess is large (A). In contrast, it is easy to see the relationship between abscesses and elongated crowns that are penetrating the soft tissue (B).





Localised swellings over the periapical areas where elongated roots penetrate bone indicate which tooth is involved (see Figure 18). The rabbit shown in 'C' has a periapical abscess of the second upper premolar. The rabbit in 'D' has and periapical abscess of the fourth lower cheek tooth.

C

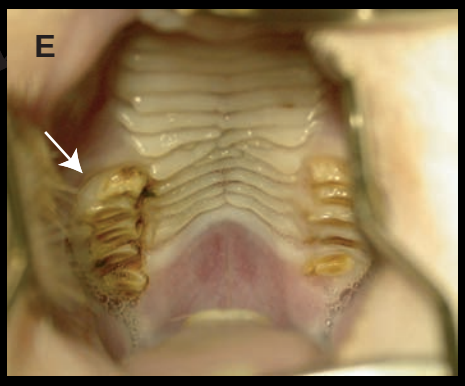



Sometimes pus can be seen in the mouth of rabbits with facial abscesses. The teeth may be loose. The rabbits shown in 'E' and 'F' have a retrobulbar abscess from infected roots of the upper cheek teeth. Pus may be seen around the teeth (arrow on E).

Clinical conditions that are secondary to dental disorders

Change in demeanour

Although they are non specific clinical signs, lethargy and depression usually accompany dental problems. Affected rabbits sit immobile at the back of a cage or hutch for long periods of time. They cease to be inquisitive. Observant owners are often able to detect the onset of dental problems by a change in their rabbit's demeanour.

Anorexia and weight loss

A healthy rabbit has a good appetite and will eat a wide range of foods including grass and hay. The first sign of dental problems is often a change in the rabbit's eating habits. It may stop eating hay or leave favourite vegetables uneaten. Absent crowns or abnormal occlusion can affect the ability to prehend and chew food. Affected rabbits may take a long time to eat or will only consume moistened or soft food. They may be hungry and attempt to eat but drop food uneaten. These rabbits may not eat sufficient food to maintain their bodyweight so they lose weight. Complete loss of appetite is a common manifestation of dental disease in rabbits. Sharp spurs that lacerate the tongue or other soft tissue can be acutely painful for the rabbit and affected animals may not even attempt to eat food. Pain and stress can slow gut motility, which, if left untreated, can result in hepatic lipidosis and death.

Epiphora and dacryocystitis

Elongation of the roots of the upper first incisors can block the nasolacrimal duct and cause epiphora. (Figure 20).

Salivation

In rabbits, saliva is continuously secreted (Fekete, 1989). Soft tissue injury within the mouth, such as a lacerated tongue or ulcerations of the oral mucosa either make swallowing saliva painful or increase the amount of saliva that is secreted. Wet fur becomes matted and soiled and secondary skin infection can ensue in longstanding cases. Saliva staining may be unilateral. This is associated with a lesion in the mouth on the same side as the staining.

Uneaten caecotrophs

The rabbit is a hindgut fermenter. It is a strict herbivore whose digestive system is adapted for the ingestion of a fibrous diet. Digestion in the stomach and small intestine is similar to monogastric animals and residual ingesta that reaches the hindgut is mainly composed of fibre that cannot be broken down by the digestive enzymes of the stomach and small intestine. In the colon, large fibre particles are separated from small particles that are simultaneously sent in opposite directions. Large particles of undigested fibre pass distally through the colon to be excreted as hard faecal pellets. Small fibre particles and fluid are sent in a retrograde direction to the caecum where they undergo bacterial fermentation. Periodically, the pasty contents of the caecum are expelled as soft faecal pellets or 'caecotrophs', which should be re-ingested directly from the anus. Caecotrophs provide an additional source of nutrients for the rabbit. Many clinical conditions, including dental disease, can interfere with the act of ingesting caecotrophs. To the owner, uningested caecotrophs have the appearance of diarrhoea. They are soft and pasty with a characteristic strong odour and may stick to the fur under the tail. Uneaten caecotrophs that stick to the fur under the tail predisposes to fly-strike.

Grooming difficulties

Dental problems interfere with grooming, either by impairing the rabbit's ability to grasp dead hair between the incisors or by making the tongue sore so the rabbit is reluctant to lick its skin and fur. The result is an accumulation of skin debris and parasites, such as *Cheyletiella parasitovorax* and *Leporacus gibbus* in the fur. Moulting compounds the situation as it is difficult or impossible for the rabbit to remove dead hair from the coat. *Cheyletiella* causes pruritis and areas of heavy scurf. Dental problems and impaired grooming and cleaning the fur also increases the risk of flystrike.

© Frances Harcourt-Brown 2006

Figure 20:
Clinical conditions associated with underlying dental disease

Epiphora





Epiphora in pet rabbits often heralds the onset of further dental problems, It is usually due to obstruction of the nasolacrimal duct by elongated roots of the first upper incisors. This can be seen on the lateral skull radiograph 'A'. Contrast material (sodium/meglumine iothalamate) has been instilled into the duct.

Dacryocystitis





Infection of the lacrimal sac and conjunctivitis, keratitis or keratoconjunctivitis are potential sequels to obstruction of the nasolacrimal duct. Pus can be expressed into the conjunctival sac by applying pressure to the medial canthus of the eye. The pus-filled duct can become very dilated as in 'B'.

Weight loss and grooming difficulties

The general condition of the rabbit is affected by dental problems.It may be thinand unkempt (C).



Salivation

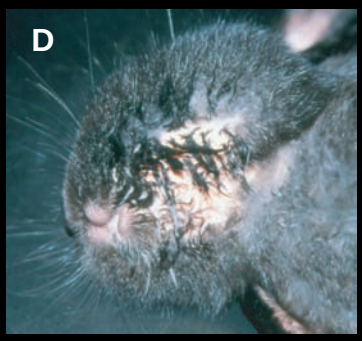

A wet chin or neck (D) is indicative of soft tissue damege within the mouth.

Uneaten caecotrophs



Dental disease is one of the underlying causes of uneaten caecotrophs sticking to the fur under the tail (E).

Section 1.3: Progressive syndrome of acquired dental disease in pet rabbits (PSADD)

Causes of dental problems in pet rabbits

Prognathism

Prognathism is a cause of incisor malocclusion. In pet rabbits, incisor malocclusion due to prognathism appears to be linked with the Dwarf breeds. These rabbits are bred for their characteristic short nosed head shape. Malocclusion is evident from an early age and many breeders cull affected rabbits before they are old enough to be sold. There are varying degrees of malocclusion. In mild cases, the incisor teeth occlude edge to edge. Once the rabbit is fully grown, this occlusal pattern does not change unless it develops other forms of dental disease. In rabbits with a greater disparity between the upper and lower jaw length, the incisors never occlude and can become very long.

Trauma

Traumatic injury to the jaws and teeth can result in abnormal dentition. Fractured jaws or broken teeth can be the result of a fall on to a hard surface or being trodden on by owners. Some rabbits break their incisors by pulling on cage bars (Figure 21).

Foreign bodies

Foreign bodies in the oral cavity can lead to secondary dental problems. Blades of hay, splinters, seeds and awns can become wedged between the teeth and set up a chronic periodontal infection. Foreign bodies are more likely to gain access to wide interdental spaces so the presence of an oral foreign body can signify another underlying dental problem.

Neoplasia

Neoplasms of the teeth, jaw or surrounding soft tissue can result in dental problems, either directly or indirectly by pushing some teeth out of position and causing malocclusion. Examples include fibrosarcomas, osteosarcomas and odontomas (Figure 21).

Progressive syndrome of acquired dental disease (PSADD)

The author of this thesis has identified a progressive syndrome of acquired dental disease in pet rabbits. Her description of the progressive nature of dental disease in pet rabbits was first published in *In Practice* (Harcourt-Brown 1997 *). Observation of the dentition of a large number of rabbits over many years has shown that the majority of pet rabbits affected by dental disease are not suffering from prognathic problems or neoplasia. Acute traumatic jaw or tooth fractures are uncommon. Instead, the vast majority of dental cases are progressive and acquired. The occlusion, shape and structure of the teeth is normal at the outset. Subsequent progressive changes in the shape, structure and position of the teeth can be staged and the author has devised a grading system based on her observations of the course of the syndrome (Box 1). Sequential skull radiographs of a rabbit that progressed through the typical stages of this syndrome are shown in Figure 22. Visual examination of prepared skulls from pet rabbits affected by this syndrome shows an apparent osteopaenia (Harcourt-Brown, 1995*) that suggests an underlying metabolic bone disease.

© Frances Harcourt-Brown 2006

Figure 21:
Some causes of dental disorders in rabbits

CONGENITAL ABSENCE OF TEETH

This hemimandible (right) has an absent lower molar so there are only four cheek teeth (A). The rabbit with a skull fracture (below) has no second upper incisors (peg-teeth) (B).

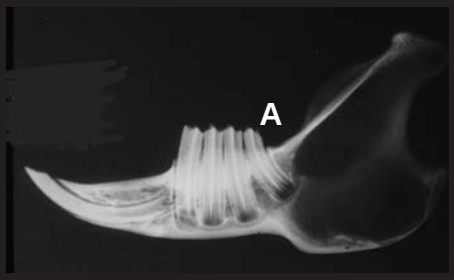

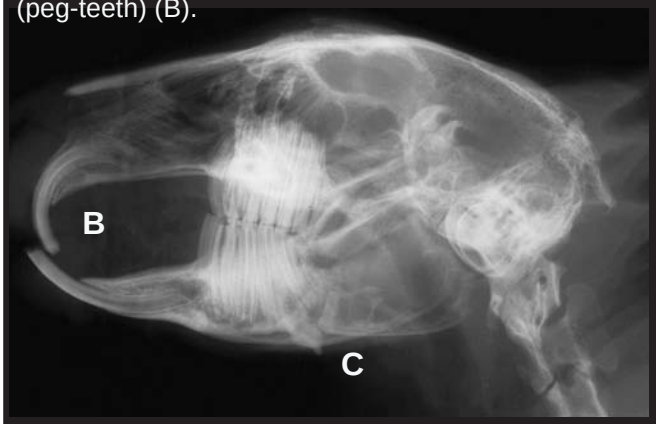

FRACTURED JAWS

Jaw fractures can lead to malocclusion. The lateral skull radiograph shown on the left shows multiple fractures on both sides of the lower jaw (C).The rostral part of the mandible has tipped ventrally.

TRAUMA

Acquired malocclusion may also be the result of fractured teeth. The rabbit shown on the right had broken the upper first incisors by pulling at the wire bars of his cage. In this case the fractured parts of the crowns were easily removed and the teeth regrew normally.





PROGNATHISM

The radiograph on the left is a lateral view of the skull of a 1year old Netherland Dwarf female with a mild prognathic abnormality. The incisors meet edge-to-edge. This condition was non-progressive. The rabbit lived to 4 years of age

Prognathism can cause severe incisor malocclusion. The pictures on the left show a big disparity in length of the upper and lower jaws





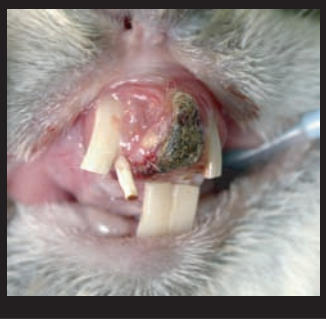

NEOPLASIA

As in other species, neoplasms of the oral cavity can loosen and displace teeth. The rabbit shown on the left had a fast growing tumour involving the upper jaw that had separated the incisors.

Box 1: Grading the progression of acquired dental disease in pet rabbits

Grade 1: Normal

Grade 2: Root elongation, uneven teeth and/or enamel defects.

At this stage, there are usually no clinical problems that are obvious to the owner of the rabbit. But examination of the teeth and surrounding structures reveals abnormalities:

- The incisors may or may not have horizontal ribs in the enamel although the shape of the teeth and occlusion can be normal.
- Hard swellings may be felt along the ventral border of the mandible. These are associated with elongated roots of the mandibular cheek teeth.
- Epiphora may be present. This is caused by obstruction of the nasolacrimal duct by elongated roots of the upper primary incisors
- The enamel ridges across the centre of the occlusal surfaces of cheek teeth may be lost so there no longer occlude in a zigzag pattern. The height of the crowns may be uneven

Grade 3: Acquired malocclusion

Malocclusion is the result of alterations in the position and shape of the teeth, which alters the way they occlude:

- The mandibular incisors tend to tip forward.
- The maxillary incisors curl and rotate laterally.
- The mandibular cheek teeth curl towards the tongue
- The maxillary cheek flare towards the buccal mucosa.

This stage is associated with a range of clinical problems such as incisor malocclusion that is obvious to the owner, anorexia, grooming difficulties, uneaten caecotrophs, perineal soiling, cheyletiellosis and fly strike. Purulent dacryocystitis may or may not be present.

The changes in shape, structure and position do not take place in all teeth simultaneously. It is possible to have healthy incisors and major changes in the cheek teeth or *vice versa*.

Grade 4: Cessation of tooth growth

This stage is characterised by teeth that are no longer growing although this seldom happens in all the teeth simultaneously. Any teeth that continue to grow will grow in an aberrant fashion. The exposed crowns of the non growing teeth may remain *in situ* as stumps or break off altogether and the gums heal. Affected rabbits can manage to eat with any teeth that remain in occlusion. The rabbit's overall condition may be good at this stage as long as there are no sharp spurs penetrating soft tissue. Or there may be grooming difficulties because of absent or non occluding incisors. There may be recalcitrant epiphora and dacryocystitis.

Grade 5: Endstage dental disease

This stage is characterised by the absence of functional teeth although there may be remnants of exposed crowns. Affected rabbits are usually, but not always, thin and debilitated. They can only eat softened food. Abscesses, epiphora, chronic dacryocystitis, rhinitis and grooming difficulties are common.

© Frances Harcourt-Brown 2006

Figure 22: 'Flopsy Nicholls'
Case report to show progressive nature of acquired dental disease:

Flopsy Nicholls was an entire 2.5kg black mixed breed rabbit that was a typical case of the progressive syndrome of acquired dental disease (PSADD). The changes in the shape, structure and position of the teeth can be seen in this sequence of radiograph of his skull.

FEB '95-Age 1yr 6m
(GRADE 2):
Reason for presentation :
Epiphora



JULY '95
(GRADE 2)
Reason for presentation:
Fell and fractured incisors

OCTOBER '95
(GRADE 3)
Reason for presentation:
Anorexia and salivation due to sharp spur on left lower third cheek tooth.



OCTOBER '96
(GRADE 4)
Reason for presentation:
Dacryocystitis (Dacrocystogram illustrated on dorsoventral view)

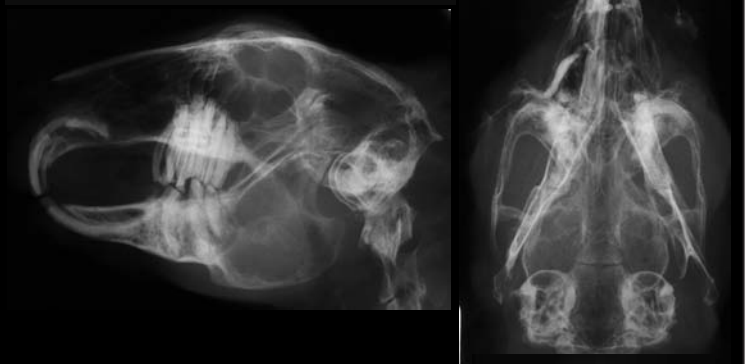

DECEMBER '99
(GRADE 5)
Reason for presentation:
Euthanased because of an abscess
Age 6y

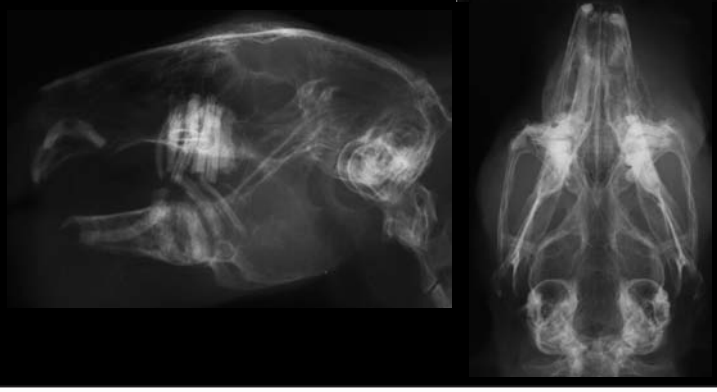

Section 1.4 General overview of calcium metabolism and metabolic bone disease

Calcium is involved in number of physiological processes that are necessary for life i.e. muscle contraction, nerve cell activity, blood clotting, enzyme activity, hormone release and membrane permeability. Input of calcium is from the diet. Calcium lost from the body in pancreatic and biliary secretions, sweat, milk production, foetal growth and, in species with continually erupting teeth, tooth formation. Bone acts as a reservoir for calcium and other minerals such as phosphorus and magnesium.

Dietary calcium is absorbed across the intestinal mucosa and is achieved by two parallel processes: active vitamin D dependent transcellular transport and passive paracellular diffusion (Breslau 1996, Rosol and Capen, 1997). Passive diffusion is bidirectional and depends on the concentration gradient between the intestinal lumen and the blood. Active calcium transport through cells is complex. It requires carrier proteins that are synthesised in the intestinal mucosa in response to vitamin D. The active transport system mechanism can adjust according to the amount of calcium in the gut. Absorption is increased if intestinal calcium concentrations are low and are decreased if concentrations are high. Intestinal absorption of phosphorus is stimulated by vitamin D and there is an interrelationship between vitamin D, calcium and phosphorus concentrations both in the blood and in the gut. Excessive dietary phosphate affects intestinal absorption of calcium by forming insoluble complexes in the gut. In blood, calcium and phosphate concentrations are close to their solubility product, so an increase in either ion causes a reciprocal decrease in the other.

Box 2: Calcium absorption from the small intestine

Calcium is absorbed from the small intestine either by:

- Active transport across the cell membrane bound to a carrier protein synthesised in response to circulating vitamin D ($1,25(OH)_2D$) levels. $1,25(OH)_2D$ synthesis is stimulated by hormones i.e. PTH, growth hormone, testosterone, oestrogen.
- Passive diffusion across a concentration gradient between intestinal contents and blood. This process is not regulated and mainly takes place in the jejunum and ileum.
- Convection i.e. passive movement of calcium between cells with the flow of water. This mechanism plays a minor role in calcium absorption from intestine (but is important in renal reabsorption/ excretion of calcium).

Factors that affect calcium absorption from gut:

- Dietary calcium levels i.e. intestinal concentrations.
- Circulating levels of the active form of vitamin D ($1,25(OH)_2D$). Availability of calcium for absorption. Calcium is absorbed in its ionic form so the pH of ingesta affects absorption. Lower pH increases absorption.
- Ions that bind with calcium such as phytates, oxalates and phosphate impair calcium absorption.
- Fats that bind with calcium and reduce absorption.
- Bile salts increase absorption, so any disease that reduces biliary secretion (e.g. liver or small intestinal disease) will also reduce calcium absorption.
- Lactose aids calcium absorption.
- Glucocorticoids and thyroid hormone can decrease calcium absorption
- Drugs, e.g. furosemide increases calcium absorption from gut

© Frances Harcourt-Brown 2006

Hormonal regulation of blood calcium concentrations

Hormones, mainly parathyroid hormone (PTH), vitamin D and calcitonin, regulate blood calcium concentrations. Parathyroid hormone (PTH) is released from the parathyroid glands in response to low serum ionised calcium concentrations or to low $1,25(OH)_2D$ concentrations. This hormone stimulates osteoclastic activity to release calcium from bone. PTH also decreases urinary calcium excretion and increases phosphorus excretion, so that blood calcium levels are raised but not phosphorus levels. PTH stimulates conversion of 25(OH)D to $1,25(OH)_2D$, the active metabolite of vitamin D, in the kidney. These actions result in an increase in serum calcium concentrations that inhibits PTH release from the parathyroid glands forming a negative feedback system. PTH also has the potential to serve as an anabolic agent in bone and increase bone mass (Rosol and Capen, 1997).

Vitamin D is both a vitamin and a hormone. It has a range of physiological effects in addition to its role in calcium metabolism. Vitamin D receptors are found in a many tissues including the stomach, brain, pituitary gland, gonads, parathyroid glands, epidermis, dermis, monocytes and activated T and B lymphocytes (Holick, 1990). From a functional point of view, the main role of vitamin D is to regulate sufficient calcium and phosphorus absorption and excretion to ensure mineralisation of bone matrix whereas PTH maintains optimum extracellular fluid concentrations. Vitamin D has a direct effect on bone mineralisation and remodelling (Underwood and Deluca 1984, Deluca 1986) due to its stimulatory effect of osteocalcin synthesis. Osteocalcin is protein that is produced by osteoblasts (Canalis, 1996).

Calcitonin is produced in the parafollicular cells of the parathyroid and released in response to increased blood calcium levels. It is linked with gastrin secretion and is involved in preventing a post prandial surge in calcium absorption. Calcitonin has the opposite effect to PTH. It depresses serum calcium and phosphorus concentrations by inhibiting osteoclastic activity. Calcitonin has no effect on vitamin D synthesis and little effect on intestinal calcium absorption. It increases urinary calcium excretion. In general, calcitonin has a minor role in calcium homeostasis except during growth, pregnancy and lactation.

Blood calcium concentrations

There is a complex relationship between calcium, phosphate and magnesium concentrations in the blood. Calcium is in blood in three forms:

1. Ionised
2. Complexed with other anions (e.g. phosphate, lactate. bicarbonate, citrate)
3. Bound to protein (especially albumin).

Because of the protein binding capacity of calcium, total serum calcium concentrations are proportional to protein concentrations and any condition that affects protein synthesis or increases protein loss can affect total blood calcium concentrations. Albumin has an affinity with calcium and it is not possible to consider total blood calcium levels without considering albumin levels. Ionised calcium is the physiologically active component and is involved in neuromuscular and neural activity. Hypocalcaemia is a life threatening condition. In many species, a high demand for calcium during late pregnancy and lactation can result in hypocalcalcaemic tetany. Diseases such as renal, pancreatic and neoplastic disorders can alter serum calcium concentrations.

© Frances Harcourt-Brown 2006

Metabolic bone disease

Imbalances of calcium, phosphorus and vitamin D can result in skeletal abnormalities such as deformed bones or loss of bone density. These diseases are generally known as 'metabolic bone disease'. This is defined by Blood and Studdert (1999) as '*a range of bone diseases associated with metabolic diseases, e.g. secondary hyperparathyroidism, rickets and osteoporosis'.* In some cases, the aetiopathogenesis of metabolic bone disease is complex and multifactorial. For example, in humans, osteoporosis is a serious bone disease that is most common in post-menopausal women. It is defined by Wasnich (1996) as '*a metabolic bone disease characterised by low bone mass and microarchitectural deterioration of bone tissue, leading to increased bone fragility and a consequent increase in fracture risk*'. Risk factors for human osteoporosis include age, genetic predisposition, environmental factors, endogenous hormones, chronic disease and physical characteristics of bone. Genetic predisposition, calcium balance, vitamin D metabolism, hormonal factors, especially oestrogen, all appear to play a role. Bodyweight and physical activity can also influence bone mass (Marcus, 1996) and are therefore implicated in osteoporosis.

Most metabolic diseases of bone are characterised by loss of bone mass. Osteopaenia is the result of any condition that interferes with mineralisation or condition that interferes with protein metabolism. This can affect the formation of collagenous osteoid so there is no framework for mineralisation. Examples include parasitism, malnutrition, starvation or hyperadrenocorticism. Hormonal imbalances can result in osteopaenia because hormones, such as thyroid hormone, oestrogens or growth hormone, influence bone metabolism. Lack of oestrogen leads to reduced synthesis of $1,25(OH)_2D$ and increased osteoclastic activity (Breslau, 1996).

Interference with vitamin D synthesis may be manifested by skeletal abnormalities. For example, diseased kidneys may fail to excrete phosphate, which results in hyperphosphataemia and hypocalcaemia. This results in increased levels of PTH and demineralisation of bone. Conversion of $25(OH)D$ to $1,25(OH)_2D$ is also impaired, resulting in poor intestinal calcium absorption and falling blood calcium levels.

Box 3: Causes of osteopaenia in animals (From Lamb 1990, Dennis, 1989).

Generalised osteopaenia

- Nutritional secondary hyperparathyroidism
- Renal secondary hypoparathyroidism
- Hyperadrenocorticism
- Idiopathic senile osteopaenia
- Rickets
- Starvation
- Parasitism
- Diabetes mellitus
- Liver disease,
- Primary hyperparathyroidism
- Multiple myeloma
- Lymphosarcoma
- Oestrogen deficiency
- Drugs (some anticonvulsants)
- Growth hormone deficiency

Localised osteopaenia is seen in paralysed, immobilised or unused limbs

© Frances Harcourt-Brown 2006

Nutritional secondary hyperparathyroidism in animals

If a group of animals are affected by skeletal abnormalities, it is most likely to be due to incorrect diet or husbandry rather than hormonal imbalance or kidney disease. Osteopaenia is usually due to a deficiency in calcium and/or vitamin D to an imbalance of calcium and phosphorus in the diet. Falling blood calcium concentrations stimulate PTH release from the parathyroid glands, which in turn stimulates osteoclastic activity and resorption of bone to raise blood calcium levels. Because of these homeostatic mechanisms, blood calcium levels are defended at the expense of bone and may not be measurably low in animals with nutritional secondary hyperparathyroidism. However, PTH levels are high, hence the term 'nutritional secondary hyperparathyroidism'. Nutritional secondary hyperparathyroidism is defined in *Saunders Comprehensive Dictionary* (Blood and Studdert,1999) as *' a disease of horses, pigs, goats, dogs, cats and rarely cattle. It is commonly caused by an excessive dietary intake of phosphorus in the absence of calcium, which in horses is likely to be the result of a diet mainly of grain and in dogs and cats one predominantly of meat, but it may also result from other dietary causes of secondary hyperparathyroidism. In most species there is swelling of the maxillae and mandibles, which is most marked in horses, loosening of the teeth, shifting lameness and, particularly in dogs and cats, weight bearing skeletal deformities and folding or compression fractures, Called also miller's disease, bran disease, bighead, Siamese cat disease, paper-bone disease.*

Dietary phosphate can be an important factor in the development of nutritional secondary hyperthyroidism. Hydroxyapatite in bone contains calcium and phosphorus in a fixed ratio so an absolute deficiency of either mineral can result in reduced bone deposition. But the ratio of calcium to phosphorus in the diet is also important. Excessive dietary phosphate reduces intestinal absorption of calcium by forming insoluble complexes in the gut and by suppressing conversion of 25(OH)D to 1,25$(OH)_2$D in the kidney.

Diagnosis of metabolic bone disease

Radiology

Because of its dense nature, structural differences in bone are seen on radiographs. Disease can alter the shape, architecture, density and outline of bone. Although focal lesions may be due to trauma, inflammatory, infectious or neoplastic process, generalised changes are due to metabolic bone disease. The density of bone on radiographs is related to the amount of mineral that is present although radiography is not a sensitive tool for assessing the degree of bone loss. It has been estimated that 20-40% of the bone mass must be lost before a decrease in bone density is seen on radiographs (Genant, 1996). Other authors give a higher figure of 30-50% (Lamb, 1990) or 30-70% (Dennis, 1989). Interpretation by the person viewing the film plays a major part in the assessment of radiodensity. Radiodensity is also influenced by factors such as exposure, film processing, size of the patient etc. Osteopaenia can be differentiated from overexposure or processing faults by comparing bones with adjacent soft tissue. In children, radiography is used to assess bone loss by measuring cortical thickness at specific sites, such as the second metacarpal bone (Shore and Poznanski, 1996). Standard measurements are derived from typical populations. This type of information is not available for animals

Quantitative measurement of bone mineral density

In humans, several advanced techniques, such as single or dual-photon absorptiometry, dual energy X-ray absorpiometry (DXA) and computed tomography (CT) scanning can be used to quantify bone loss. DXA is used to screen post-menopausal women for osteoporosis and measures bone mineral at multiple sites. Bone mineral density assessment using these techniques is expensive due to the cost of the equipment and it is not generally available for veterinary patients. Good results depend on the skill of the operator who must give attention to positioning using clearly defined landmarks (Grier and others, 1996).

© Frances Harcourt-Brown 2006

Biochemical assays

Routine blood tests for metabolic bone disease are seldom diagnostic. Blood calcium and phosphorus levels may be low in association with metabolic bone disease although results are often within the reference range because homeostatic regulation maintains blood levels at the expense of bone. Alkaline phosphatase levels may be elevated, especially in young animals suffering from rickets, but young animals have higher blood levels of alkaline phosphatase than adults anyway and elevated values may be a non-specific reflection of other clinical conditions such liver or intestinal disease.

Biochemical markers

There are some biochemical and hormonal markers of bone turnover. Examples include elevated serum or urinary levels of osteoclast-derived enzymes or collagen breakdown. These reflect resorption, whereas osteoblast associated proteins or poly peptides associated with collagen synthesis reflect bone formation. In humans bone specific alkaline phosphatase, osteocalcin and collagen propeptides are examples of biochemical markers of bone turnover.

Parathyroid hormone assays (PTH)

Parathyroid hormone (PTH) is an 84 amino acid, single chain polypeptide. Circulating PTH is a mixture of intact hormone and fragments of the molecule. Radioimmunoassays have been developed that recognise specific regions of the molecule and a two site assay is used to detect the intact biologically active molecule (Barber and others, 1993). Measurement of blood PTH levels is indicated in metabolic bone disease and is an assay that is available in veterinary medicine.

Vitamin D assays

Although several vitamin D metabolites can be assayed, it is usually 25(OH)D and/or $1,25(OH)_2D$ that are measured and assays are available that can be used on animals. As vitamin D deficiency develops, PTH secretion maintains conversion of 25(OH)D to $1,25(OH)_2D$ in the kidney. Therefore blood levels of $1,25(OH)_2D$ are maintained while levels of 25(OH)D are gradually depleted. In humans, low blood levels of 25(OH)D almost always indicate deficient cutaneous synthesis or insufficient dietary intake of vitamin D (Clemens and Adams, 1996). A low blood $1,25(OH)_2D$ concentration is more difficult to interpret. Although it could indicate vitamin D deficiency, low blood $1,25(OH)_2D$ may also reflect a problem with conversion of 25(OH)D to $1,25(OH)_2D$ perhaps due to renal disease or hypoparathyroidism. Also, any condition, such as liver or kidney disease, that affects protein synthesis or increases protein loss can deplete blood 25(OH)D concentrations due to low serum calcium levels stimulating PTH secretion. Hyperphosphataemia suppresses PTH secretion and reduces conversion of 25(OH)D to $1,25(OH)_2D$.

In animals, it is possible to differentiate between vitamin D derived from plants from vitamin D that is synthesised in the skin by measuring 25(OH)D2 and 25(OH)D3 (Smith and Wright, 1984).

Vitamin D intoxication results in high levels of 25(OH)D that suppress the negative feedback of $1,25(OH)_2D$ and 25(OH)D so that 25(OH)D levels are high but $1,25(OH)_2D$ levels are normal or even low.

© Frances Harcourt-Brown 2006

Bone ash analysis

Bone ash analysis measures the mineral content of bone and can be used to investigate metabolic bone disease. Samples of bone are weighed and then heated to 600°C until there is no more weight loss. The ash is weighed and analysed for its mineral content. The ash content is expressed as a percentage of 'dry fat free bone' and each mineral, usually calcium, phosphorus and magnesium are expressed as a percentage of the ash, so one variable is expressed as a percentage of another variable.

There are several problems associated with bone ash analysis. Normal values for a particular species may be unavailable and the mineralisation of bone is affected by the age of the animal and its activity. Ash content of different parts of the skeleton varies so a comparison can only be made using a sample of bone taken from the same site from each animal.

Histopathology

The histological appearance of bone, collagen and cells reflect the modelling and remodelling activity and can be used to diagnose bone disease. Histologically, metabolic bone disease is most obvious in cancellous bone. Various staining techniques are available to show collagen, mucopolysaccharides, calcifying cartilage, reticulin and the various cells that are present (Page, 1977). Additional information can be gained from radiography of specimens of bone. Although bone biopsies can be taken from the live animal, it is not easy to obtain representative samples and the results are influenced by the biopsy site. In humans, histological examination of bone is used as a diagnostic aid using iliac bone biopsies, but in animals, most investigations involve material obtained during *post mortem* examination. Histological examination of teeth is similar to bone, except that dental tissue is harder and more difficult to section.

In order to prepare sections, most bone samples are decalcified prior to preparation. This renders the tissue useless for diagnosis of disorders of skeletal calcification (Teitelbaum, 1980). Preparation of non decalcified specimens requires the tissue in plastic rather than paraffin and using heavy duty microtomes and blades. Ground sections can be used for the study of mineral content.

© Frances Harcourt-Brown 2006

Section 1.5: Aspects of calcium metabolism and metabolic bone disease in rabbits

Laboratory investigations show several characteristics of the calcium metabolism of rabbits that differ from other species. Despite the continual eruption and growth of rabbit's teeth, laboratory investigations of calcium metabolism in rabbits seldom include examination of the teeth. Most studies are conducted on young laboratory rabbits, mainly New Zealand Whites, housed individually and fed on a standard laboratory ration.

Intestinal absorption of calcium in rabbits

In rabbits, vitamin D does not appear to play the same regulatory role in intestinal calcium absorption as in other species (Bourdeau and others1986, Kamphues and others 1991). Passive absorption is the main mechanism of calcium uptake and can continue in the absence of vitamin D if dietary calcium concentrations are adequate. However, vitamin D does increase intestinal absorption of calcium in rabbits (Tvedegaard, 1987) and is required if dietary calcium levels are low (Brommage and others1988). As absorption is passive, there is no feedback mechanism regulating intestinal absorption so calcium is absorbed according to the concentration gradient between intestinal contents and blood rather than metabolic need. This means that amount of calcium that is absorbed is proportional to the dietary calcium concentration. Cheeke and Amberg (1973) fed a very high dietary level of calcium (10 % calcium carbonate) to rabbits and rats. They found that 59% of the ingested calcium was excreted in the urine of the rabbits, in comparison with 2% in rat urine. Rat faeces contained 92.7% of ingested calcium in comparison with the rabbit faeces that only contained 19.8%.

Factors such as oxalates, phytates, phosphates in the gut influence the availability of calcium for absorption. For example, Cheeke and others (1985) found that 49% of calcium in calcium oxalate is absorbed by rabbits.

Calcium excretion

As in other species, calcium is secreted into the gut in pancreatic and biliary secretions. This process is independent of serum calcium concentrations and can take place in a hypocalcaemic animal. It has been demonstrated that secretion of calcium into the gut continues during periods of calcium deprivation in rabbits. (Barr and others, 1991).

It is the rabbit kidney that plays a major role in calcium regulation. It is capable of excreting or conserving calcium according to metabolic need. Responses are mediated by PTH and vitamin D (Bourdeau and others, 1988). Tubular reabsorption of calcium by the kidney increases during periods of calcium deprivation (Bourdeau and Lau, 1992) and decreases during periods of high calcium intake. Because intestinal absorption of calcium in proportional to the concentration of calcium in the gut, the excretion rate of calcium can be proportional to dietary intake (Kennedy, 1965) and during periods of high calcium intake the rabbit kidney is capable of increasing the fractional excretion of calcium into the urine considerably (Whiting and Quamme, 1984).

Excreted calcium precipitates as calcium carbonate in the alkaline urine of rabbits. Sediment is a normal finding although high dietary calcium intake results in larger amounts of urinary sediment. Pregnant, lactating or growing rabbits or those that are anorexic or on a calcium deficient diet excrete clear urine. Rabbits with renal disease may excrete clear urine (Harcourt-Brown, personal observation) presumably due to impaired calcium excretion..

Blood calcium concentrations

The total serum calcium concentrations of rabbits vary over a wide range and are 30-50% higher than other mammals (Buss and Bourdeau, 1984). In most species, ionised blood calcium levels are regulated within a narrow range of 1.15-1.35mmol/l (Caple, 1995) but in rabbits, ionised serum calcium concentrations are in the range of 1.71 + 0.11mmol/l (Warren and others 1989, Kamphues and others 1986).

© Frances Harcourt-Brown 2006

Not only are ionised blood calcium levels higher than other species but total serum calcium concentrations of rabbits reflect dietary calcium intake (Chapin and Smith 1967a, Chapin and Smith 1967b, Kamphues 1991). Whiting and Quamme (1984) found that rabbits on a low calcium diet (0.29%) showed lower serum calcium values than those on a normal diet (0.61% calcium) although higher serum calcium values were not demonstrated in rabbits on a high calcium diet (1.89%). Kamphues and others (1986) compared the effect of high dietary calcium on growing rabbits (5-19 weeks old) and adult rabbits (1 year old) and found that serum calcium concentrations were not as variable in the growing rabbits as in the mature ones. Other authors have reported this age influence on high dietary calcium and blood levels (Gilsanz and others, 1991).

It is not clear why rabbits have higher blood calcium levels than other species. Experimentally, hypocalcaemia or hypercalcaemia can be brought about by the infusion of EDTA or calcium gluconate. Reciprocal elevations in PTH or calcitonin in response to EDTA or calcium gluconate infusion indicate that these hormones regulate serum calcium concentrations in rabbits as in other species (Warren and others 1989, Bourdeau and others 1986). However, rabbits appear to differ from other species in the level at which serum ionised calcium is set to initiate a PTH response i.e. 1.7mmol/l rather than 1.2mmol/l (Warren and others, 1989).

Hypocalcaemia is rare in rabbits, although lactation tetany has been reported in nursing does (Barlet, 1980). Experimentally, hypocalcaemic tetany can be induced by parathyroidectomy (Tan and others, 1987) or by feeding diets deficient in calcium or vitamin D. (Chapin and Smith 1967a, Bourdeau and others 1986, Swan and Salit 1941).

Calcification of bone

There have been several studies of the influence of dietary calcium or vitamin D on the calcification of bone in rabbits. Chapin and Smith (1967) investigated the calcium requirement of growing rabbits. They found that a minimum of 0.22% of calcium in the diet is required to support normal growth but a level of 0.44% is required for bone calcification.

Because laboratory rabbits are used as models of human osteoporosis, a low calcium diet is frequently used to stimulate bone resorption (Kim and others, 1998). Gilsanz and others (1991) induced reduced vertebral bone density in rabbits by feeding a calcium deficient diet (0.15%). Another study by Wu and others (1990) showed that mature rabbits suffered a 20% vertebral bone loss after only 14 weeks on a calcium deficient (0.1%) diet. In a more recent study, the effect of dietary calcium levels on the skeletal mass of growing female rabbits was investigated (Norris and others, 2001). Bone mineral density of the lumbar spine was measured using dual-energy X-ray absorpiometry (DXA) in two groups of rabbits fed on either 0.5% or 1% calcium. They found significantly higher PTH concentrations and lower bone density in the group fed on 0.5% calcium suggesting that the higher levels may be beneficial for bone growth in rabbits. These laboratory investigations suggest that a dietary calcium level of 0.6-1% is optimal for rabbits.

Calcification of the teeth

The constant process of dental growth and attrition in rabbits results in a high demand for calcium for the continual formation of dental tissue. The rate of incisor growth is approximately 2mm per week (Shadle, 1936), which gives an idea of the calcium demand. The efficient passive absorption of calcium from the gut is a way of meeting that demand and effectively recycling calcium that is worn from the teeth and swallowed.

The circulation of calcium around the body in rabbits is summarised in Figure 23.

© Frances Harcourt-Brown 2006

Figure 23: Calcium circulation in rabbits

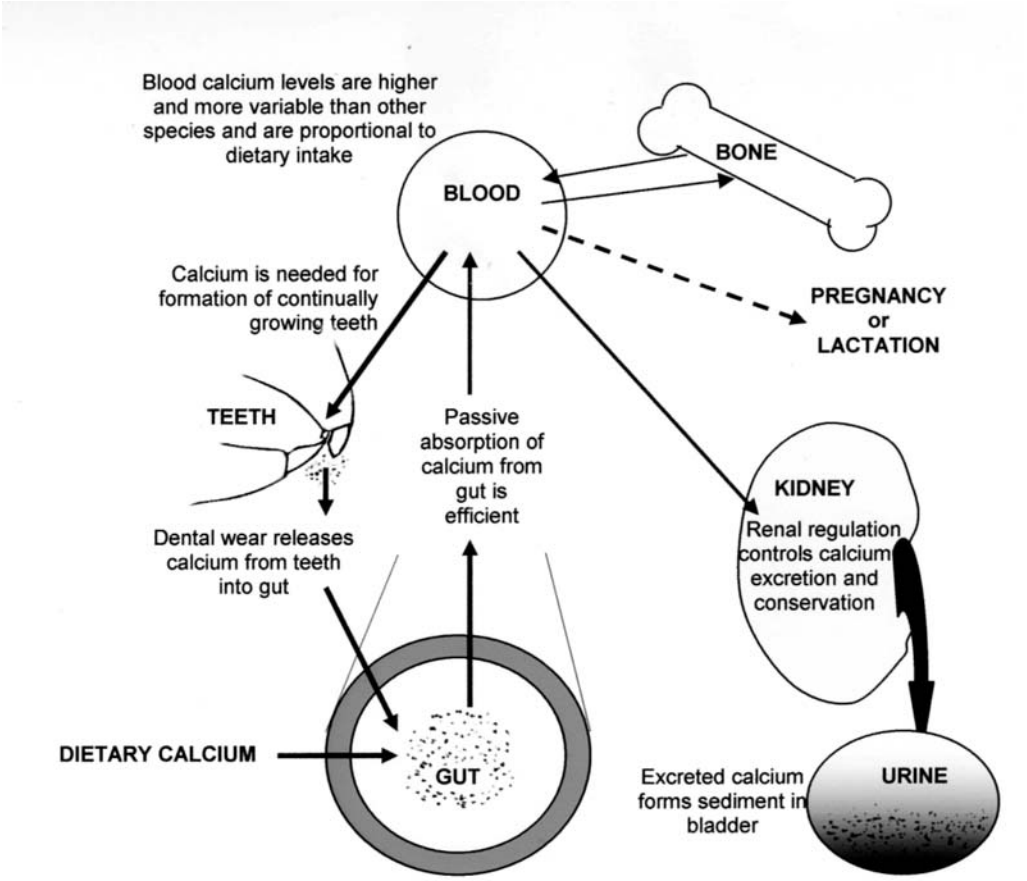

Section 1.6: The diet and husbandry of pet rabbits

The incidence of dental disease in pet rabbits has increased in recent years. This increase coincides with a change in the manner in which domestic rabbits are kept and fed. Prior to 1950, there were few compounded feeds for rabbits (Sandford, 1996).

Present day diets for pet rabbits

The following information has been gained from the author's experience of keeping and feeding pet rabbits and from details of diet and husbandry ascertained during rabbit consultations. Most of the published information on the nutrition of rabbits relates to farmed rabbits raised for their meat or fur, or to laboratory rabbits. These rabbits are shortlived and fed to grow rapidly and reproduce quickly. Their nutritional requirements are different from the pet rabbit that is not growing or reproducing and is expected to live for many years. Yet, most pet rabbits are fed on diets that are formulated according to the requirements of commercial rabbits. These diets are widely available in shops and supermarkets. They are cheap, clean and convenient and sold as 'rabbit food' with many claims about the benefits of the diet on the health of the rabbit that eats them. Many of these diets consist of a muesli type mixture composed of flaked or micronised peas and maize, rolled oats and extruded or cooked wheat (in the form of a coloured biscuit). Other ingredients, such as pieces of alfalfa or locust bean seeds, may be added to the mixture (Figure 63). To balance out any deficiencies of the basic ingredients, a supplement is added, but, to overcome the problem of a powder falling to the bottom of the bag, the supplement is often incorporated into grass pellets that are mixed with the ration. Many rabbits leave the pellets uneaten (Harcourt-Brown, 1996)

Owners are often discouraged from feeding vegetables to their rabbits. Breeders, pet shops and rabbit food manufacturers tell them that vegetables cause diarrhoea. This belief may be reinforced by a transient period of soft uneaten caecotrophs that can follow a change of diet. Owners are also discouraged from feeding fresh grass and garden weeds to their rabbits because they are told that plants may be poisonous or contaminated by chemicals. As a result many pet rabbits are fed on an *ad libitum* diet of mixed rations with little or no vegetables. Hay is usually available, although the quality and amount is variable. The manner is which pet rabbits are kept falls into three groups:

1. **Hutch rabbits:** The majority of pet rabbits live in hutches in the garden with or without access to an enclosed run. In the winter, the hutch is often moved indoors into garages, sheds, porches or other buildings.
2. **House rabbits:** A minority of owners keep their rabbits in the house as 'house rabbits'. This practice has increased rapidly over the last decade. Many house rabbits are given the free run of the house, others are confined in a cage for some of the time. Some house rabbits have access to a run. Others never go outside.
3. **Free range rabbits:** A few owners keep their rabbits in 'free range' conditions. These rabbits have are kept in some sort of outside enclosure where they can graze, browse and lie in the sun in conditions that are as close to living in the wild as possible. Some are brought into a building during the night, others stay outside. These rabbits live outside throughout the winter months with access to shelter.

© Frances Harcourt-Brown 2006

© Frances Harcourt-Brown 2006

CHAPTER 2: INVESTIGATION OF THE PROGRESSIVE SYNDROME OF ACQUIRED DENTAL DISEASE (PSADD) IN PET RABBITS

Section 2.1: Comparative study of morphological features of skulls of rabbits with and without dental disease

Materials and methods

Prepared skulls from 172 rabbits were collected over a seven year period from 1995 to 2002. These skulls were from 156 pet rabbits and 19 wild rabbits. The owners of the pet rabbits had consented to *post mortem* examination. The rabbits had died or were euthanased for a variety of reasons, including dental disease. Age at time of death, gender and breed of the rabbits were recorded.

Each case was categorised according to the author's grading system, which is based on the clinical history and clinical findings This grading system is described in Box 1.

Post mortem examination and skull preparation

Post mortem examination included examination of the internal organs, mouth, eyes and occlusal relationship of the teeth. The skulls were prepared by maceration, as described by the Natural History Museum. Maceration is not an exact procedure: the temperature and length of time for simmering and bleaching can vary with each specimen without affecting the appearance of the bone. Degreasing is not recommended as a routine part of the procedure. In this investigation, the head of the rabbit was removed and skinned prior to immersion in water and gently cooking for long enough for the soft tissue to be removed easily. After cooling, the soft tissues were removed from the bones under running water over a sieve to collect any teeth or bones that were dislodged during preparation. A toothbrush and a dental scaler were used to take off any soft tissue remnants that were adherent to the bone. The brain was removed by pulverising it with a skewer through the foramen magnum and flushing the tissue out under running water. After the soft tissue was removed, the skull was dropped into diluted hydrogen peroxide and brought back to the boil, then left for sufficient time for the bones to turn white. Then skull was drained and rinsed in cold water and placed in a warm place to dry.

© Frances Harcourt-Brown 2006

Morphological examination of the skulls

The comparative, morphological examination of the prepared skulls involved:

a: Complete skulls

b: Extracted teeth from some skulls that were dismembered.

Protocol for examination of the skulls

The skulls were inspected using a standard protocol with a skull from a mature wild rabbit for as a normal comparison. The following features were examined in detail:

1. **The exposed crowns of the teeth:** Pressure was applied to see if the teeth were loose and the alignment and structure of the exposed crowns was noted. The crowns of the cheek teeth were classified into one of four categories: straight, curved, misaligned or deformed. The enamel on the incisors was examined for the presence of horizontal ribs. If ribbing was present, evidence of symmetrical ribbing across both upper primary incisors was looked for
2. **The roots of the teeth:** These were examined by looking at the parts of the skull where tooth roots are situated. Bulging of the bone over the tooth root was evidence of root elongation. Loss of of bone and exposure of the apex of the root of the tooth was classified as root penetration. Raised calcified areas in which the roots were embedded in the surrounding bone were classified as 'calcified'.
3. **The occlusion of the incisors:** This was categorised according to the classification system illustrated in Figure 24.
4. **The colour and appearance of the bone:** This was classified as white, yellow or oily.
5. **The thickness of the bone:** The thickness of the bone was assessed in the cribriform area on the lateral aspect of the maxilla and in the overlying bone supporting the roots of the upper and lower primary incisors.
6. **The osteoporotic appearance of the bone:** The parietal bone had a spongy, osteoporotic appearance in some of the skulls so this feature was recorded. There was a hole in the ramus of the mandible near the angular process in some skulls but was absent in others. This feature was also recorded.
7. **The foramina**: These were examined for any abnormalities.
8. **The presence of abscesses**. A record was made of the teeth that were affected.

At the end of this examination a selection of representative hemimandibles and dismembered skulls of each grade was chosen for radiography with and without the cheek teeth *in situ*.

© Frances Harcourt-Brown 2006

Figure 24: Classification of Incisor Occlusion

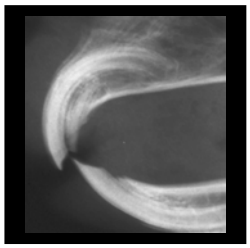

Class 1: Normal
The tip of the lower incisor rests against the upper peg tooth but is not in contact with the upper primary incisor

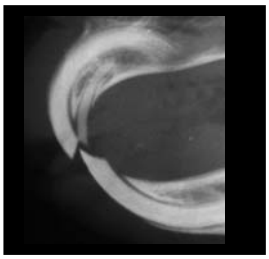

Class 2: Contact between primary incisors
The tip of the lower incisor rests against the upper primary incisor.

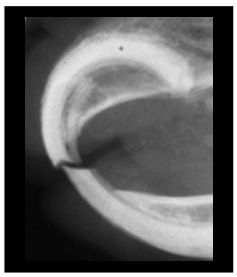

Class 3: Edge to edge contact
The occlusal surfaces of the upper primary incisor are in full contact with lower incisor

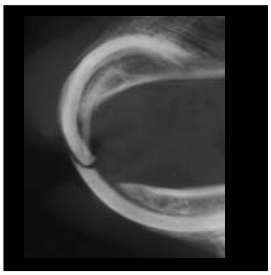

Class 4: Slight protusion of lower incisors
The anterior surface of the lower incisor is no longer in contact with the upper primary incisor

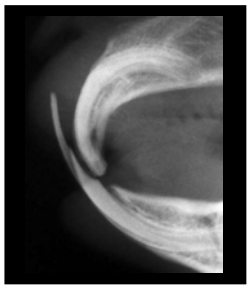

Class 5: Partial overgrowth of lower incisor
The occlusal surface of the lower incisor is in contact with the anterior surface of the upper first incisor

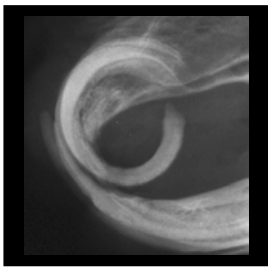

Class 6: Overgrowth of both upper and lower incisors
The upper incisors are still in contact with the lower incisors but are elongated and curled

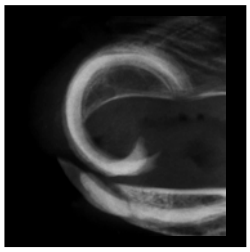

Class 7: Complete malocclusion
The upper and lower incisors not in contact

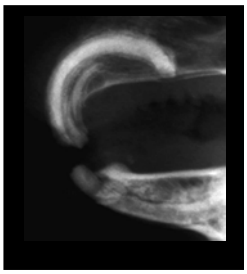

Class 8: Non occluding stumps
The crowns have broken off to leave stumps

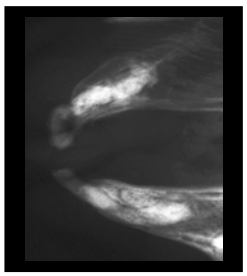

Class 9: Root resorption
There are only remnants of visible crowns



Unclassified: Incisors have been removed

Problems that were encountered during morphological examination of the skulls

1) Weights and measurements

At the outset of the study, the intention was to weigh and measure each skull and their components in order to compare the weight of the bone. However, the weight of a skull also includes the weight of the teeth, and in many of the specimens, the teeth were abnormal or even missing. This meant that the all the teeth would need to be removed from all the skulls for a valid comparison of weights. This proved difficult to do without damaging the bone and also affected the weight of the skull.

To make a comparison between skulls, a mathematical parameter was required that could be used as an index of skull size. Measurements of hemimandibles from eighteen wild rabbits were taken in an attempt to find such a parameter (Figure 25). But even within this well-defined group, there was such a variation in the shape of this bone (see Appendix 3), that it was impossible to derive a standard mathematical parameter. Therefore, the idea of removing teeth and weighing and measuring all the skulls was abandoned.

Figure 25: Measurement parameters of hemimandibles of wild rabbits

A: Length of mandible
B: Height of condyle
C: Width of mandibular body
D: Height of crown

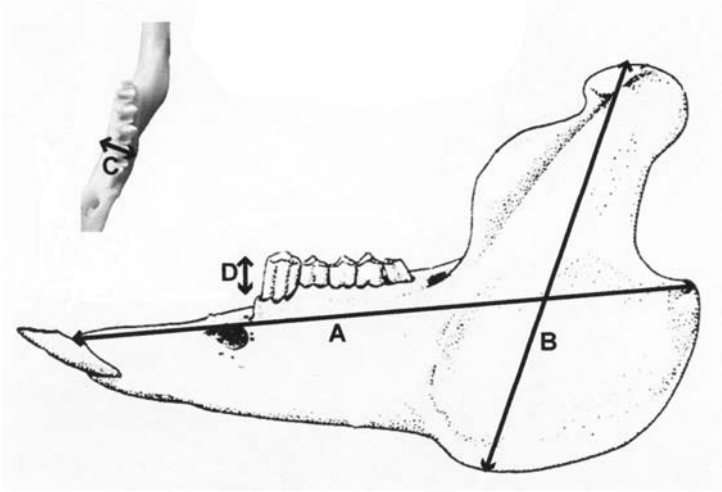

© Frances Harcourt-Brown 2006

2) Assessment of 'crown elongation'

At the outset of the study, the intention was to measure the length of the crowns of the teeth. This proved impossible because:

1. There were variations within the teeth in the same animal
2. In the skulls of rabbits affected by dental disease, the gingival bone was often eroded, which led to a lower gingival margin and an apparent increase in crown height.
3. Curvature of the teeth increased the length of the crown without altering the height.
4. Crown height was increased if the opposing teeth were short and vice versa

Figure 26: Difficulties associated w

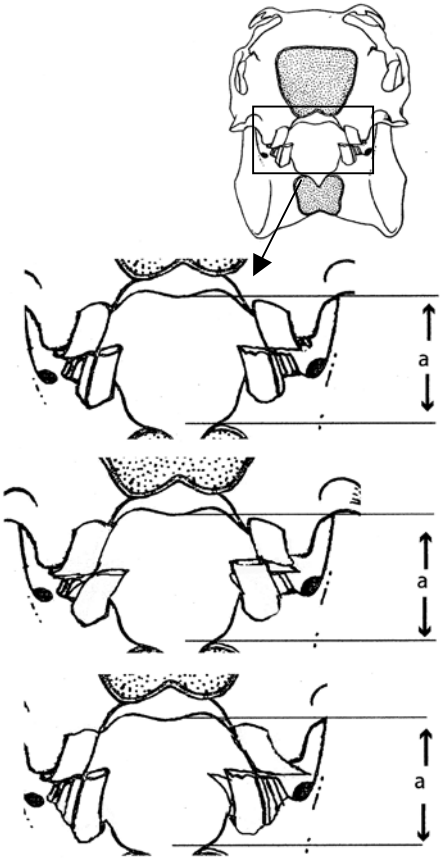

Normal occlusion of cheek teeth *(From Ardran and Kemp (1958), (Reproduced with permission from Zoological Society of London)*

Examples of alterations in crown length but not height. *Modified from above drawing by Ardran and Kemp (1958)*:

1) Normal height

2) Increased curvature of teeth or short crowns opposed by long ones can make crowns look long.

3) Erosion of gingival bone and tipping of teeth, so crowns look long

This photograph of the lower cheek teeth of a rabbit illustrates the problem of measuring the length of the crowns. Some crowns were long and others short in the same animal. The opposing tooth of a long tooth was short and *vice versa.*

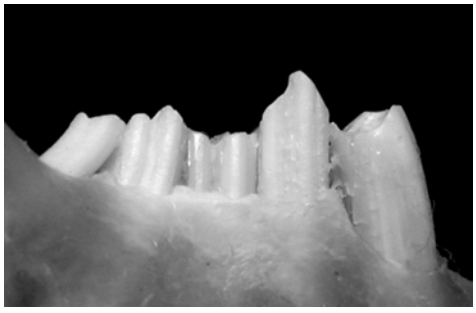

Because of these problems, measurement of crown length or height was abandoned as part of the morphological examination of the skulls.

© Frances Harcourt-Brown 2006

Morphological examination of teeth

After the skulls were examined, the teeth were removed from a selection of representative skulls of each grade. The decision to remove teeth was based on the quality of the skull and whether it should be preserved complete. Teeth were removed from those skulls that were already incomplete or were not well preserved.

© Frances Harcourt-Brown 2006

Section 2.2: Comparative study of radiological features of skulls of rabbits with and without dental disease

Materials and methods

A Philips Practix X-ray machine with fixed 20mA, but variable Kv and time, was used for the radiological studies. A cassette containing fine screens suitable for extremities in humans (Trimax T2) contained the film (Fuji HRE). The radiographs were developed, fixed and dried in a Fuji HR automatic processor.

The comparative study of the radiological features of skulls and of rabbits with and without dental disease looked at:

1. Examples of dismembered skulls from each grade
2. Teeth that were removed from dismembered skulls of each grade
3. Radiographs of the heads of wild rabbits and pet rabbits that were presented for treatment

1). Radiographic study of dismembered skulls

Examples of skulls and hemimandibles from each grade were radiographed before and after removal of the teeth. An exposure of 55Kv and 4 mAS was using for dorsoventral views of the skull. Hemimandibles were radiographed at 50Kv and 4 mAS.

2). Radiographic study of the teeth that were removed from dismembered skulls

The extracted teeth from skulls of each grade were arranged on adhesive transparent film so the teeth could be lifted on an off the cassette easily and individual teeth were identifiable. An exposure of 45kv and 4mA was used for taking radiographs of the teeth.

3). Study of radiographs of the heads of pet rabbits that were presented for veterinary treatment

Radiographs of the heads of 315 rabbits were studied. These radiographs were collected from 1995 to 2002 and included:

1. **Radiographs of clinical cases:** Indications for skull radiography included abscesses, neoplasia, trauma, dacryocystitis, malocclusion, rhinitis and vestibular disease
2. **Radiographs of dead rabbits**: These had died or were euthanased for a variety of reasons.
3. **Radiographs of rabbits that were anaesthetised for neutering**: These radiographs while the rabbit was anaesthetised and were taken with the owner's informed consent.

A lateral or almost lateral view was taken of the skulls of all 315 rabbits in this study. An additional dorsoventral view was taken in 230 cases. A standard exposure of 55kv and 4mAS was used for the lateral view and 60kv and 4mAS for the dorsoventral view. Oblique and rostrocaudal views were taken in some cases but are not included in this study.

© Frances Harcourt-Brown 2006

Examination of skull radiographs

Based on the clinical history and findings of the clinical examination, each set of radiographs was assigned to a grade using the standard grading system (Box 1 and Appendix 1). A methodical approach to interpretation was adopted for examination of radiographs. The accuracy of positioning was assessed by looking evidence of tilting of the skull, such as two outlines of the zygomatic prominence or two outlines of the ventral border of the mandible, on the lateral view and for right and left symmetry of the structures on the dorsoventral view. The radiographs were examined on a viewer in a darkened room.

On the **lateral view,** the shape of the head was looked at in conjunction with the rabbits breed. Attention was paid to the occlusal relationship of the upper and lower teeth and the lines of the hard palate and rostral mandible.

The following radiographic features were examined and recorded in detail using a lateral view skull radiograph of a clinically healthy rabbit for comparison (Figure 27):

a) Shape, structure and occlusion of incisors: The enamel on the incisors was examined for evidence of ribbing and the roots examined for elongation and/or dystrophic calcification. The pulp cavity was assessed and classified as 'closed' or 'not closed'.

b) Occlusal line of the cheek teeth: This was classified as

- Zigzag (normal)
- Uneven occlusal line
- Visible spurs
- Uneven occlusal line with short, deformed crowns
- Deformed radiodense crowns

c) Shape and structure of the crowns of the cheek teeth: The length of the crowns of the cheek teeth was assessed but with the same problems as assessing crown length in the prepared skulls i.e. curvature and unevenness of the teeth. The mesial surface of the premolars was a good site to detect abnormalities so the shape and structure of this surface was examined for erosions, spurs, lost crowns, deformities or other abnormalities.

d) Roots of the cheek teeth: The following abnormalities were recorded:

- Loss of radiodense longitudinal line of the enamel fold.
- Elongated roots
- Blurring of the structure of the roots and surrounding bone
- Deformed, misshapen roots
- Dystrophic calcification and increased radiodensity of embedded roots and surrounding bone
- Resorbed roots

e) Alveolar bulla: The alveolar bulla was examined looking for a clear line of bone overlying the apices of the roots of the teeth or for obvious root elongation and penetration of the alveolar bone. This examination was sometimes inconclusive because of superimposition. Dystrophic calcification and increased radiodensity of embedded roots and the surrounding bone was seen in some cases.

f) Apex of root of lower fourth cheek tooth: Previous examination of the prepared skulls had shown that the bone surrounding the apex of the root of the second lower molar is very thin and easily penetrated by elongated roots. Therefore, special attention was paid to this area on the lateral skull radiographs and any increase in lucency was noted.

g) Radiographic evidence of osteopaenia: Bone loss was assessed by looking at the thickness of the cortical lines, especially those of the hard palate and the ventral mandible. Generalised radiodensity of the bone was assessed on the rami of the mandibular condyles.

h) Abscesses: The radiographs were examined for areas of osteolytic bone and abscesses. Which tooth or teeth that were associated with abscessation was noted.

© Frances Harcourt-Brown 2006

Figure 27:
Radiographic features of a normal rabbit skull: lateral view

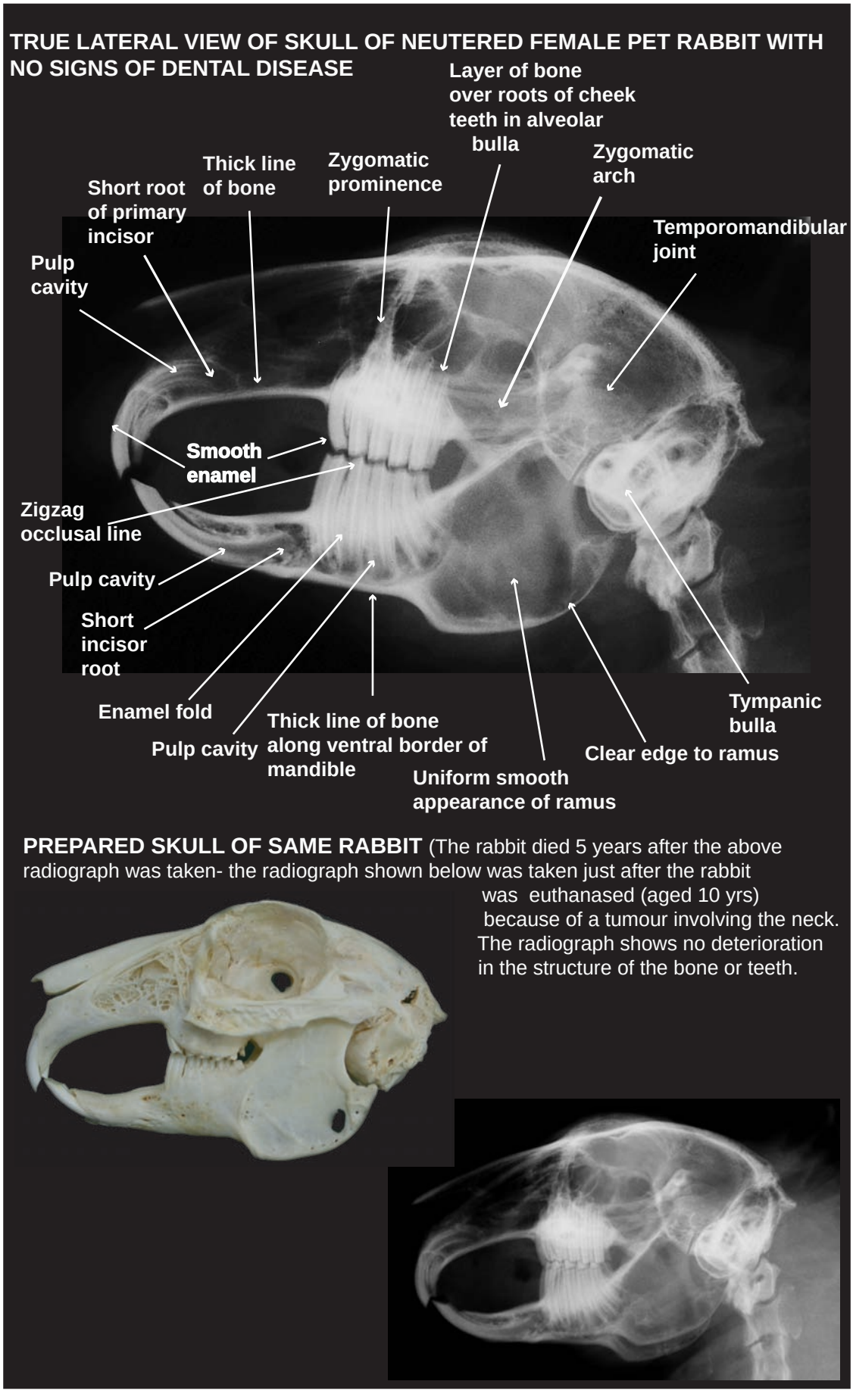

On the **dorsoventral view, t**he following features were noted:

a) First upper premolars. This view provided a site where the *lamina dura* could be assessed without superimposition. In rabbits with normal dentition, the internal structure of the tooth could also be seen. This view also showed changes in the upper premolar tooth roots such as elongation, penetration of the bone, deformity or dystrophic calcification and increased radiodensity of embedded roots and the surrounding bone

b) Loss of contrast. Radiodensity of the bone was assessed by looking at the structure of the bone of the zygomatic arch and comparing it with a dorsoventral view of the skull of a wild rabbit.

c) Abscesses. The radiographs were examined for areas of osteolytic bone and abscesses. Which tooth or teeth that were associated with abscessation was noted.

The radiographic features of the dorsoventral view of a skull of a clinically normal pet rabbit are shown in Figure 28 opposite.

© Frances Harcourt-Brown 2006

Figure 28:
Radiological features of the dorsoventral view of the skull of a clinically healthy (Grade 1) rabbit.

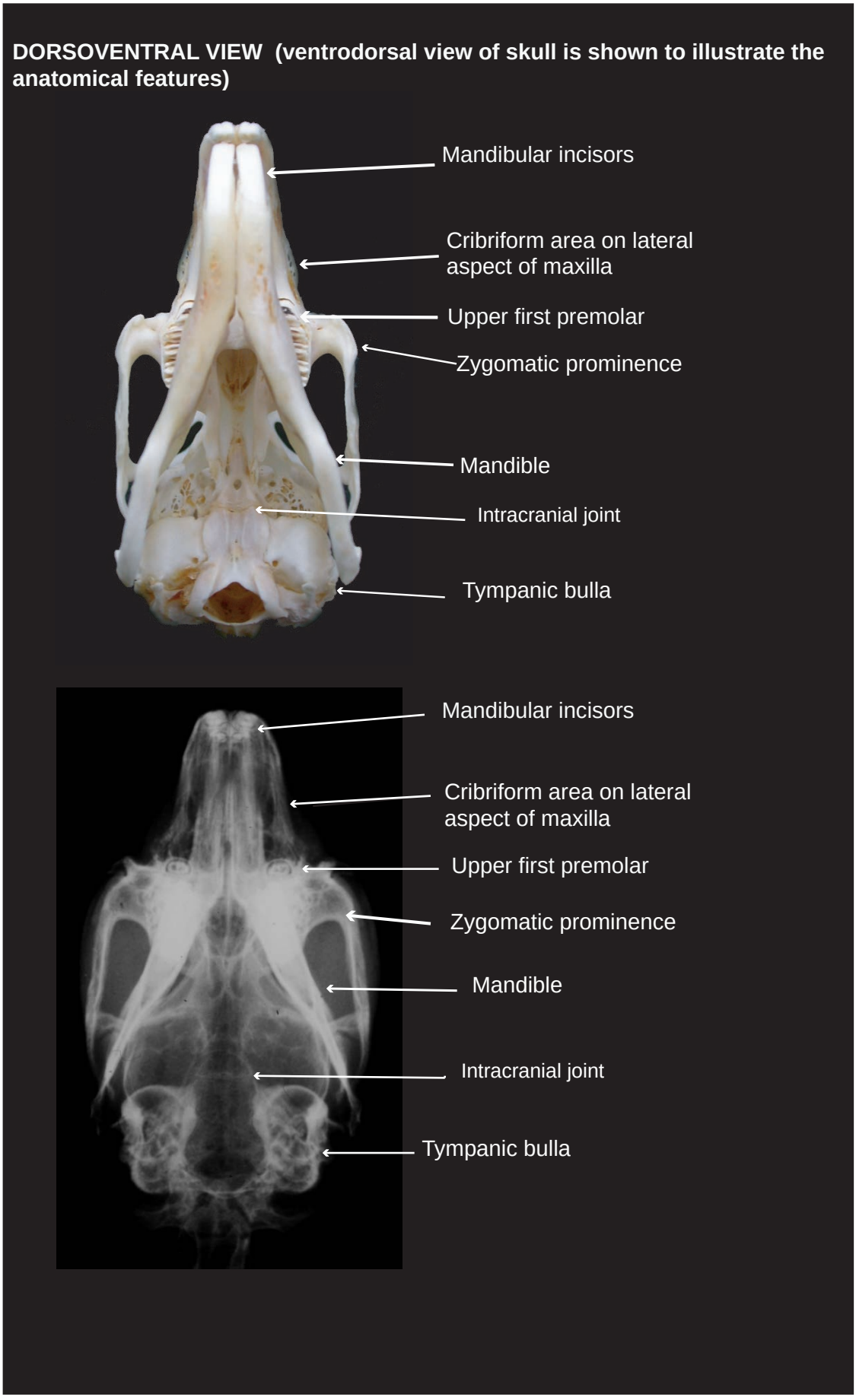

Section 2.3: Comparative study of the vertebral column of rabbits with and without dental disease

Whole rabbit radiography is a common investigative procedure in the author's practice so lateral views of the vertebral column were available of some of the rabbits whose skull radiographs were included the study. These radiographs were examined for differences in the appearance of the lumbar vertebrae. The lumbar vertebrae were chosen as a site for comparison as it the place that shows most bone mineral density loss in laboratory investigations (Gilsanz and others, 1991).

© Frances Harcourt-Brown 2006

Section 2.4: Data analysis of rabbits presented for veterinary treatment

Data collection

Computer records of 1245 rabbits presented for veterinary treatment between 1998 and 2002 were examined. Of these, 465 required dental treatment. The remainder were presented for neutering, vaccination, neoplasia, digestive problems, respiratory tract problems or other conditions unrelated to poor dentition. Gender and breed of rabbit was recorded. Age data was excluded from the statistical analysis because it was considered unreliable. An exact age was unknown in many cases and it was difficult to know the age at which dental problems had begun.

Although the gender of the rabbit recorded accurately, breed details were not reliable. Rabbit breeds were a source of confusion for both owners and the veterinary staff who entered the details on the computer. Some rabbits were classified by coat texture or colour e.g. Angora, Chinchilla or Satin. Breeds such as Rex, Netherland Dwarf, Dutch, English or New Zealand White were easy to recognise from their colour, markings, size and head shape, so data relating to these rabbits was reliable. Lop-eared rabbits were classified as Dwarf Lop if they weighed over 1.5kg and Minilop if they weighed less. Larger lop-eared rabbits (> 4.5kg) were easily identifiable as French or English Lops from the length of the ears. Other giant rabbits (> 4.5kg) were identifiable as a breed such as English Giant, Vienna Blue, Beveran or Chinchilla Gigantica. But rabbits with no recognisable characteristics of any particular breed were classified as 'mixed'. This group included rabbits of any uniform colour that had upright ears and could easily have included some pedigree rabbits from obscure breeds.

Statistical analysis

Data from the 1254 rabbits were subdivided into rabbits that required dental treatment (465) and those that did not (789). The Chi Square test was used to compare the gender and breed of the two groups.

© Frances Harcourt-Brown 2006

Section 2.5:
Examination of the collection of rabbit skulls at the Natural History Museum in London.

In August 2004, the author visited the Natural History Museum in London to examine their collection of skulls of the European rabbit (*Oryctolagus cuniculus).* This large collection contains skulls from different parts of the world that have been collected over the last 150 years or so. It even contains some skulls collected and prepared by Charles Darwin.

A number of methods were used to prepare the skulls that are held at the Natural History Museum. Some skulls were from decomposed wild rabbits. Weathered bones had been picked up and submitted to the museum. Other skulls were from rabbits that were submitted whole and prepared at the museum. The skins from these rabbits were also held in the collection, so preparation by the Museum could be deduced from the presence of both skin and skull in the collection. Sometimes the skulls were submitted from private collectors who had prepared the specimens themselves but the method of skull preparation was not included in the provenance. These skulls could have been buried and dug up, prepared by carnivorous beetles (*Dermestid* spp.), macerated or stewed. There may or may not have been additional chemical treatment with hydrogen peroxide or sodium perborate.

In total, 317 skulls from wild rabbits and 20 from domesticated rabbits were examined. Details of age of the animal at the time of death or even the sex of the animal were seldom available. Some skulls from wild rabbits were incomplete but they were all checked for abnormalities of the teeth or of the bones of the skull. A detailed examination was conducted of 100 complete skulls from wild rabbits. The following features were looked for:

1. **The exposed crowns of the teeth** were examined for evidence of abnormality such as curvature, misalignment or defects such as horizontal ribs on the upper first incisors.
2. **The roots of the teeth** were examined by looking at the parts of the skull where tooth roots are situated.
3. **Whether the skull could be positioned with both the cheek teeth and incisors in occlusion** was noted. A note was also made of whether the skin from the rabbit was also held in the collection, in which case the skull had been prepared by the museum so the teeth would have been removed and glued back in place. The presence of glue in other specimens was recorded.
4. **The colour and appearance of the bone** was assessed..
5. **The osteoporotic appearance of the parietal bone** was assessed and recorded.
6. **The foramina** were examined for any abnormalities.

© Frances Harcourt-Brown 2006

Section 2.6: Other investigations

Bone Ash Analysis

At the outset of the study, hemimandibles were collected during *post mortem* examination and submitted to the local Veterinary Investigation Centre for bone ash analysis. Eventually, it was realised that the size and structure of the teeth would affect these results so femurs were submitted instead. This was changed to the first cervical vertebra (axis) after reading the results of a German thesis (Conrad, 1997) that indicated that bone mineral density of vertebrae was preferable to femurs because the weight and activity of the rabbit had less effect. Unfortunately, at this time, the policy of the VI Centre changed and they ceased to accept submissions from domestic pets so this part of the investigation was abandoned before a statistically significant number of samples were collected. The results that were collected are presented in Appendix 3.

Histopathology

Several skulls were submitted for histological examination to a total of four histopathologists, including an expert in human metabolic bone disease. Unfortunately, all the histopathologists experienced difficulties in preparing sections due to the hard, brittle nature of the teeth and the risk to their microtome. Interpretation of decalcified specimens proved difficult because of the nature of the changes that were taking place and the pathologist's unfamiliarity with rabbit dentition.

© Frances Harcourt-Brown 2006

© Frances Harcourt-Brown 2006

CHAPTER 3: RESULTS

Section 3.1: Results of morphological study of skulls of rabbits with and without dental disease

Age, gender and breed of pet rabbits from which the skulls were prepared

The age at death of the rabbits from which the skulls were prepared was recorded and is presented in Graph 1. The raw data can be found in Appendix 3. From the graph, it can be seen that 75% of the rabbits with dental disease were less than four years old when they died.

Graph 1: Age distribution of rabbits with and without dental disease from which skulls were prepared (excluding wild rabbits)

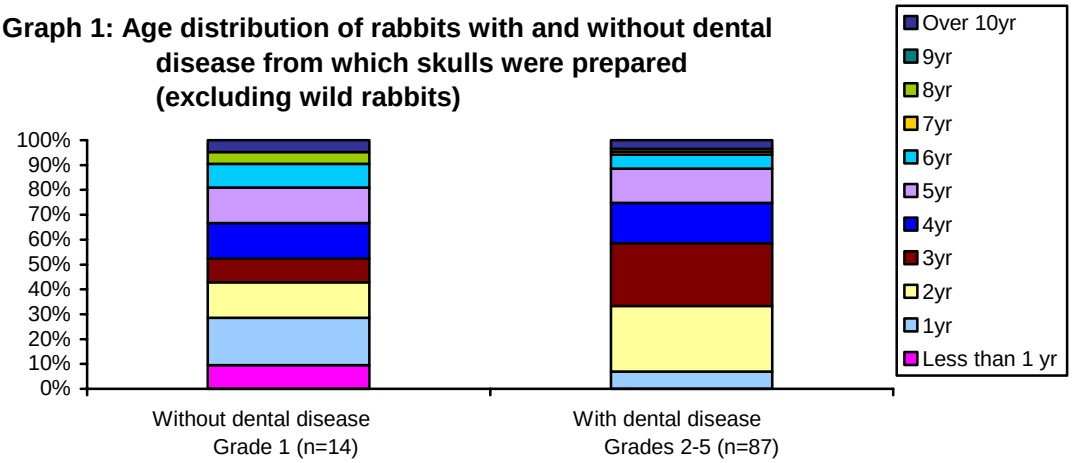

Graph 2 shows the gender of the rabbits from which the skulls were prepared. Less than 45% of the rabbits without dental disease were male in comparison with 63% of the rabbits that showed signs of dental disease.

Graph 2: Gender distribution of rabbits from which skulls were prepared (excluding wild rabbits)

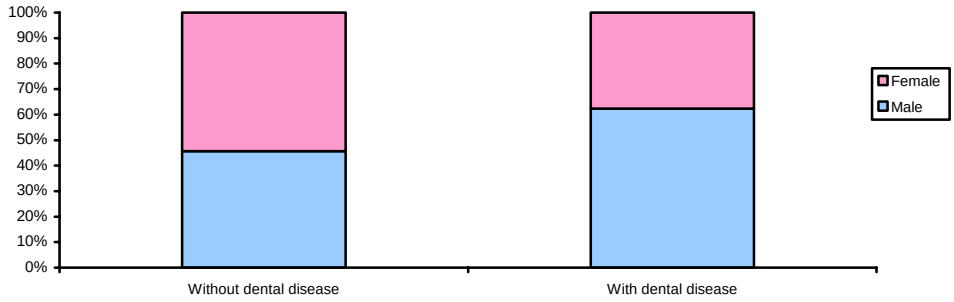

The skulls were prepared from a range of breeds. Further classification of the breeds into breeds into Dwarf (Dwarf Lop and Netherland Dwarf) and non-Dwarf Breeds showed an equal distribution both in rabbits with and without dental disease (Box 4)

Box 4 : Comparison of Dwarf breeds with non Dwarf breeds of rabbits with and without dental disease from which skulls were prepared

	Without dental disease	With dental disease
Dwarf breeds	17	43
Non Dwarf breeds	17	43

© Frances Harcourt-Brown 2006

Raw data relating to detailed examination of prepared skulls can be found in Appendix 3

1. Changes in the exposed crowns of the cheek teeth

The results of examination of the exposed crowns of the cheek teeth are shown in Graph 1. Examples of the changes are illustrated in Figure 29.

Graph 3: Comparative changes in the exposed crowns of the cheek teeth in rabbits of different grades

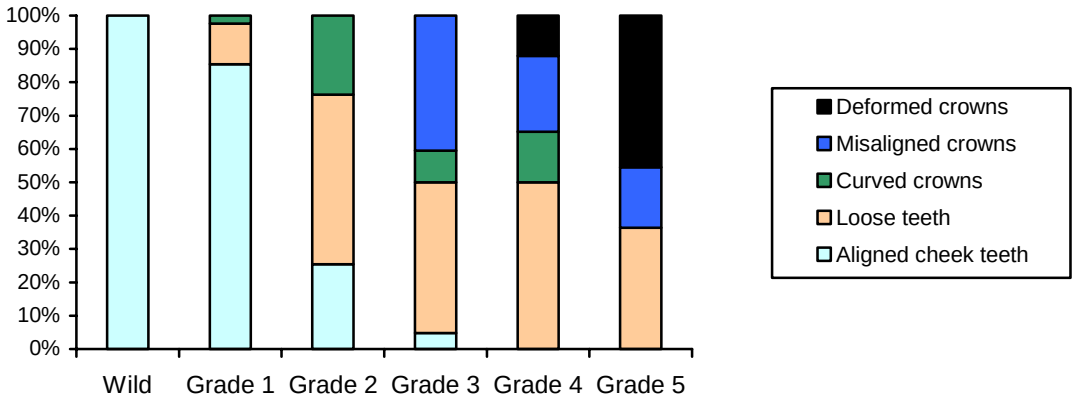

There were visible enamel defects on many of the exposed crowns of the teeth. The most obvious were horizontal ribs across the enamel of the upper primary incisors (Graph 2, Figure 29). Horizontal ribs were not observed on the incisors of the Grade 5 skulls because the exposed crowns of these teeth were short and deformed or absent altogether.

Graph 4: Ribbing of incisors in skulls of rabbits of different grades

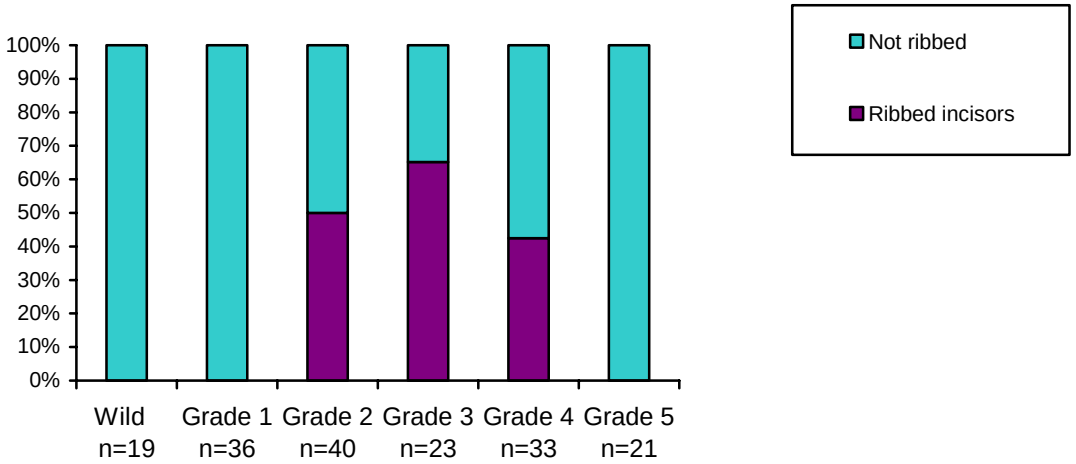

© Frances Harcourt-Brown 2006

Figure 29:
Examples of morphological changes in the exposed crowns of the teeth

INCISORS:
NORMAL

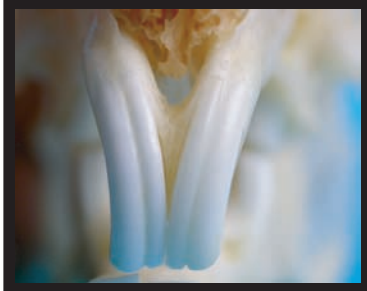

Horizontal ribs across the labial surface of the incisors was a feature that was looked for on prepared skulls. Assymetry of the changes would suggest that disruption in enamel formation was not due to episodic insults, such as infection.

RIBBED

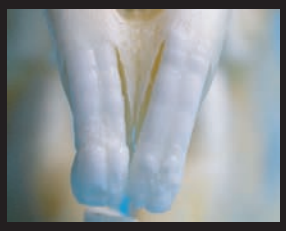


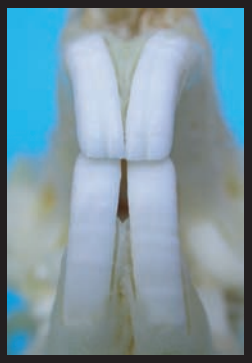

CHEEK TEETH- SHAPE, ALIGNMENT AND STRUCTURE OF CROWNS

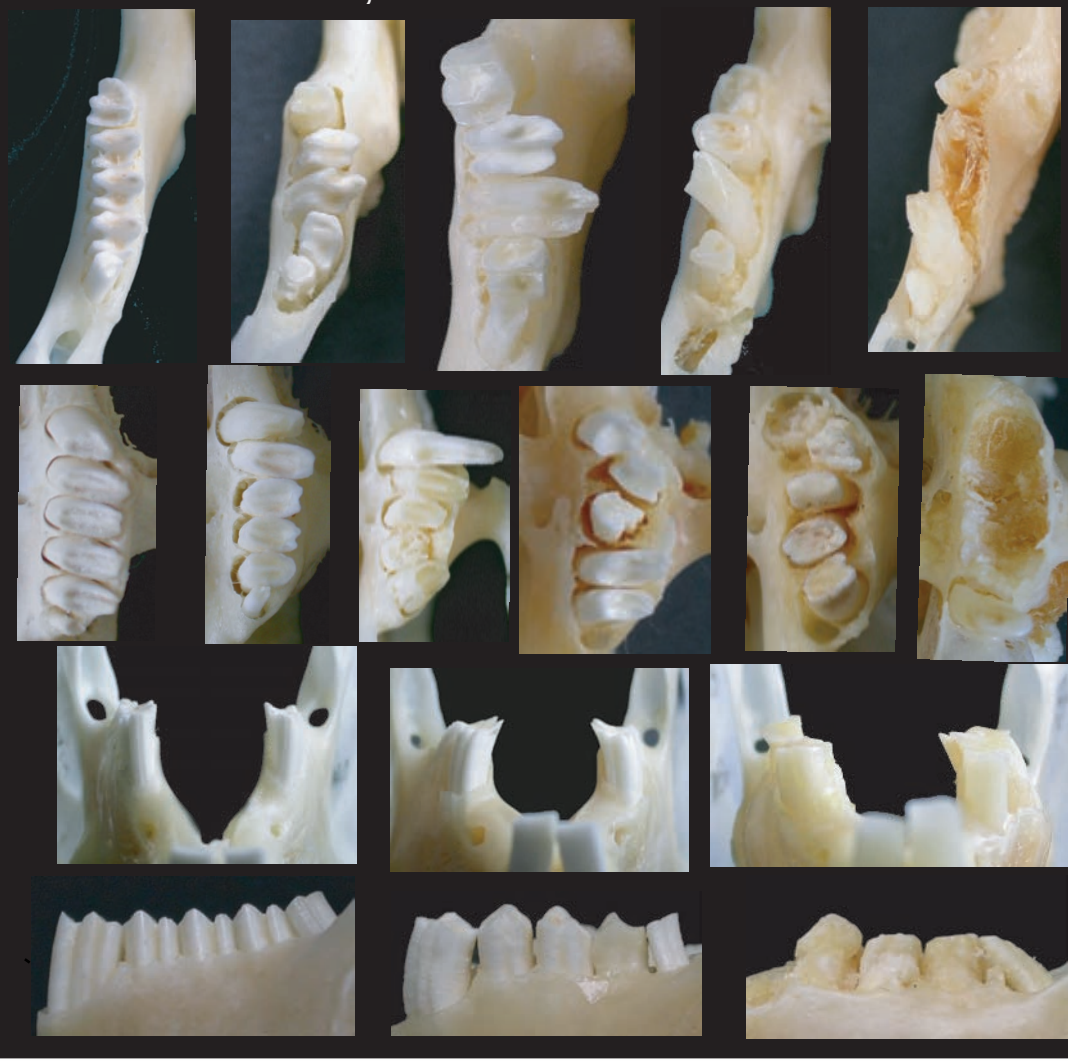

2. Changes in the roots of the teeth

Examination of the skulls gave limited information about the roots because they could not be visualised. Instead, the parts of the skull overlying the apices of the roots were examined for signs of root elongation, penetration of the bone by elongated roots or roots that showed dystrophic calcification of the teeth and surrounding bone. The results showed that dystrophic calcification occurred after other changes had taken place in the teeth. It was a feature of Grade 4 and Grade 5 skulls. The incidence of root elongation reduced in Grade 4 and Grade 5 skulls because the elongated roots had penetrated the bone and were therefore classified as 'penetration' or 'dystrophic calcification' (Figure 30).

Graph 5: Changes to the apices of the tooth roots in skulls of different grades

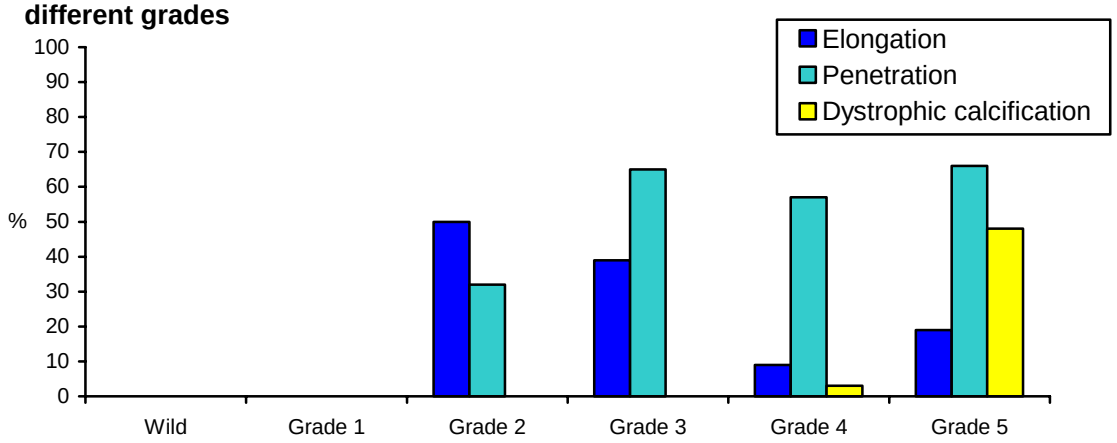

Changes were seen in all the teeth (except the upper second incisors that were not examined). Graph 6 shows the changes in individual teeth.

Graph 6: Incidence of changes in individual teeth

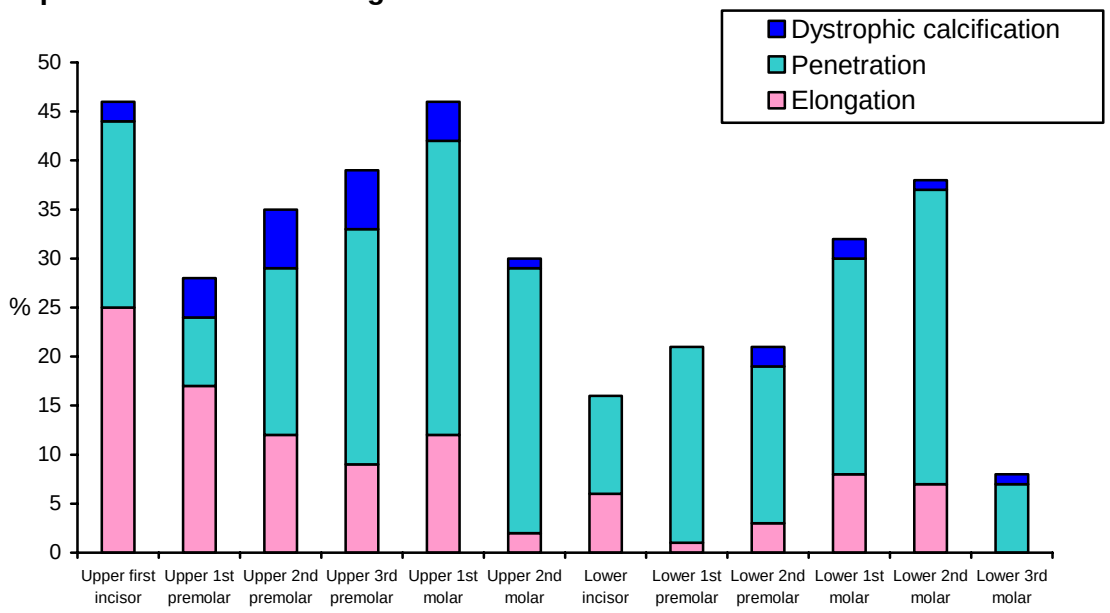

© Frances Harcourt-Brown 2006

Figure 30:
Examples of morphological changes in apices of roots of the teeth in prepared skulls of pet rabbits

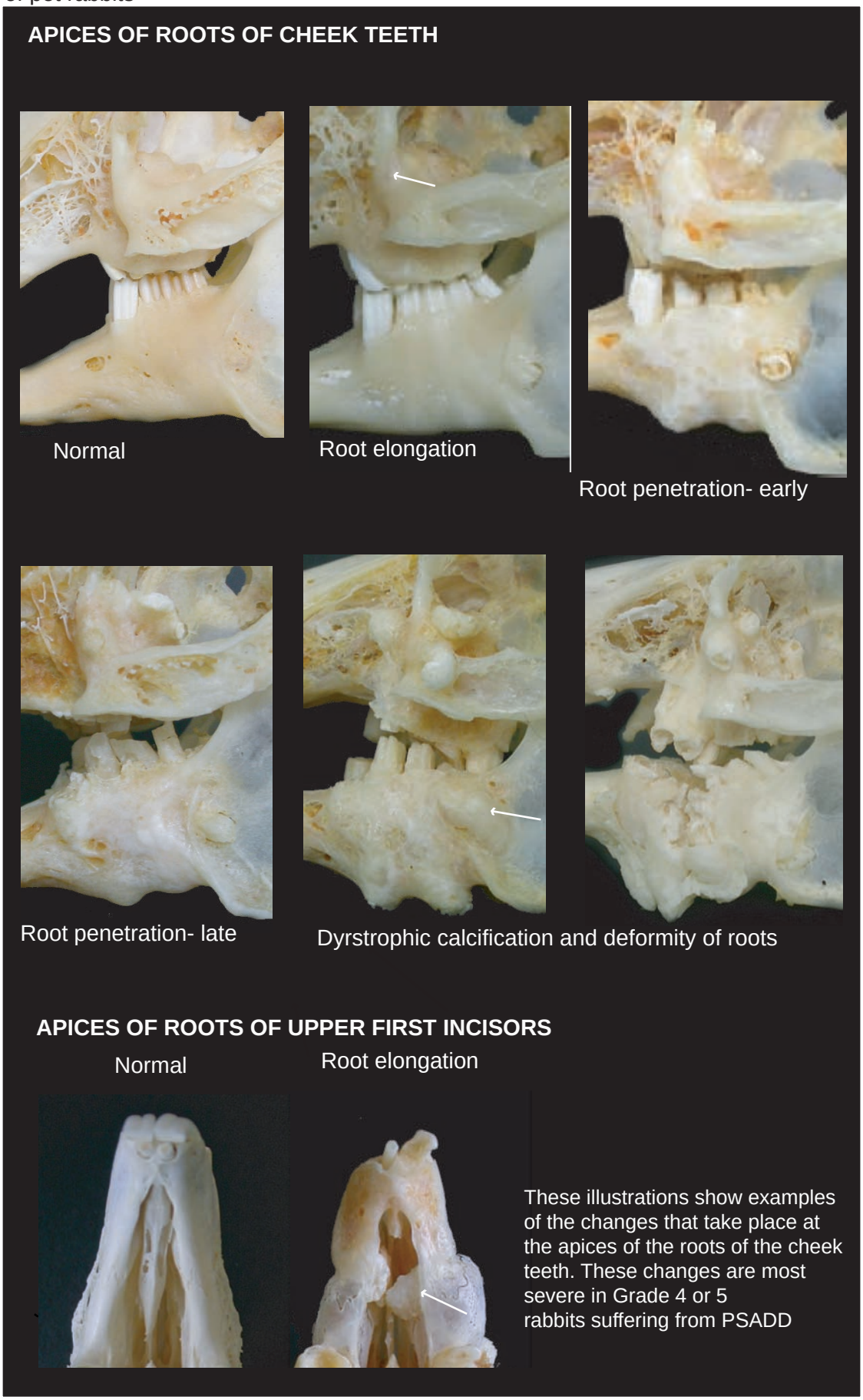

3. Incisor occlusion

There was a progressive change in the occlusion of the incisors between different grades of rabbits (Graph 7). All the skulls from Grade 1 rabbits showed normal occlusion with the tips lower incisors resting against the peg teeth. The nature of the abnormalities increased in severity and occurrence in each Grade. Examples are shown in Figure 31. In the skulls showing evidence of dental disease (Grade 2-5), there were more rabbits with abnormal occlusion. More Grade 4 or 5 rabbits showed absent crowns and non-growing stumps.

Graph 7: Class of incisor occlusion of in skulls of rabbits of different grades

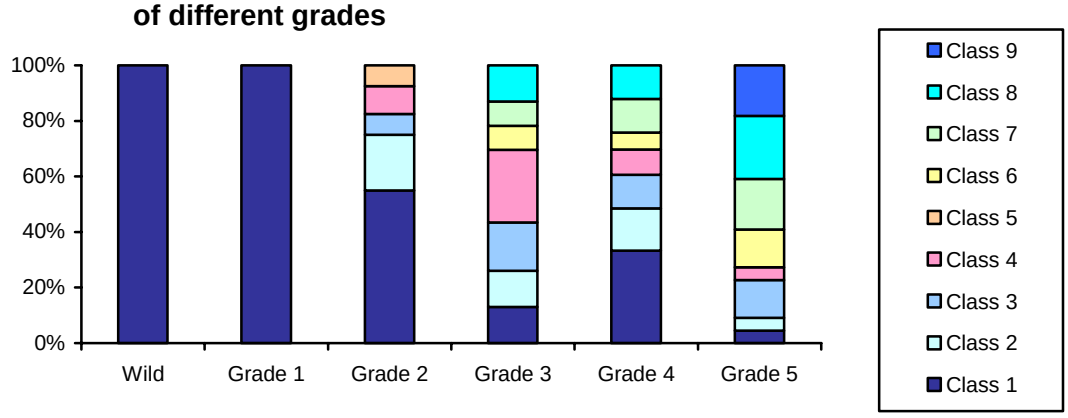

4. Colour and appearance of bone

The colour of the skulls was variable. Seventeen out of the 19 wild rabbit skulls had a smooth white appearance. The remaining two were slightly yellow. Yellow bone was a feature of many of the pet rabbit skulls. So was translucency. Some skulls had an oily appearance that highlighted the translucency of the skulls with thin bone. It was difficult to define a degree of 'yellowness', 'oiliness' or translucency. More rabbits with dental disease, especially those with advanced changes (Grade 4 and 5) had yellow, oily or translucent bones (Graph 8). Three skulls were heavy when picked up and had a dense chalky white appearance (Figure 31). These three rabbits were known to be in chronic renal failure.

Graph 8: Appearance of bone of skulls of rabbits of different grades of dental disease

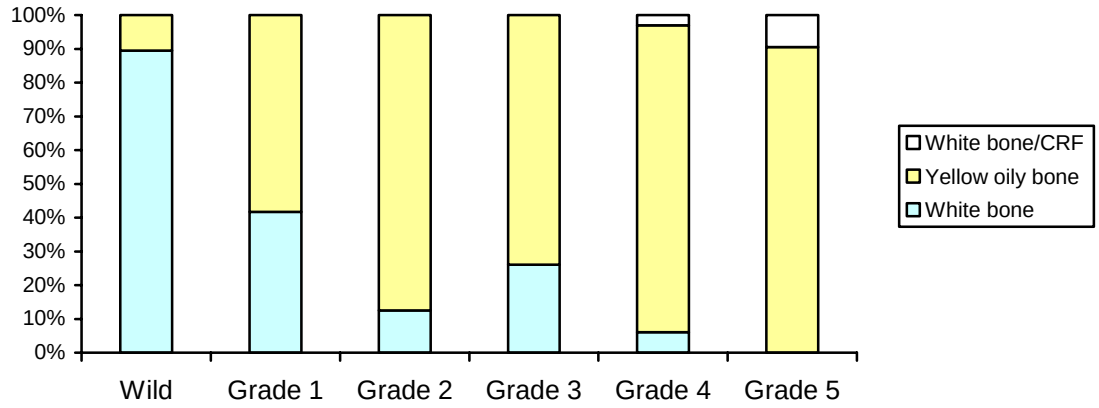

© Frances Harcourt-Brown 2006

Figure 31: Examples of grades of incisor occlusion and appearance of bone of prepared skulls from pet rabbits

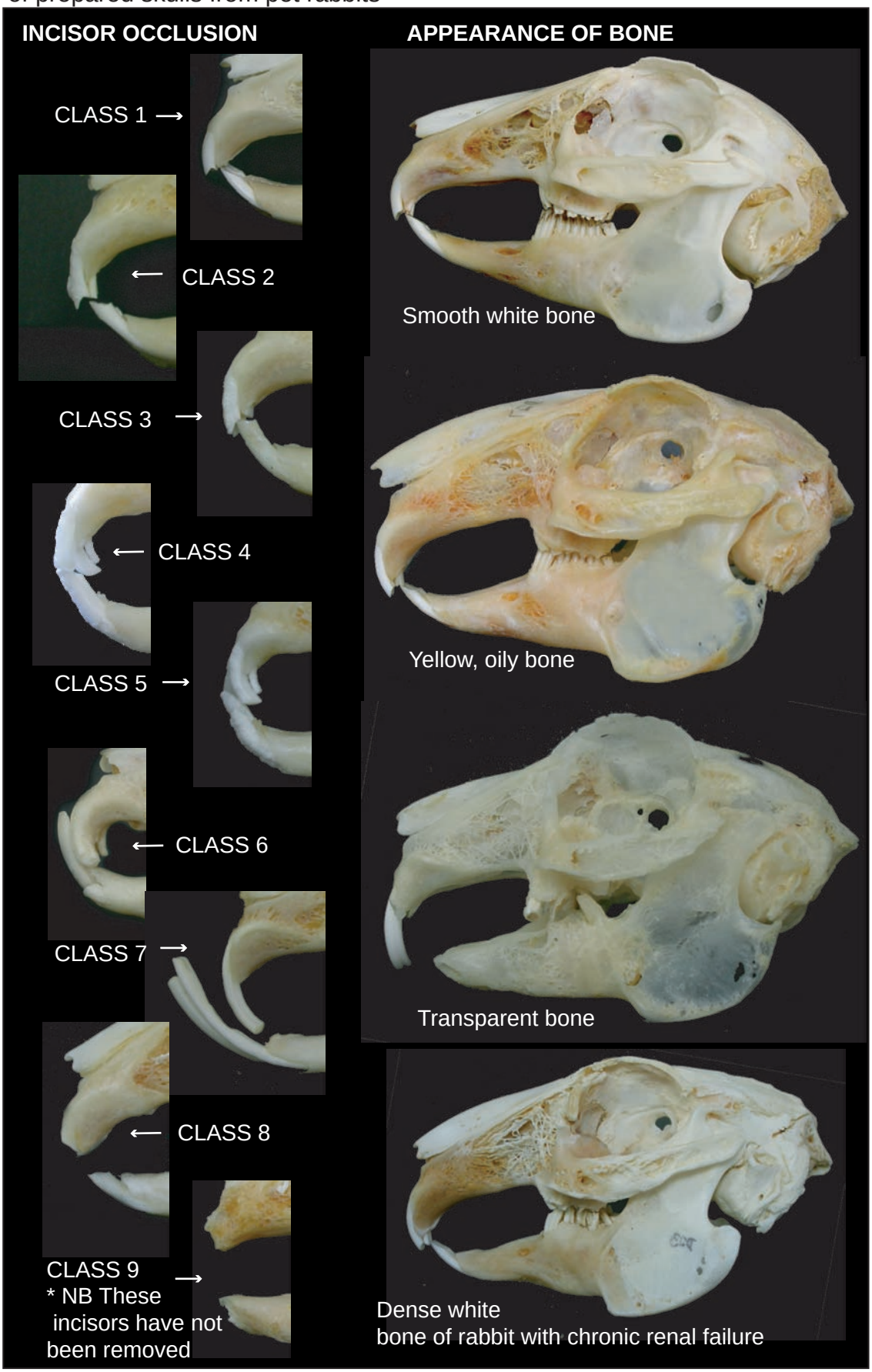

5. Thickness of the bone

The parts of the skull that showed bone loss most obviously were the bone supporting the incisor roots, the incisive bone and the ramus of the mandible. Thin bone was also evident in the area of cribriform bone that forms the lateral aspect of the maxilla . This showed thin strands of bone in comparison with the same area of the skulls of the wild rabbits.

The bony canal that contains the nasolacrimal duct was evident as a dilated structure in many of the skulls of rabbits suffering from dental disease (Graph 9 and Figure 32)

Graph 9: Changes in structure and thickness of bone of skulls of rabbits of different grades of dental disease

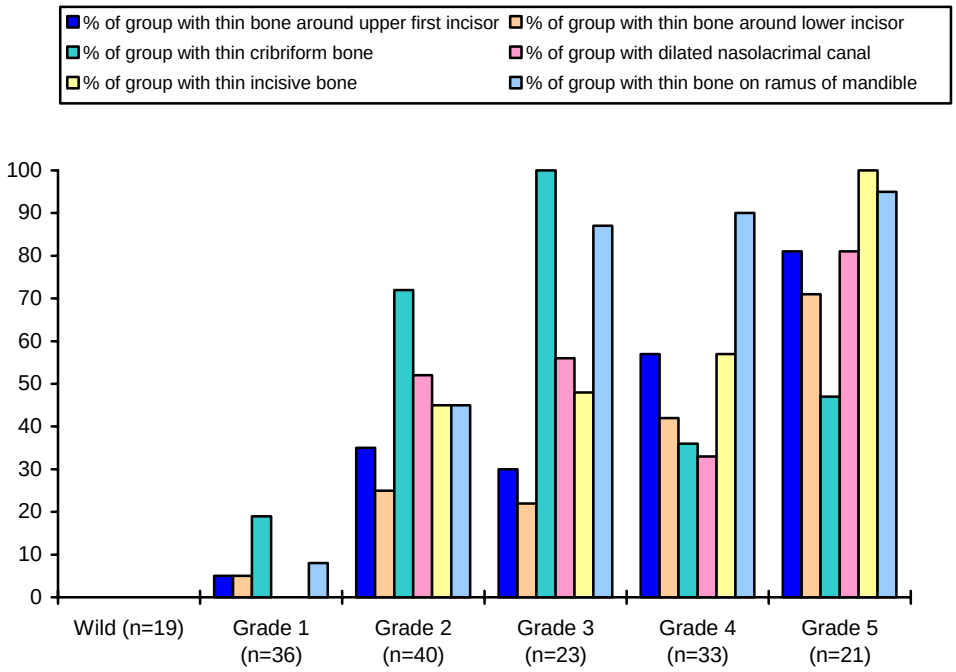

The graph shows that there was evidence of bone loss in the majority of the skulls from pet rabbits. Only the wild rabbits showed no evidence of thin bone. The degree of bone loss was greater in rabbits with dental disease, indicating a relationship between the bone loss and advancing dental disease.

© Frances Harcourt-Brown 2006

Figure 32:
Assessment of the thickness of the bone of prepared skulls of pet rabbits

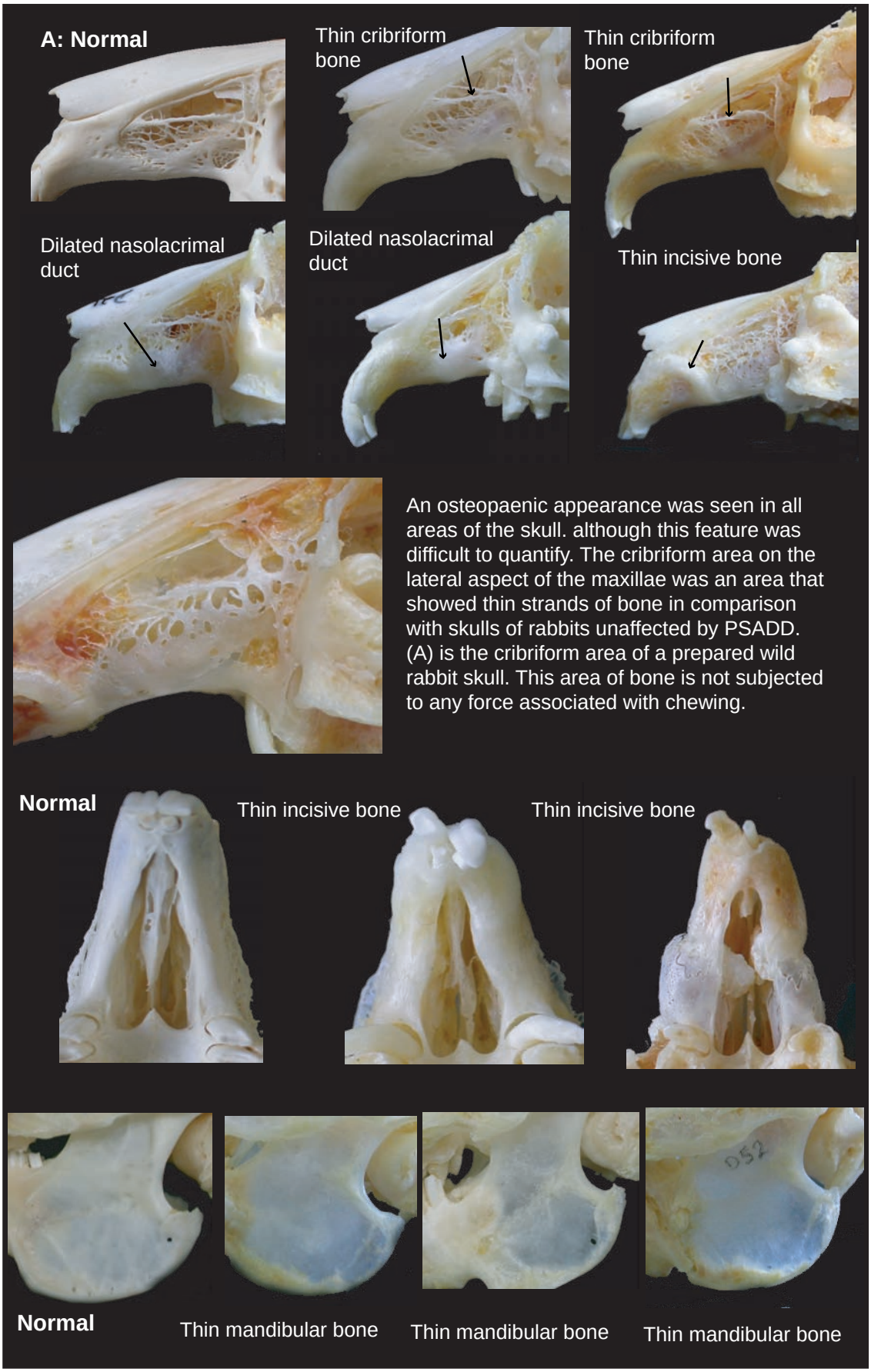

6. The osteoporotic appearance of the bone

Approximately one third of the skulls of pet rabbits in each grade showed a spongy, osteoporotic appearance of the parietal bone. It did not appear to be a significant feature. Neither was a foramen in the mandibular ramus although a smaller percentage of skulls from pet rabbits than wild rabbits showed this feature (Graph 1, Figure 33)

Graph 10: Porous appearance and presence of foramen near angular process of mandible

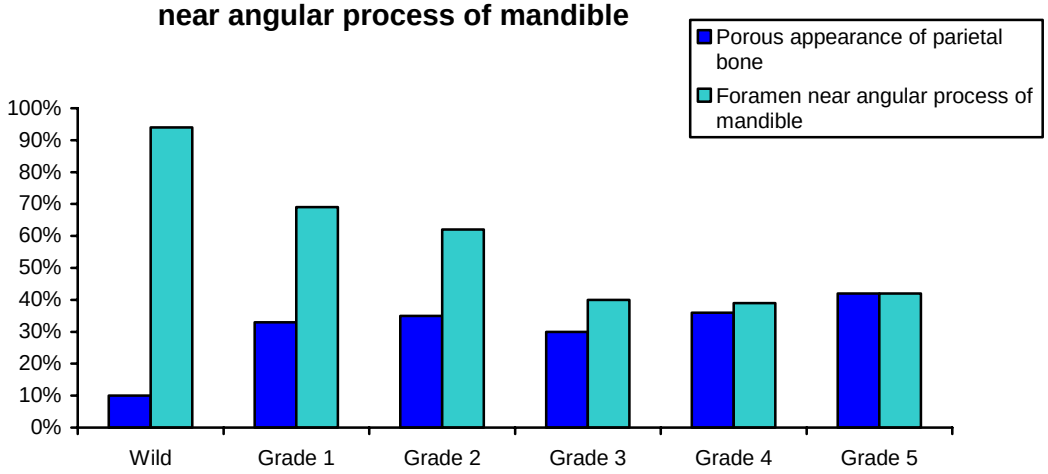

7. Foramen magnum, optic foramen and supra-alveolar foramen

These foramina were examined. There was a variation in their appearance on some of the skulls. Eight skulls showed apparent abnormalities (Figure 33). All these skulls belonged to the Grade 4 and 5 groups.

8. Abscesses

The number of skulls in each grade that have visible abscesses is shown in Graph 11 and Figure 33. The incidence of abscesses was greater in rabbits with advanced dental disease.

Graph 11: Incidence of abscesses in skulls of rabbits of each grade

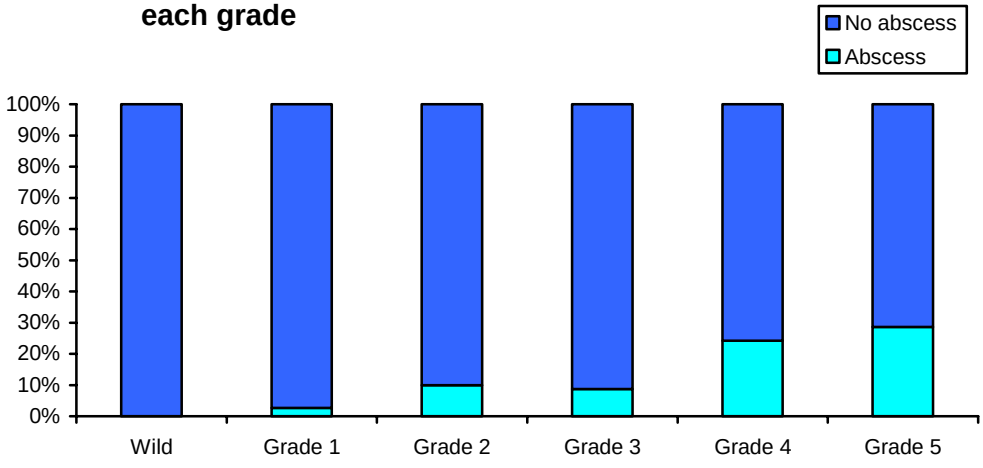

© Frances Harcourt-Brown 2006

Figure 33: Examples of abnormal foramina, porous bone, hole in mandibular ramus and abscesses

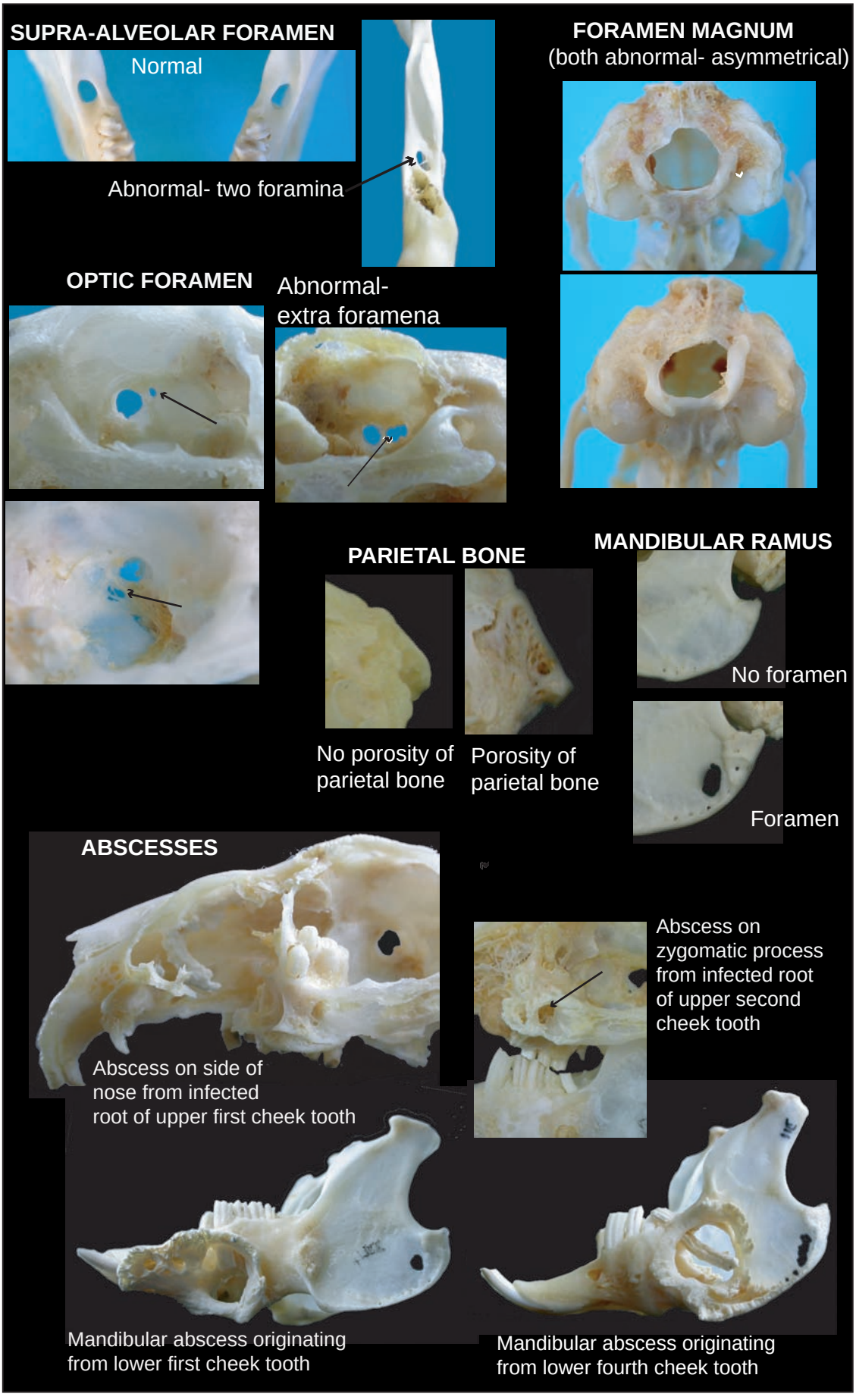

Section 3.2:
Summary of results of morphological examination of skulls

Graph 12: Incidence of morphological changes in 36 skulls from Grade 1 rabbits

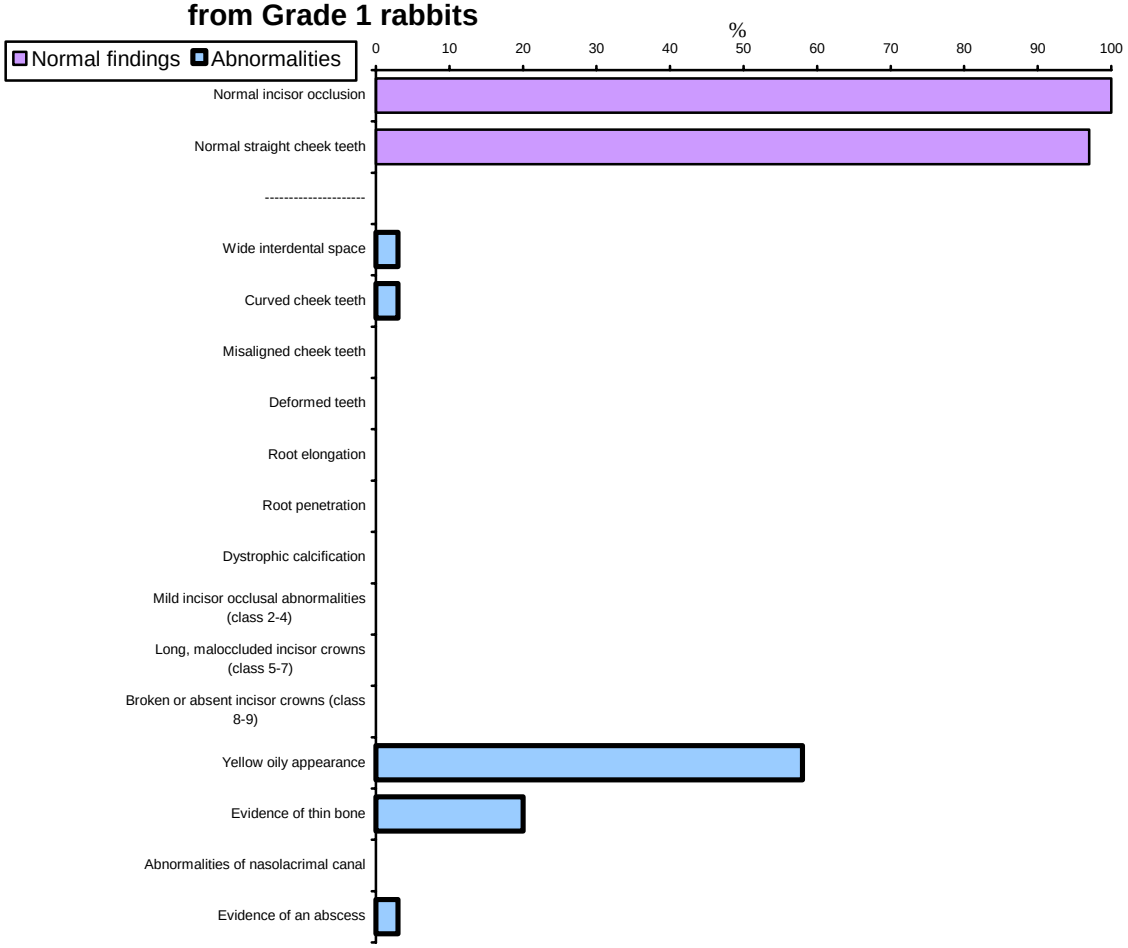

© Frances Harcourt-Brown 2006

Figure 34:
Examples of Grade 1 skulls from pet rabbits



Graph 13: Incidence of morphological changes in skulls from 40 Grade 2 rabbits

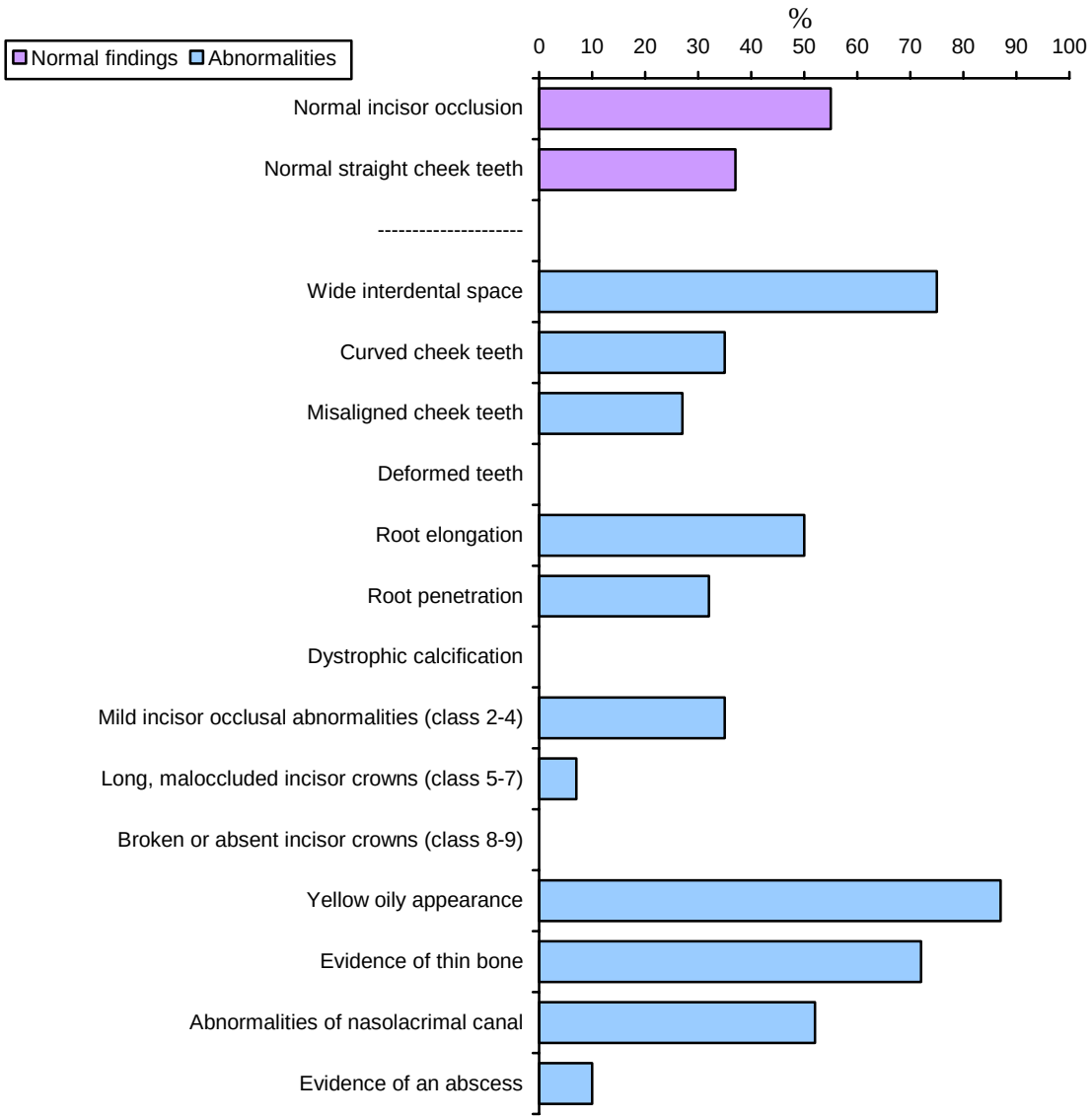

© Frances Harcourt-Brown 2006

Figure 35:
Examples of skulls from Grade 2 pet rabbits



Graph 14: Incidence of morphological changes in 23 skulls from Grade 3 rabbits

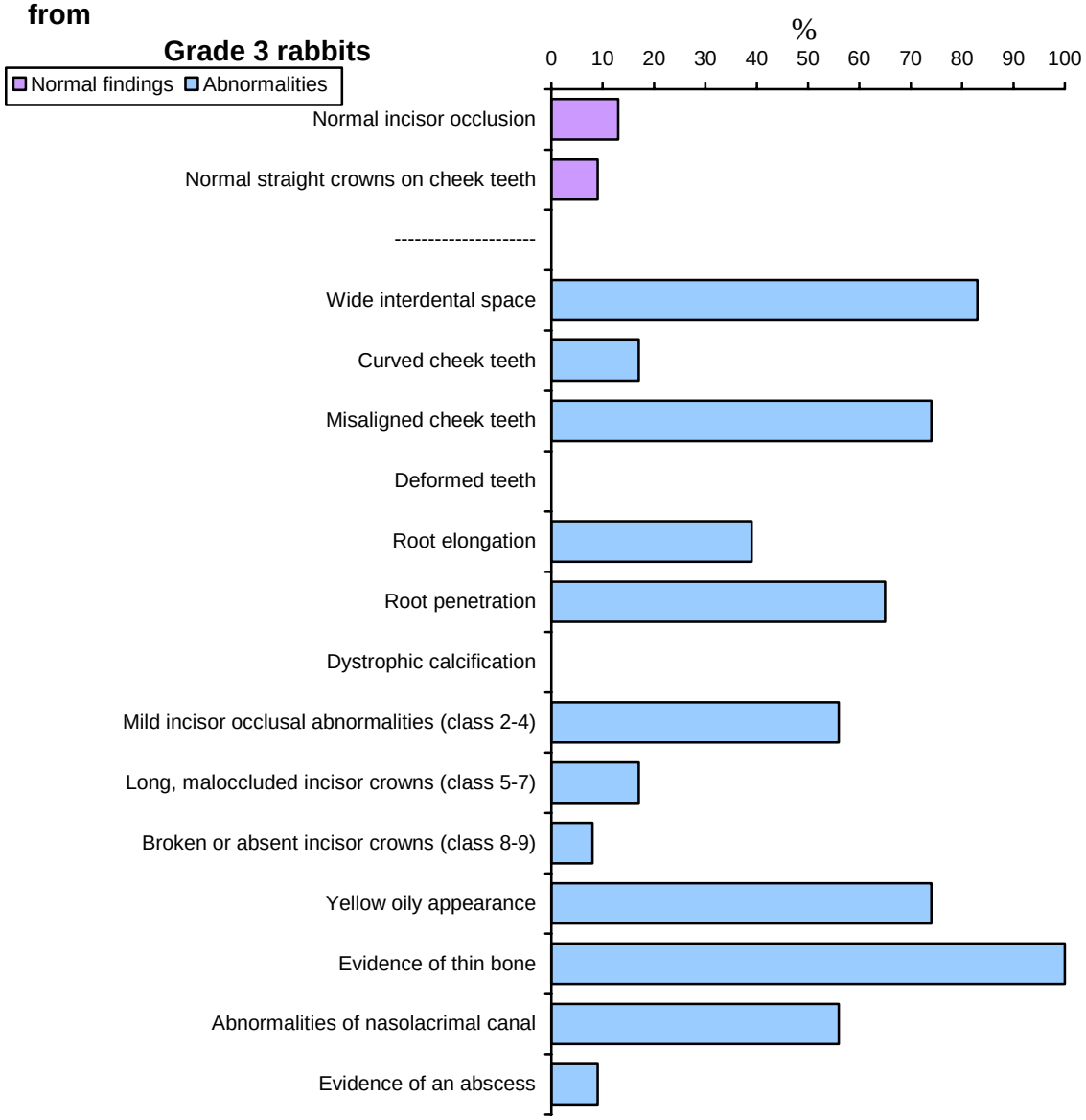

© Frances Harcourt-Brown 2006

Figure 36:
Examples of skulls from Grade 3 pet rabbits



Graph 15: Incidence of morphological changes in 33 skulls from

Grade 4 rabbits

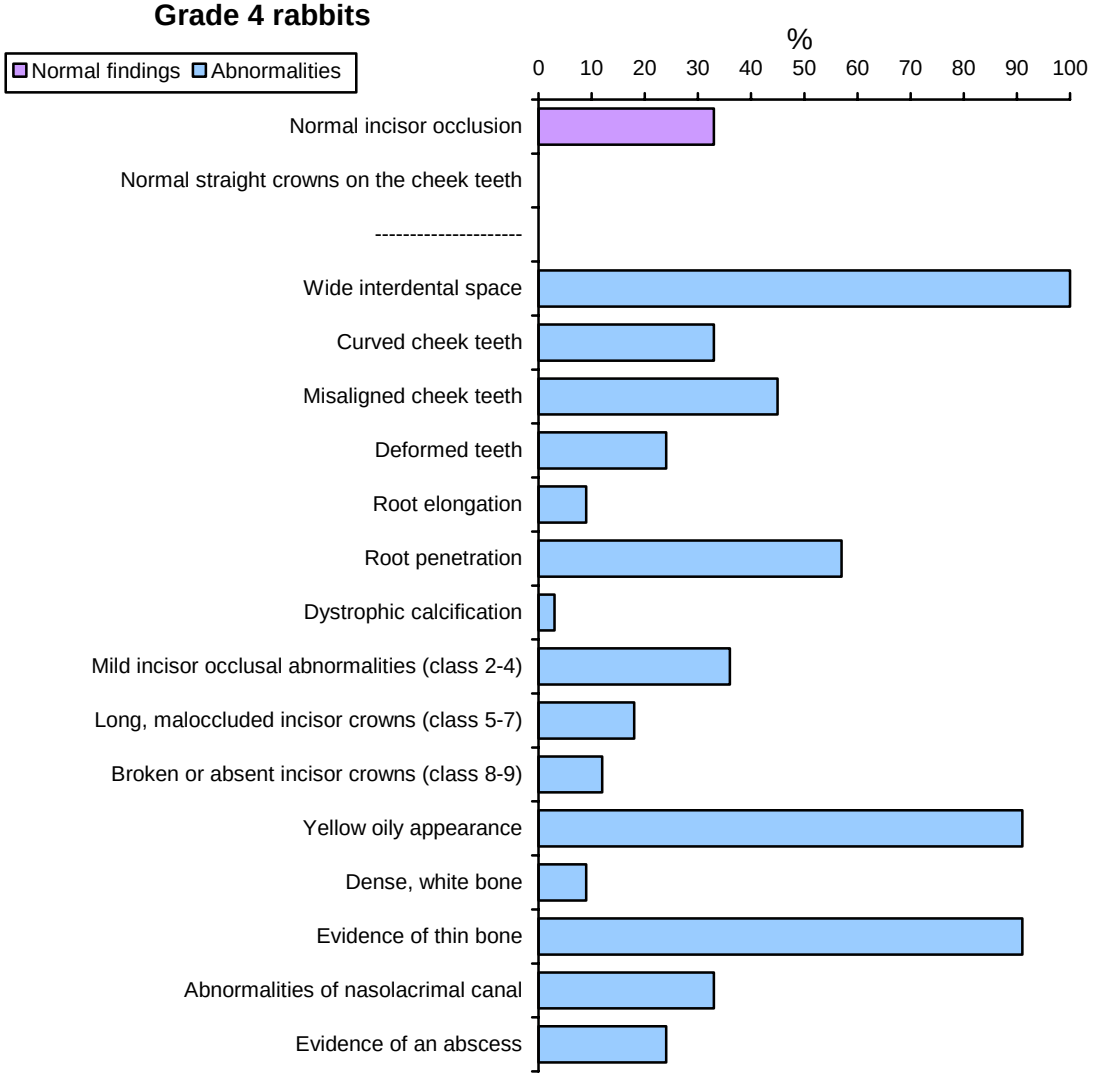

© Frances Harcourt-Brown 2006

Figure 37:
Examples of skulls from Grade 4 pet rabbits



Graph 16: Incidence of morphological changes in 21 skulls from Grade 5 rabbits

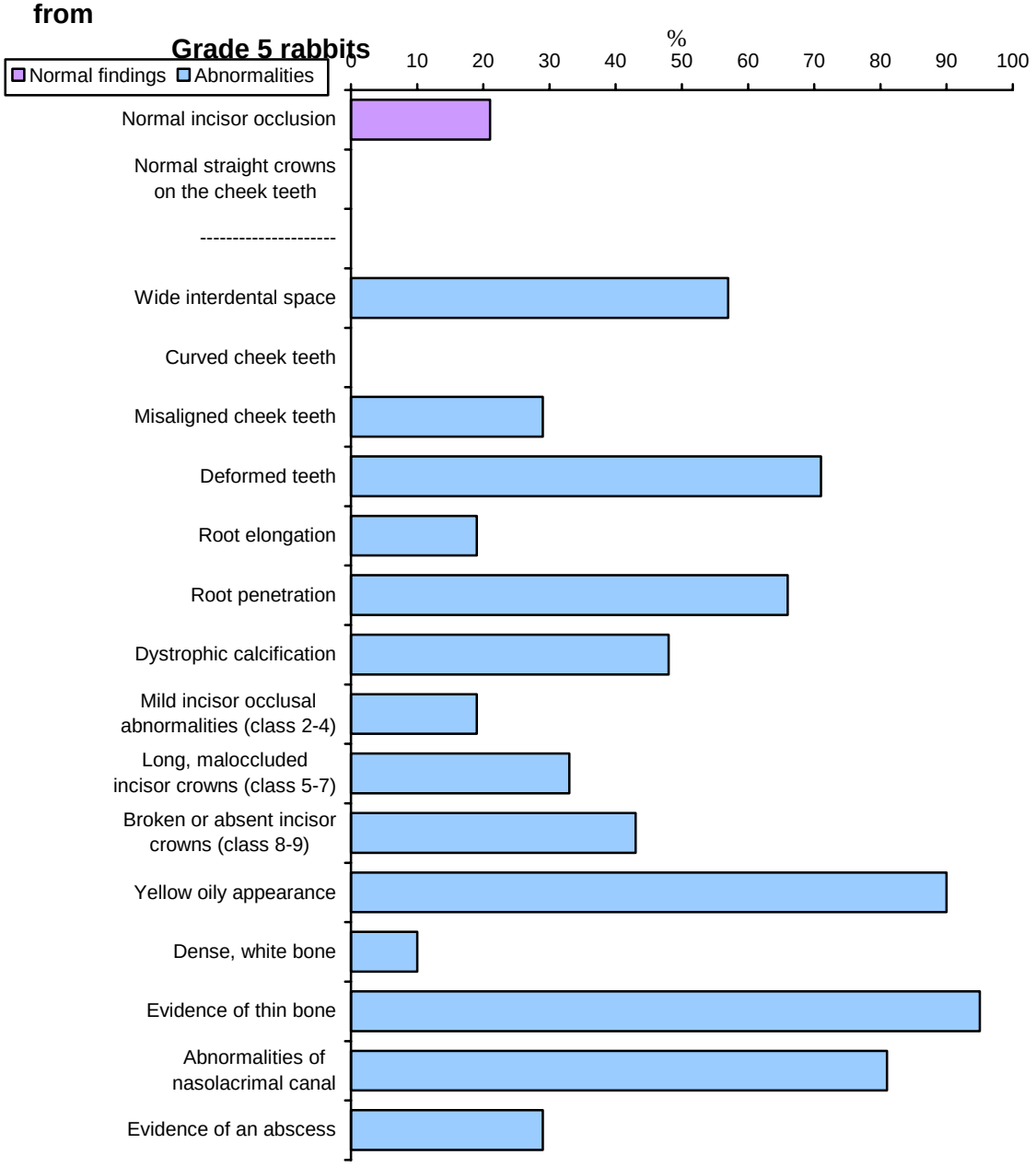

© Frances Harcourt-Brown 2006

Figure 38:
Examples of skulls from Grade 5 pet rabbits

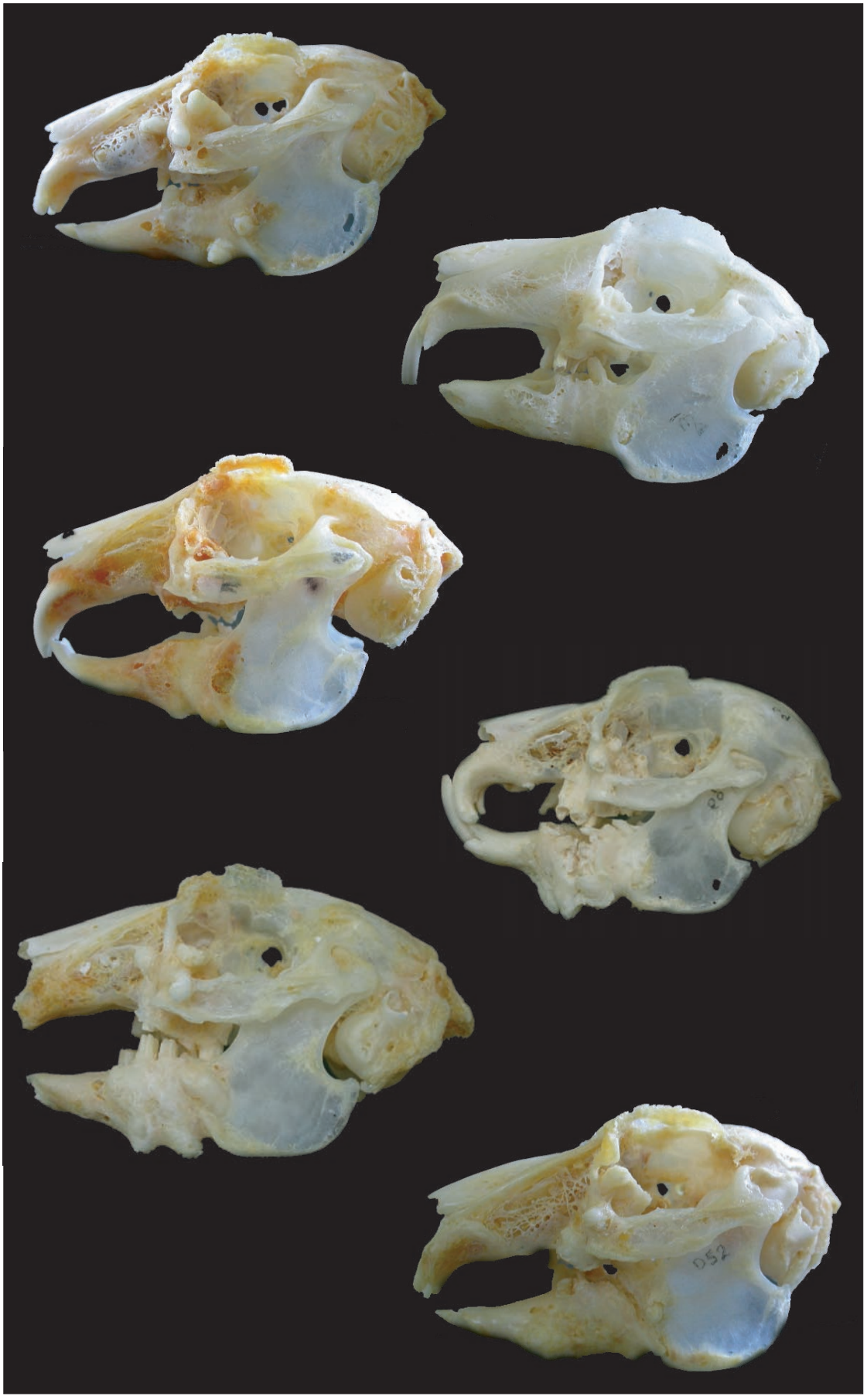

Section 3.3: Results of comparative study of teeth from skulls of rabbits with and without dental disease

Teeth from skulls of wild rabbits

The teeth from the skulls of wild rabbits were smooth and short. Although there was a difference in size between the incisors, premolars and molars of different rabbits, the shape of each tooth was similar. The apex of the root of each tooth was open with a visible pulp cavity. The enamel on the rostral surface of the incisors was thick, smooth and shiny. In many skulls, the supragingival section of the crowns of the cheek teeth was stained brown.

Teeth from skulls of pet rabbits

Most of the teeth from the Grade 1 skulls were similar in appearance to those of the wild rabbits although there was a greater variation in size (Figure 39). Not so many teeth showed brown staining. In some skulls, the incisors had a yellow, oily appearance. The occasional cheek tooth was more curved and longer than those of the wild rabbits.

There was a much wider variation in the size, shape and texture of the teeth from the Grade 2 skulls. Many (at least half) were yellow rather than white. The teeth were long and several were misshapen. The enamel on the rostral surface of the incisors varied from thick, smooth and shiny to horizontal ribbing.

All the teeth from the Grade 3 skulls were long. The majority showed a rough uneven surface. Approximately one quarter of the teeth were misshapen

The teeth from the Grade 4 skulls were misshapen and fragile. The upper cheek teeth were curved and the lower cheek teeth long. The enamel on all the cheek teeth and most of the incisors was absent, thin or ribbed. There were many defects. Examination of the apices of the roots showed them to be closed with no space for a pulp cavity.

Teeth from Grade 5 skulls were not examined. Most could not be extracted from the skulls.

© Frances Harcourt-Brown 2006

Figure 39:
Examples of teeth from skulls of each grade

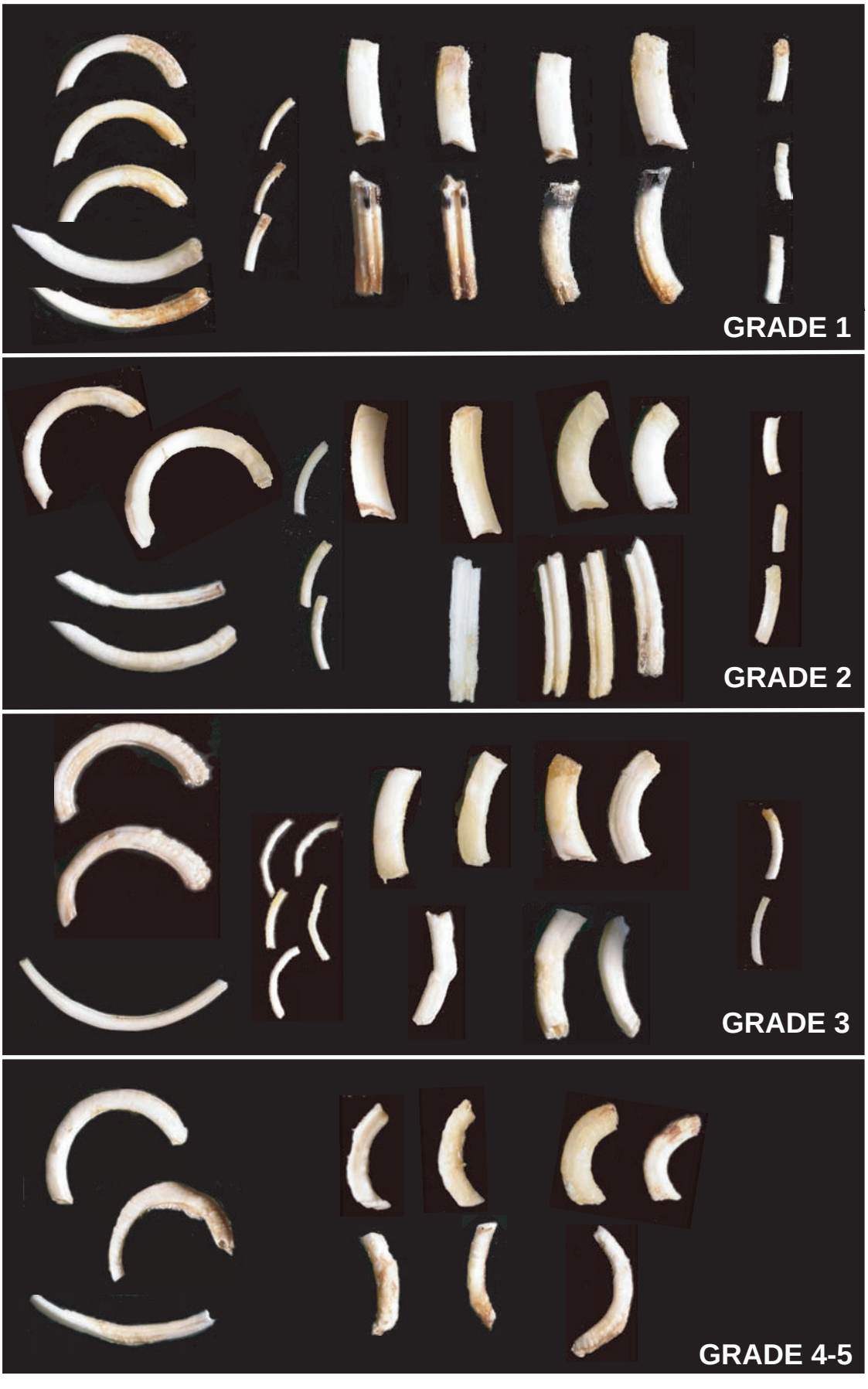

Section 3.4: Results of the study of radiological features of dismembered prepared skulls and teeth of rabbits with and without dental disease

Radiological examination of prepared hemimandibles without teeth

Examples of hemimandibles are shown in Figure 40. They show a progressive loss of alveolar bone between rabbits of each grade.

Hemimandibles from 11 Grade 1 rabbits

These showed the following features:

- Clear radiodense line of the *lamina dura* surrounding each socket.
- The line of the *lamina dura* is present at the extremity of the socket containing the apex of the root
- The apical extremity of each socket did not extend into the ventral mandibular cortex.

Hemimandibles from 16 Grade 2 rabbits

These showed the following features:

- The *lamina dura* was absent from the extremity of the socket in all the hemimandibles
- Some sockets in 15 out of 16 hemimandibles extended to the ventral mandibular cortex
- The *lamina dura* was blurred and indistinct in three of the 16 hemimandibles

Hemimandibles from 12 Grade 3 rabbits

These showed the following features:

- The *lamina dura* was absent from the extremity of the socket in all the hemimandibles
- Some sockets in 11 out of 12 hemimandibles extended to the ventral mandibular cortex. In the remaining hemimandible, the socket extended through the ventral border of the hemimandible
- In three of the hemimandibles, the *lamina dura* was absent in places so the parts of the sockets merged together
- Three out of the 12 hemimandibles appeared radiolucent in comparison with the hemimandibles from wild rabbits.

Hemimandibles from 7 Grade 4 rabbits

These showed the following features:

- The *lamina dura* was absent from the extremity of the socket in all the hemimandibles.
- Some sockets in 5 out of 7 hemimandibles extended to the ventral mandibular cortex. In the remaining 2 hemimandibles, some sockets extended through the ventral border of the hemimandible
- In three of the hemimandibles, the *lamina dura* was absent in places so the parts of the sockets merged together
- Four out of the 7 hemimandibles appeared radiolucent in comparison with the hemimandibles from wild rabbits.

Hemimandibles from Grade 5 rabbits

No hemimandibles without teeth from Grade 5 rabbits were examined because the teeth could not be extracted from the jaw without damaging it.

© Frances Harcourt-Brown 2006

Figure 40:
Examples of lateral view of prepared hemimandibles after removal of teeth

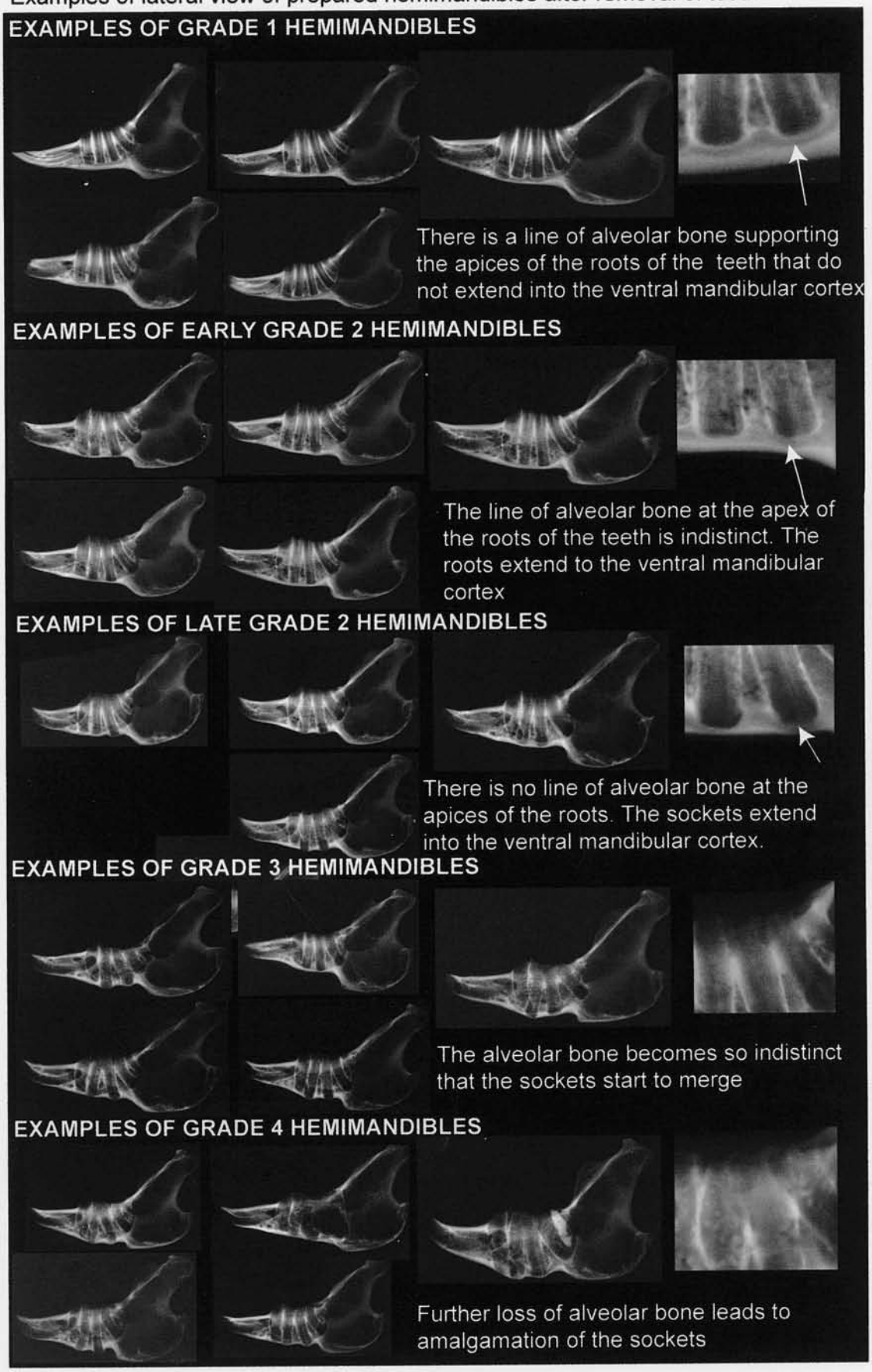

Radiological examination of prepared skulls without mandibles or teeth

Examples of dorsoventral views of prepared skulls without mandibles or teeth are shown in Figure 41 opposite. These show a progressive loss of alveolar bone between rabbits of each grade.

Skulls without mandibles or teeth from 5 Grade 1 rabbits

A defined radiodense line could be seen surrounding each socket.

Skulls without mandibles or teeth from 8 Grade 2 rabbits

These showed the following features:

- In three skulls, the *lamina dura* was blurred and indistinct.
- In two skulls, there was loss of alveolar bone in the interdental area so the sockets were merged.

Skulls without mandibles or teeth from 5 Grade 3 rabbits

These showed the following features:

- In four skulls, the *lamina dura* was blurred and indistinct.
- In three skulls, there was loss of alveolar bone in the interdental area so the sockets were merged.

Skulls without mandibles or teeth from 3 Grade 4 rabbits

These showed the following features:

- In all the skulls, the *lamina dura* was blurred and indistinct.
- In all the skulls, there was loss of alveolar bone in the interdental area so the sockets were merged.

Skulls without mandibles or teeth from 4 Grade 5 rabbits

These showed the following features:

- In all the skulls, the *lamina dura* was blurred and indistinct.
- In all the skulls, there was loss of alveolar bone in the interdental area so the sockets were merged.

© Frances Harcourt-Brown 2006

Figure 41:

Examples of dorsoventral view of prepared maxillae after removal of teeth

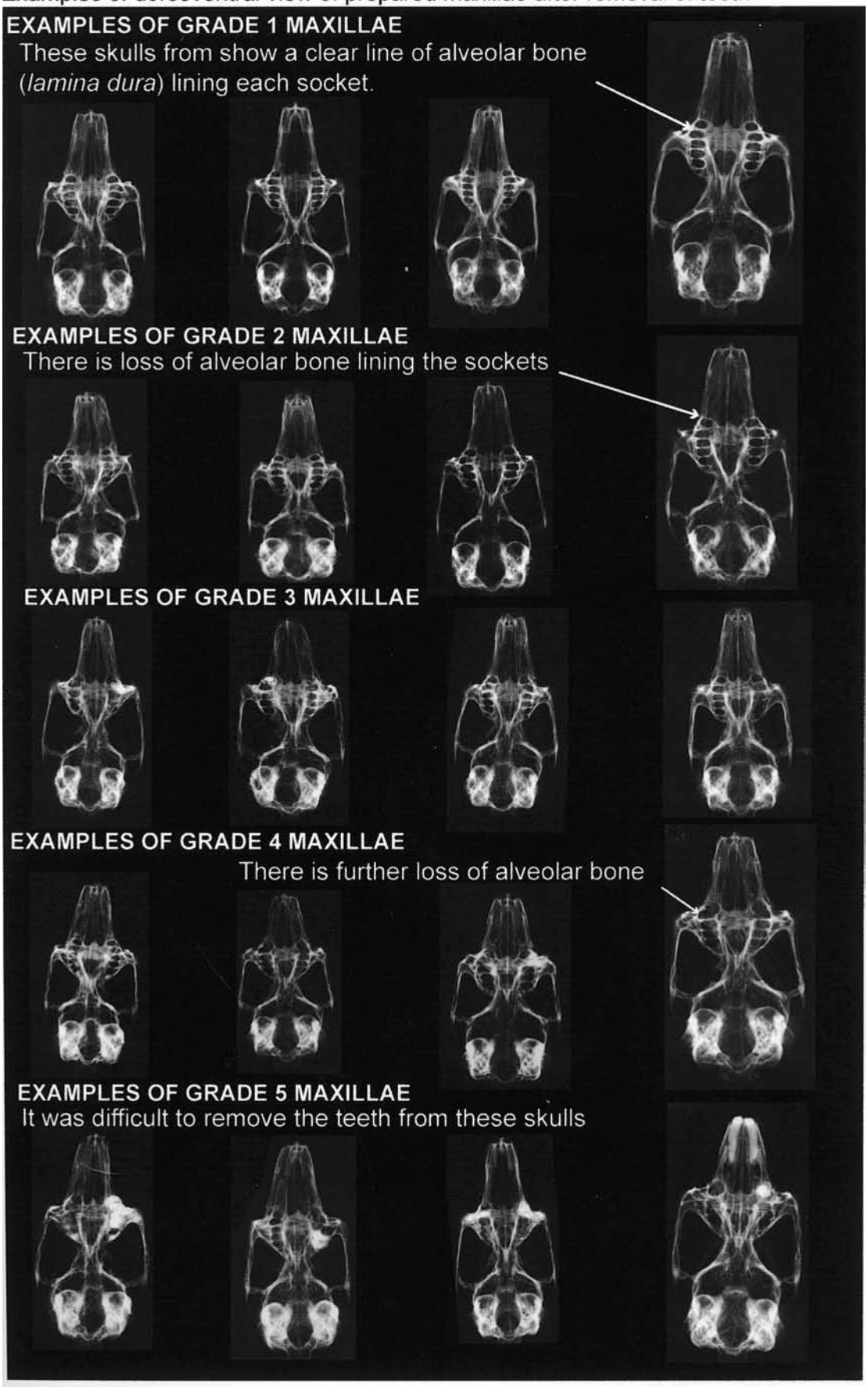

Radiographic examination of the teeth

Radiographs of teeth that were removed from the skulls were examined. Examples of teeth from each grade are shown in Figure 42 opposite.

Teeth from Grade 1 skulls

The longitudinal enamel fold running down the centre of the cheek teeth could be seen as a single or double white line in most of the lower premolars and molars in the teeth from the Grade 1 rabbits although the orientation of the tooth on the X-ray plate affected the visibility of this line. The shape of the occlusal surface was similar on all the cheek teeth although, again, the orientation of the tooth on the X-ray plate affected the image. The occlusal ends of all the primary incisors were chisel shaped.

Teeth from Grade 2 skulls

The teeth from the skulls of Grade 2 pet rabbits were not as uniform in shape and curvature as the teeth from the Grade 1 pet rabbits. The teeth were longer and there was a range of shapes in the occlusal surfaces. The upper primary incisors were more curved and longer. Some showed irregularities of the enamel. In some of the teeth, the pulp cavities were smaller and did not extend as far along the incisor as in the wild rabbits' teeth. There appeared to be an increase in the radiopacity of some of the abnormal teeth. The premolars and molars showed similar changes with striations of abnormal dentine and erosions in the enamel. Many of the lower incisors were longer and straighter than those of Grade 1 rabbits. The line of the enamel fold was thin, wavy and indistinct in some of the cheek teeth. Some of the teeth were misshapen.

Teeth from Grade 3 skulls

The changes that were seen in the teeth from the skulls of Grade 2 rabbits were seen in more of the teeth from the skulls of Grade 3 pet rabbits and in nearly all the teeth from the skulls of Grade 4 rabbits.

Teeth from Grade 4 skulls

It was difficult or impossible to remove teeth in their entirety from skulls of Grade 5 rabbits so this group was not included in this part of the study. Nearly all the teeth from the Grade 4 skulls were misshapen and had no clear lines of enamel. They were either more radiolucent or more radio-opaque than the teeth from wild or Grade 1 rabbits

© Frances Harcourt-Brown 2006

Figure 42:
Examples of radiographic appearance of teeth

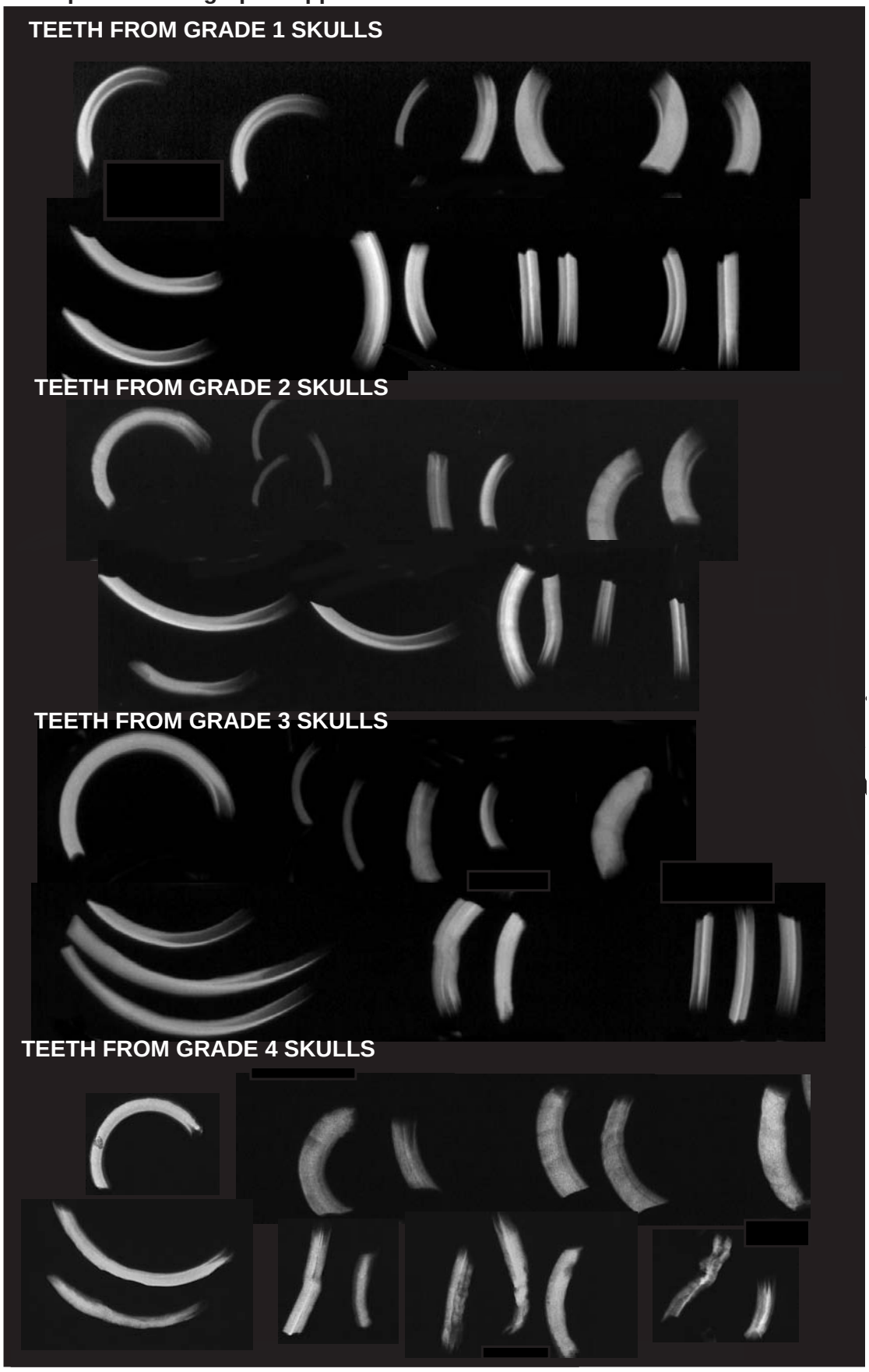

Section 3.5: Results of the study of radiological features of skulls of rabbits with and without dental disease

Radiographs of the heads of 315 pet rabbits presented for veterinary treatment were examined and compared with radiographs of wild rabbits. The raw data are shown in Appendix 3.

Head Shape

Skull radiography showed a wide variation in the head shape of rabbits of different breeds (Figure 43). These variations were not associated with abnormal occlusion except in a small number (6/315) rabbits with prognathism. These rabbits had developed incisor malocclusion at a young age (less than 6 months) but showed no other dental abnormality.

Resting occlusion

The occlusal relationship of the teeth was examined on lateral skull radiographs. Whether the incisors and the cheek teeth were in occlusion at the same time was checked on all 315 lateral radiographs, especially of those with normal dentition (Wild and Grade 1 rabbits). This feature could only be assessed on a true lateral view. No radiographs showed the cheek teeth out of occlusion and the incisors in occlusion as described by Crossley (Crossley 1995, 1998, 2000, 2000a, 2003a, 2003b, Figure 59) as the normal resting position.

'Convergence'

The angle between the line of the hard palate and the rostal mandible was examined to see if it was convergent (Figure 43). The results are shown in Graph 17.

Graph 17: Number of radiographs showing 'convergance' in each grade

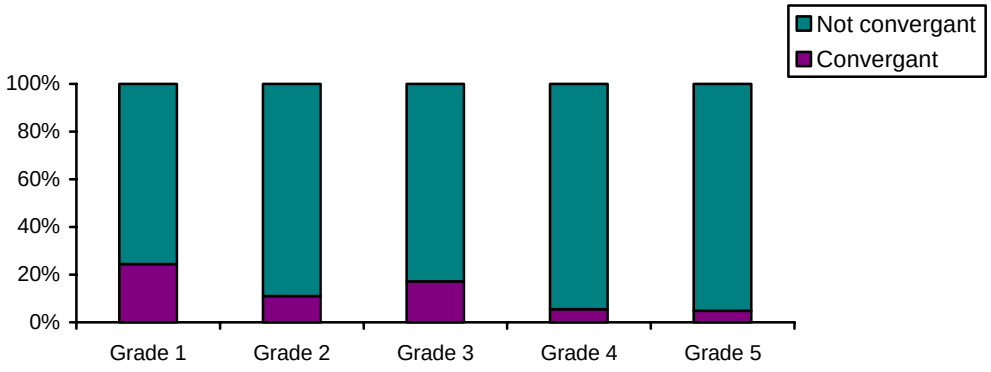

Although Graph 17 shows a trend towards loss of convergence associated with acquired dental disease, it was not a universal feature. Some rabbits with dental disease showed convergence and some rabbits without dental disease showed no convergence.

© Frances Harcourt-Brown 2006

Figure 43:
Variations in skull shape of adult rabbits of various breeds

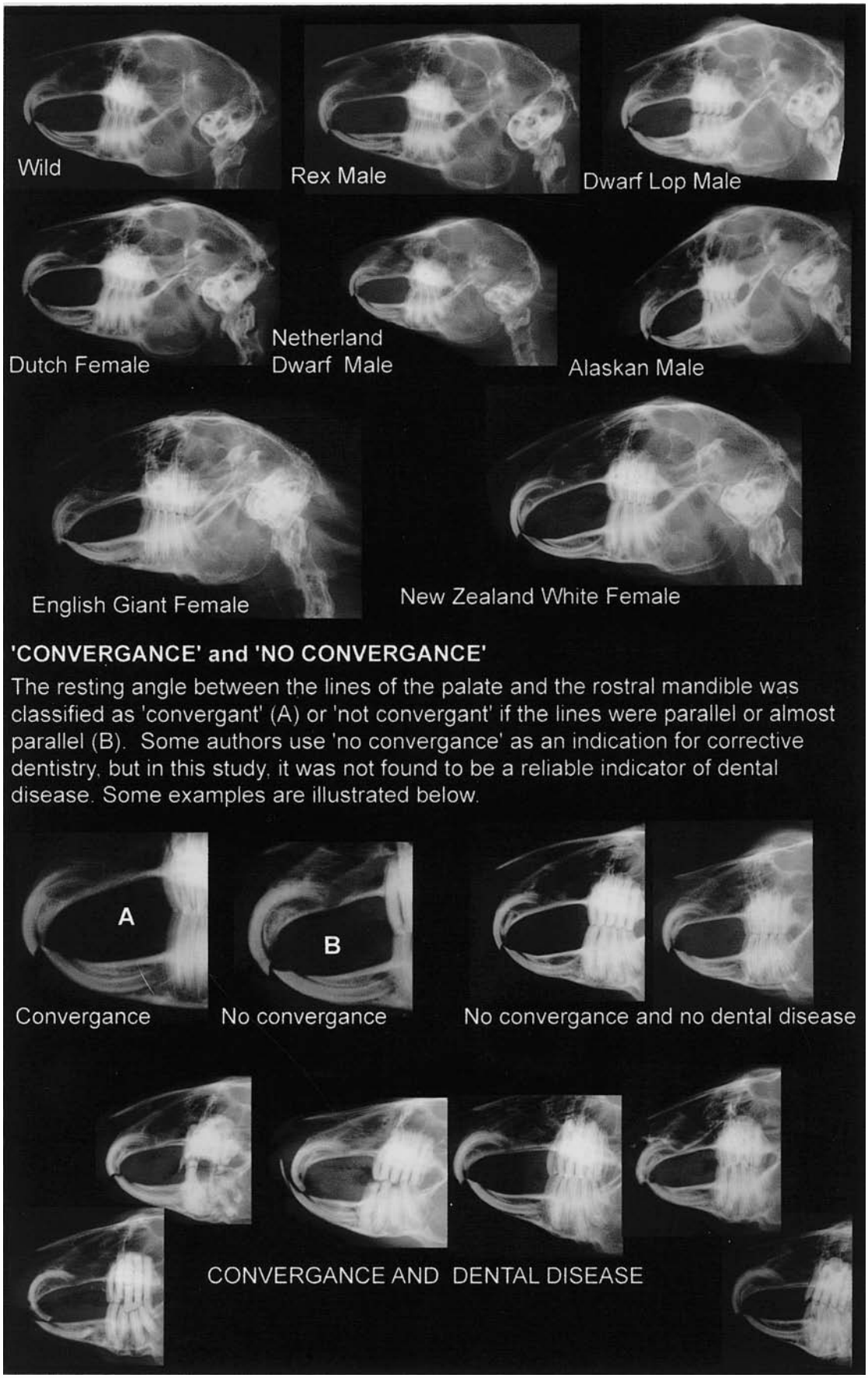

a) Shape, structure and occlusion of the incisors

The changes that were seen in the shape and structure of the incisors are shown in Graph 18.

Graph 18: Changes in the shape and structure of the incisors

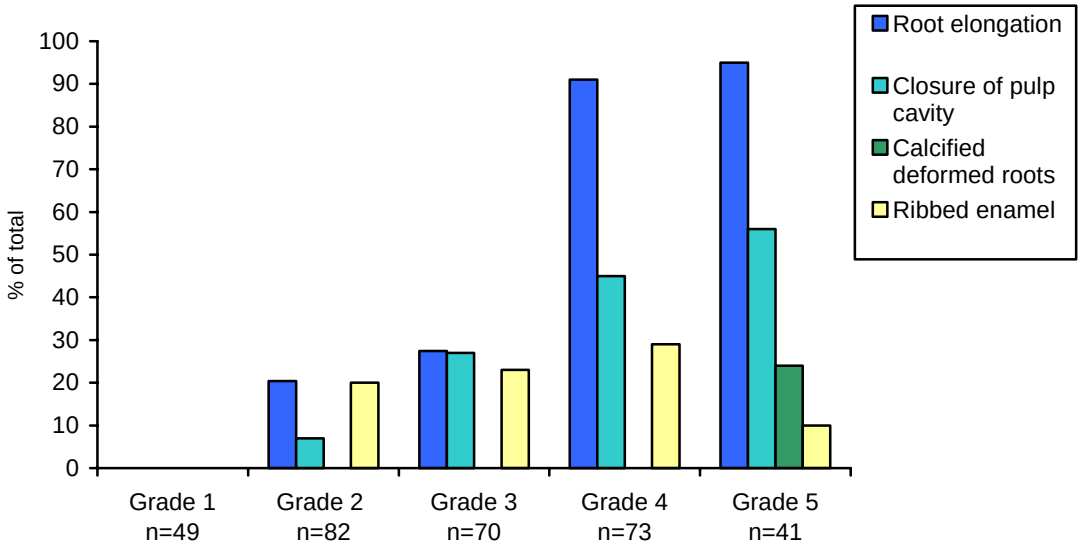

Examples of the changes in the shape and structure of the incisors and of the different classes of incisor malocclusion are shown Figure 44 and Graphs 18 and 19.

Graph 19: Class of incisor occlusion of rabbits of different grades- assessed from radiographs

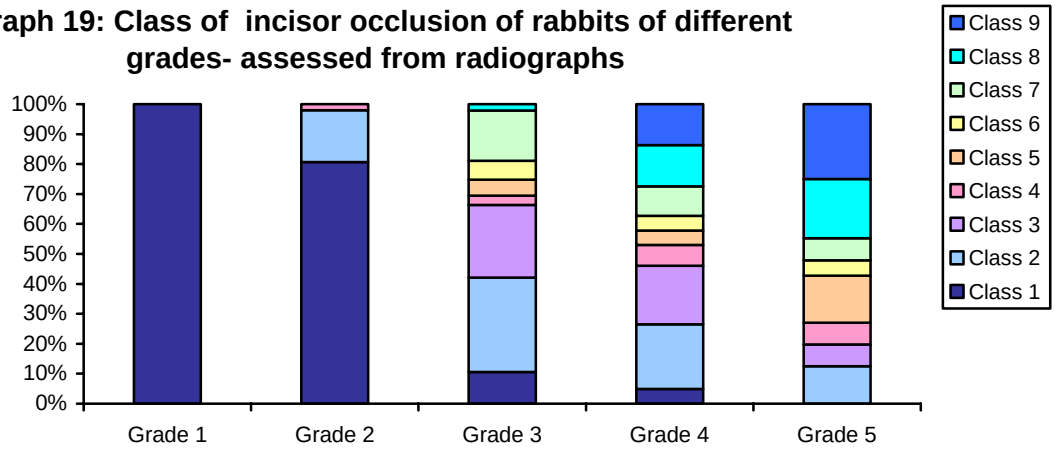

This distribution of incisor occlusion of rabbits of each grade was similar to that determined from examination of the skulls. The examples shown in Figure 44 illustrate the wide variation in the direction of growth of the incisors and their length and shape. Graphs 18 and 19 suggest that the development of incisor abnormalities follows a progressive course. Root elongation and horizontal ribs on the incisors are followed by closure of the pulp cavity and dystrophic calcification of the roots and/or surrounding bone. The majority of Grade 3, 4 and 5 rabbits showed abnormal incisor occlusion with a greater proportion of rabbits with deformed or absent crowns in the Grade 5 rabbits.

© Frances Harcourt-Brown 2006

Figure 44: Examples of radiographic changes in incisors and classes of incisor occlusion

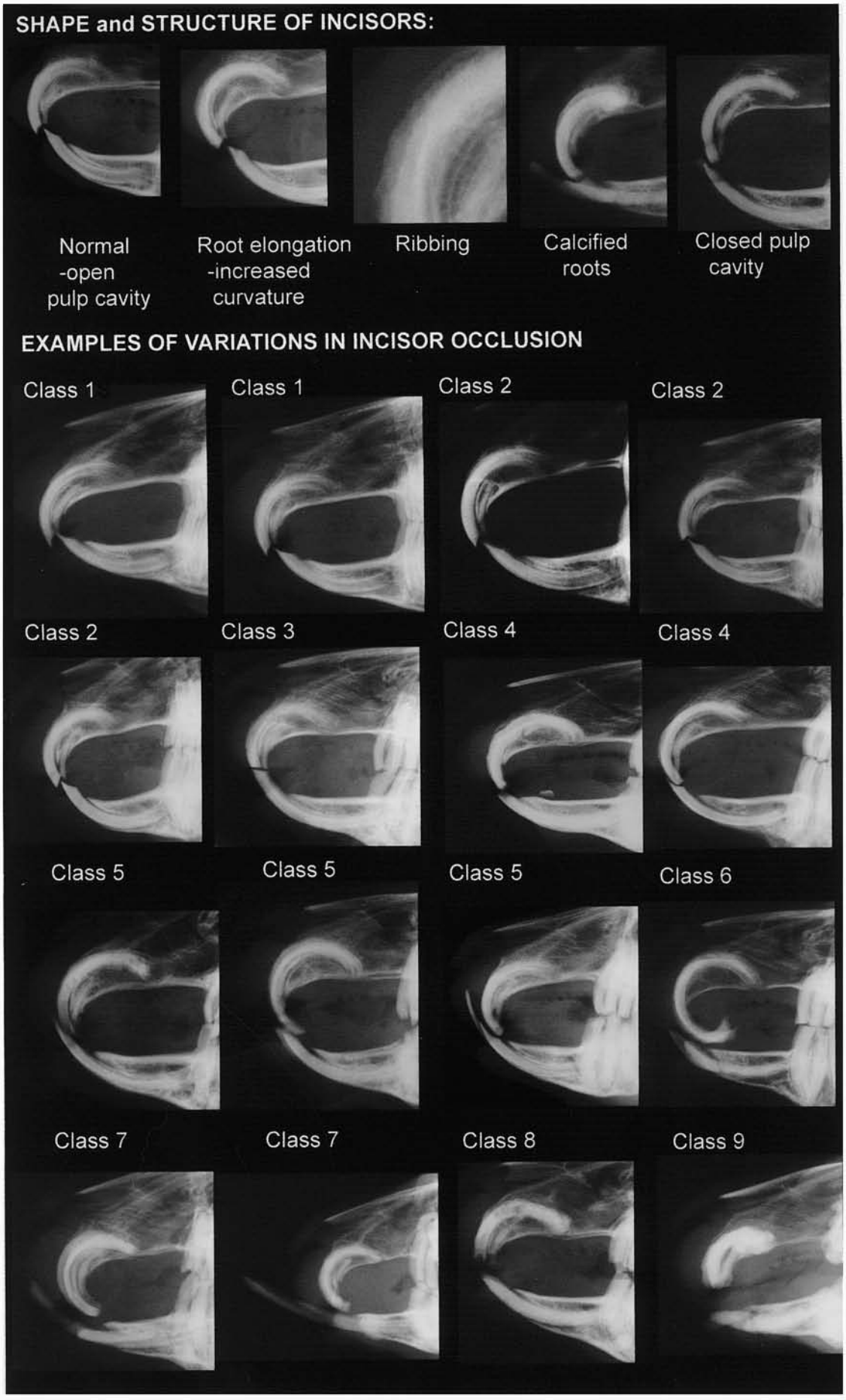

b) Occlusal line of the cheek teeth

Lateral radiographs of all but one of the Grade 1 rabbits and 75% of the Grade 2 rabbits showed the characteristic zigzag occlusal line between the cheek teeth of rabbits. An uneven, rather than zigzag, occlusal line was a radiographic characteristic of rabbits with dental disease. None of the Grade 5 rabbits with advanced changes showed this feature because the crowns were absent, deformed or showed evidence of dystrophic calcification (Graph 20, Figure 45).

Graph 20: Changes in crowns of cheek teeth on lateral views of the skull of rabbits in each grade

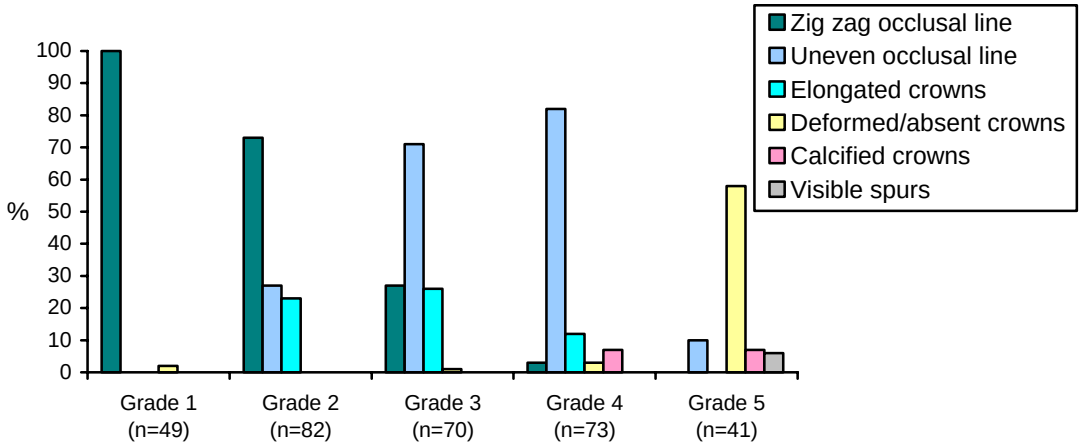

c) Shape and structure of the crowns of the cheek teeth

Visible spurs on the crowns of the cheek teeth were a radiographic feature of the later stages of dental disease. This does not reflect the clinical situation where sharp spurs on the lower cheek teeth are a feature of Grade 3 (acquired malocclusion) rabbits. The spurs curve towards the tongue and cause considerable soft tissue damage. But, they are not seen on lateral skull radiographs because they are angled at 90° to the X-ray plate. In the Grade 5 rabbits, the teeth were so deformed that spurs grew at different angles and could be seen on lateral skull radiographs.

The mesial surface of the first upper premolars proved a useful site to assess the shape and structure of the crowns (Graph 21). Defects could be seen. Examples are shown in Figure 45.

Graph 21: Appearance of mesial surface of upper premolar on lateral view of the skull

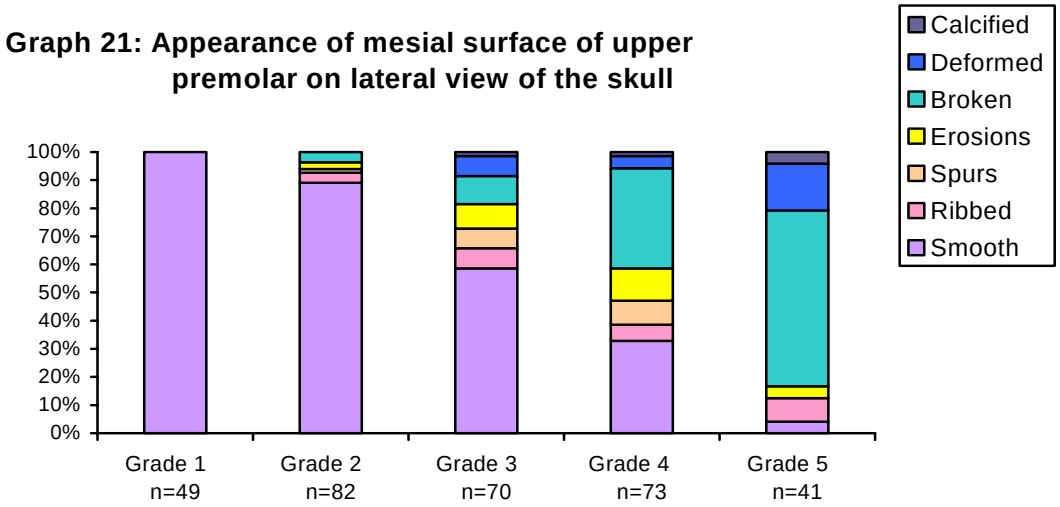

© Frances Harcourt-Brown 2006

Figure 45:
Examples of radiographic changesof cheek teeth

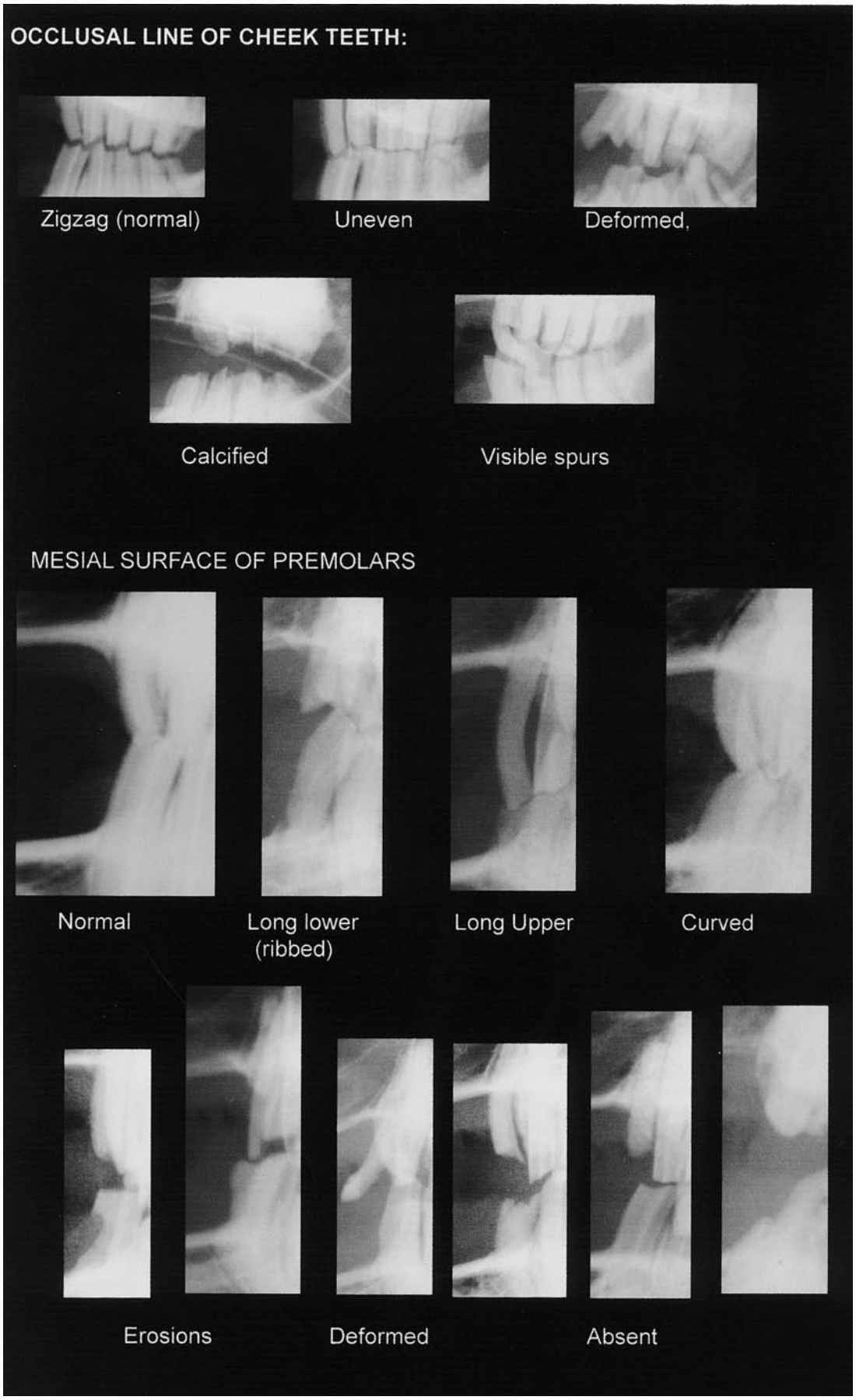

d) Roots of the cheek teeth

The roots of the cheek teeth showed the most dramatic radiographic changes. Root elongation, loss of the *lamina dura*, blurred roots, deformed misshapen roots, dystrophic calcification or resorbed roots were seen (Graph 22, Figure 46). All the radiographs of rabbits with dental disease (Grades 2-5) showed at least one of these features. They **all** showed elongation of the roots, indicating that this is the first change to take place in rabbits with PSADD. None of the Grade 1 rabbits showed this feature.

Graph 22: Changes in cheek teeth roots on lateral skull radiographs of rabbits in each grade

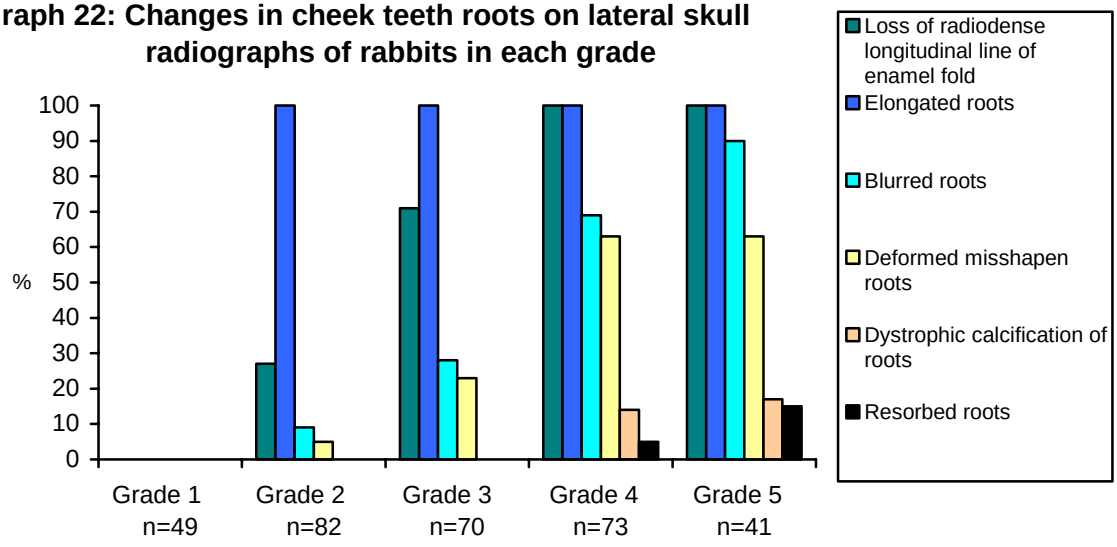

After root elongation, the next most common feature was loss of the radiodense longitudinal fold of enamel in the centre of the cheek teeth. Blurring of the roots was a feature of the Grade 4 and 5 rabbits. This was caused by loss of definition of the radiodense *lamina dura* and changes in the structure of the teeth, which had a homogenous appearance with no clear enamel edge to their outline and no longitudinal enamel fold. Some tooth roots were deformed and misshapen, especially the roots of the lower fourth cheek tooth. On many of the radiographs of the Grade 5 rabbits, it was impossible to distinguish between one tooth and another. They had amalgated (Figure 46)

© Frances Harcourt-Brown 2006

Figure 46:
Examples of radiographic changes in roots of the cheek teeth

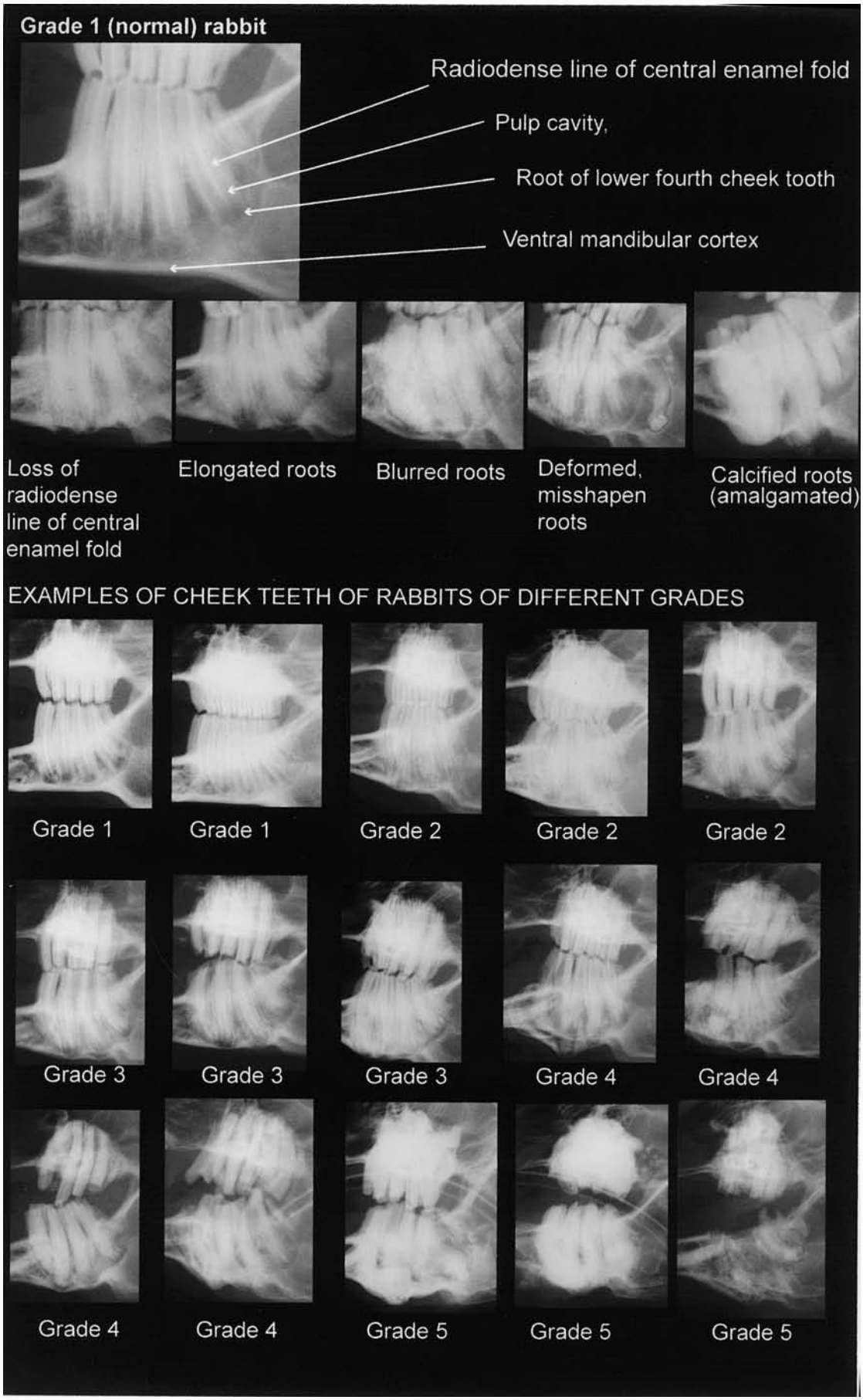

e) Alveolar bulla

It was not possible to assess the bone in the alveolar bulla on all lateral radiographs because of superimposition. Some radiographs had to be classified as inconclusive. The number of inconclusive radiographs was greater in the earlier stages of dental disease. All the radiographs of the Grade 5 rabbits and the majority of the ones of the Grade 4 rabbits showed root elongation and penetration of the bone. A clear line of bone overlying the upper cheek teeth was only seen in radiographs of Grade 1 rabbits (Graph 23, Figure 47).

Graph 23: Changes in alveolar bulla on lateral skull radiographs

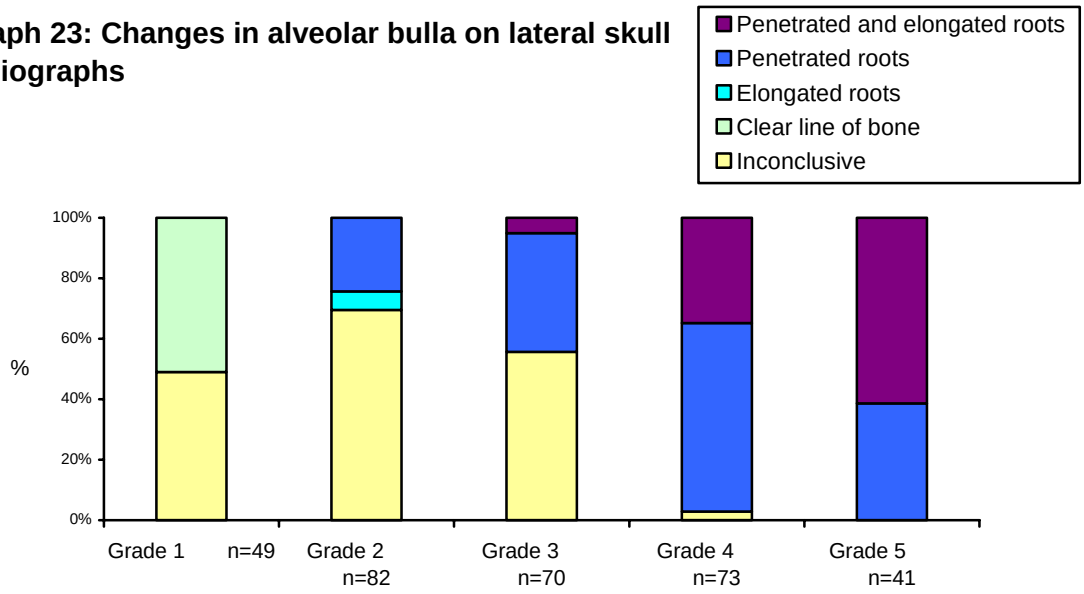

f) Apex of the root of the lower fourth cheek tooth

Previous examination of prepared skulls showed that the apex of the root and the periapical area of bone of the fourth lower cheek tooth is an area where the bone is thin and often penetrated by elongated roots. This could be seen on lateral skull radiographs (Graph 24, Figure 47).

Graph 24: Radiolucency at apex of root of lower fouth cheek tooth on skull radiographs of rabbits of each grade

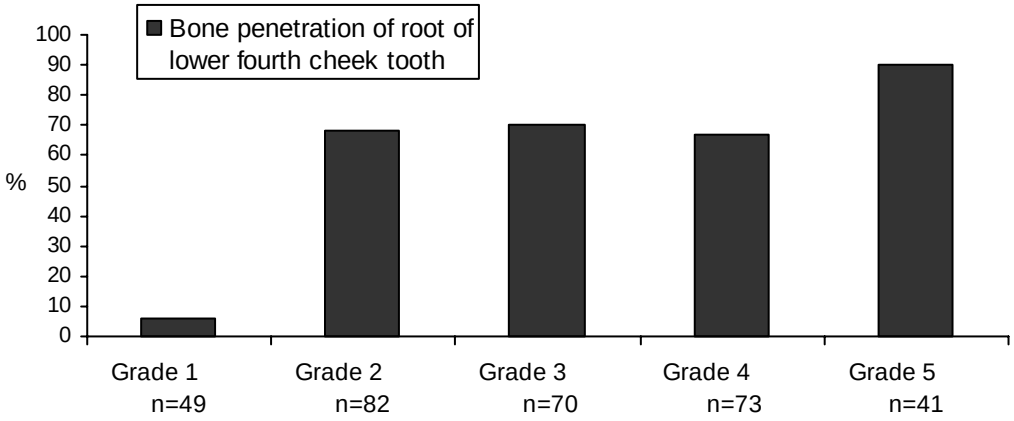

© Frances Harcourt-Brown 2006

Figure 47:
Radiographic changes to alveolar bulla and signs of reduced bone density

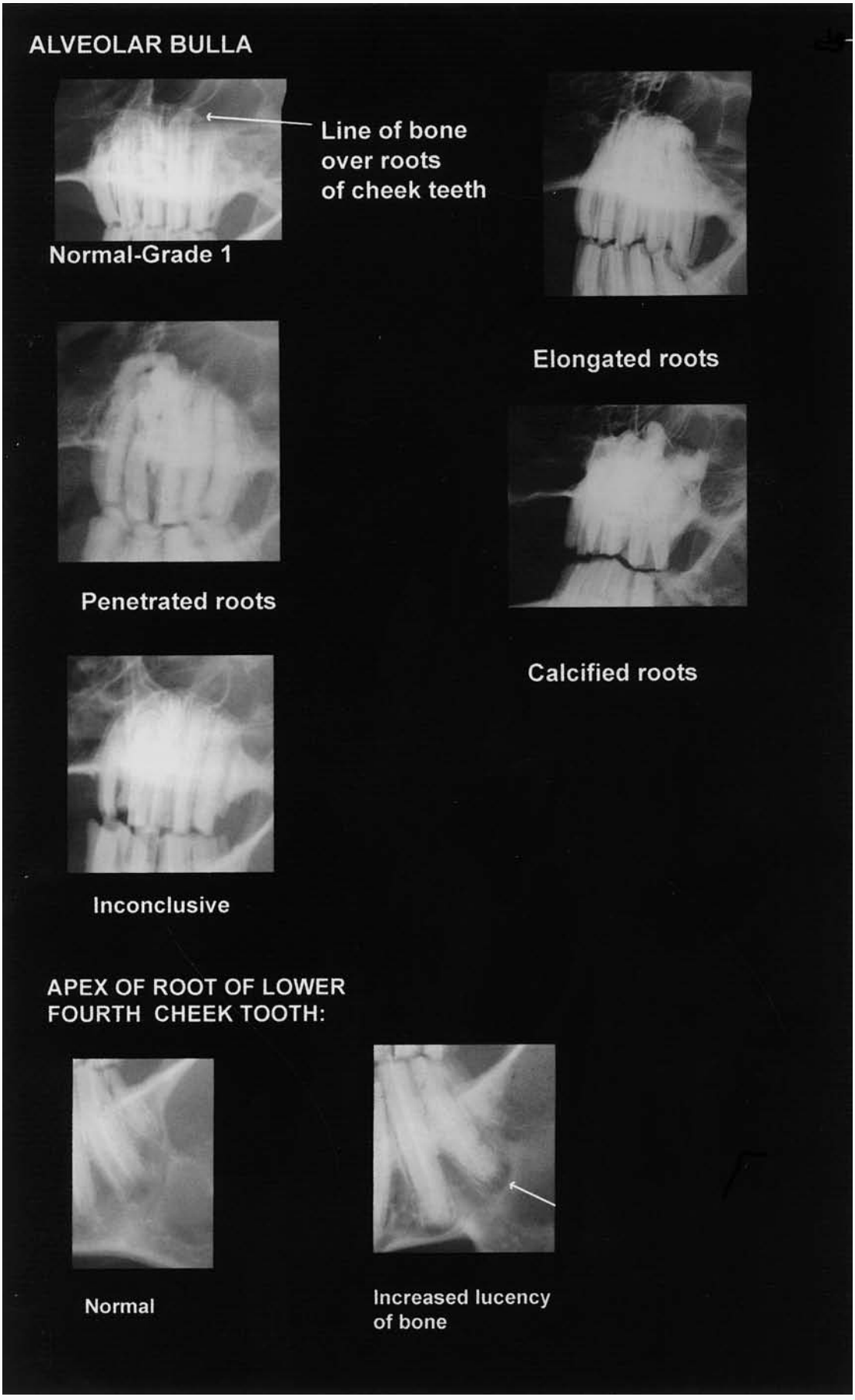

g) Radiographic evidence of osteopaenia

On lateral skull radiographs, bone loss was assessed by looking at the thickness of the cortical lines, especially those of the hard palate and the ventral mandible. On all the lateral views of the skulls of rabbits with dental disease (Grades 2-5), elongated roots of the lower cheek teeth had grown into the cortical bone of the ventral border of the mandible, so this area was deformed and difficult to classify. Therefore, only the line of cortical bone along the hard palate was used to assess cortical bone thickness. Generalised loss of radiodensity of the bones of the skull was assessed by looking at the bone of the rami of the mandibular condyles (Figure 48).

On the dorsoventral view, loss of radiodensity was assessed by looking at the structure of the bone of the zygomatic arch and comparing it with a dorsoventral view of the skull of a wild rabbit. All rabbits showing advanced signs of dental disease (Grade 5) showed radiographic evidence of bone loss in comparison with rabbits in early stages of dental disease. Evidence of bone loss increased in proportion to the severity of dental disease (Graph 25, Figure 48).

Graph 25: Percentage of rabbits in each grade showing radiographic evidence of osteopaenia on lateral and dorsoventral skull radiographs

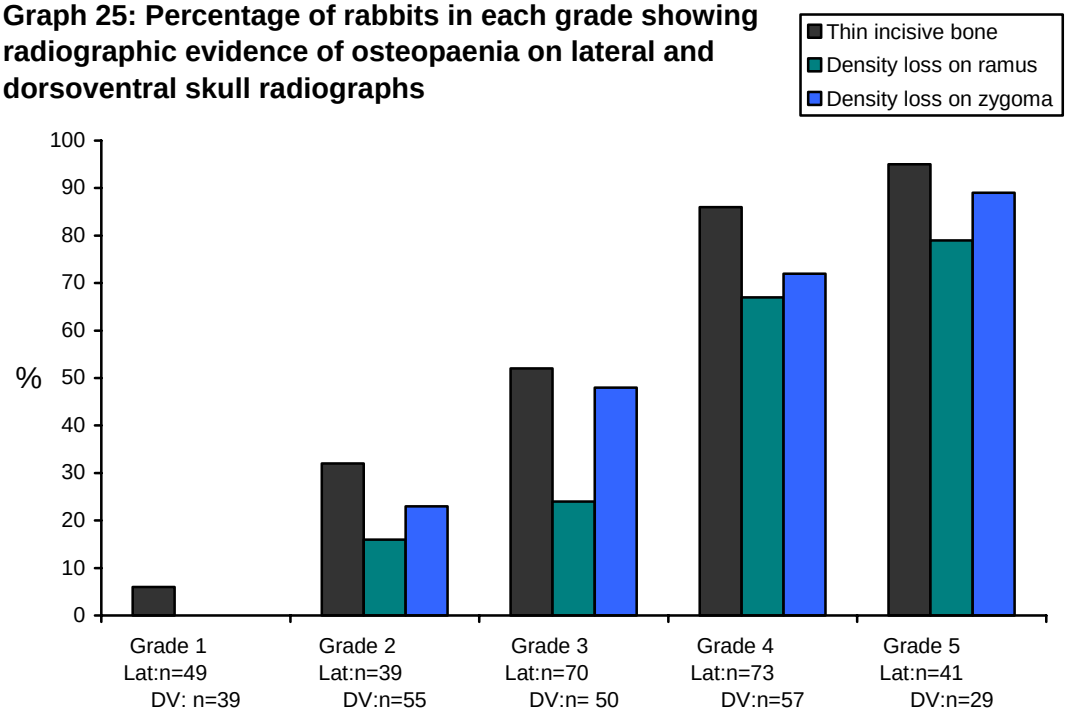

© Frances Harcourt-Brown 2006

Figure 48:
Radiographic signs of osteopaenia

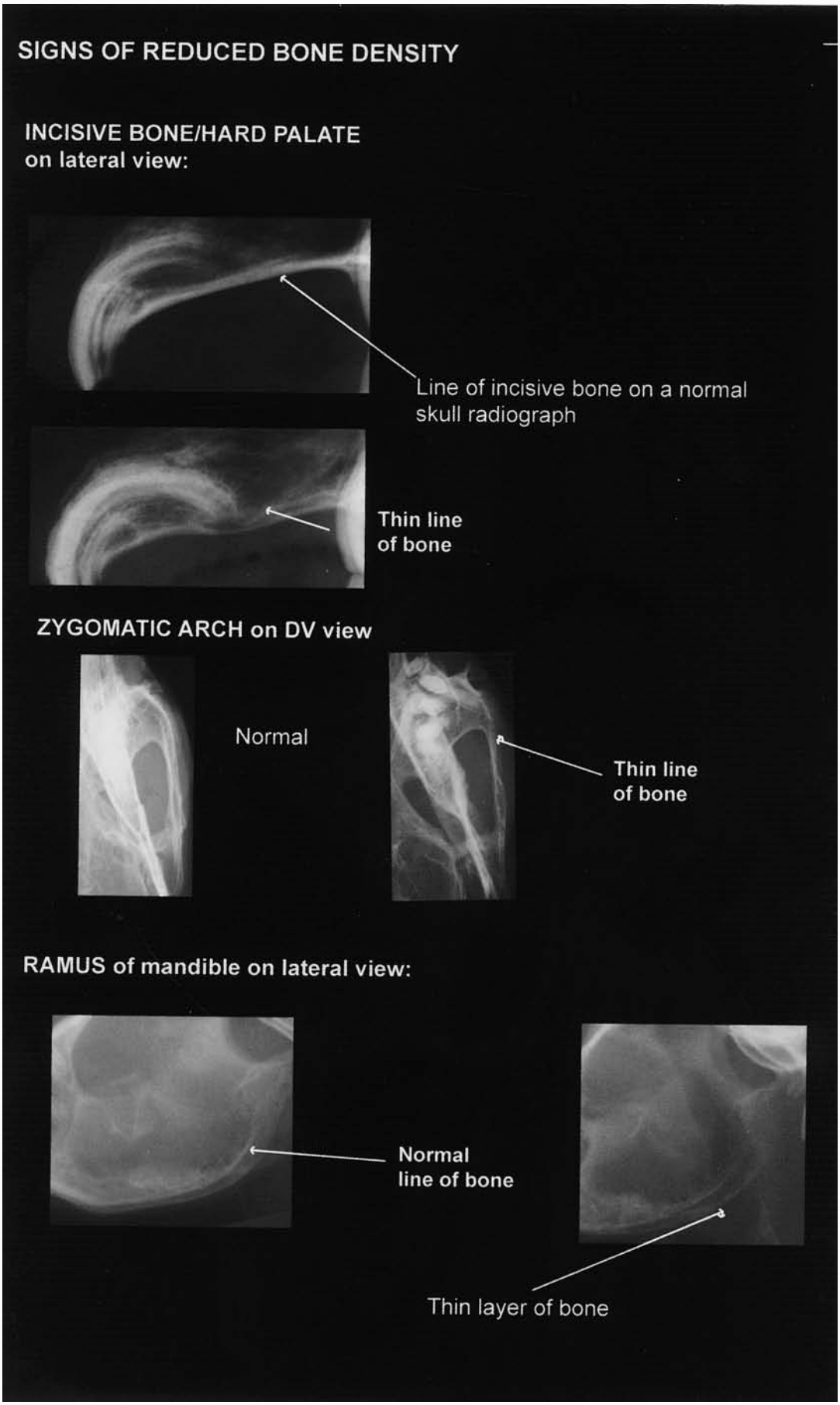

h) First upper premolars on dorsoventral view

The first upper premolars on the dorsoventral view proved a valuable site for assessing the structure of the tooth and the surrounding bone. The *lamina dura* could be seen, without superimposition, as a circle of bone encompassing the tooth. Nearly all the radiographs of Grade 1 rabbits showed a clear circle of *lamina dura* surrounding the tooth. The *lamina dura* could only be seen in a few of the radiographs of Grade 4 rabbits and none of the Grade 5 rabbits indicating that loss of alveolar bone was an early change that increased as dental disease progressed. Other changes, such as elongation, penetration of the bone, deformity or dystrophic calcification and increased radiodensity of embedded roots and the surrounding bone could also be seen at the upper first premolar (Graph 25, Figure 49).

Graph 26: Appearance of upper premolar on dorsoventral view

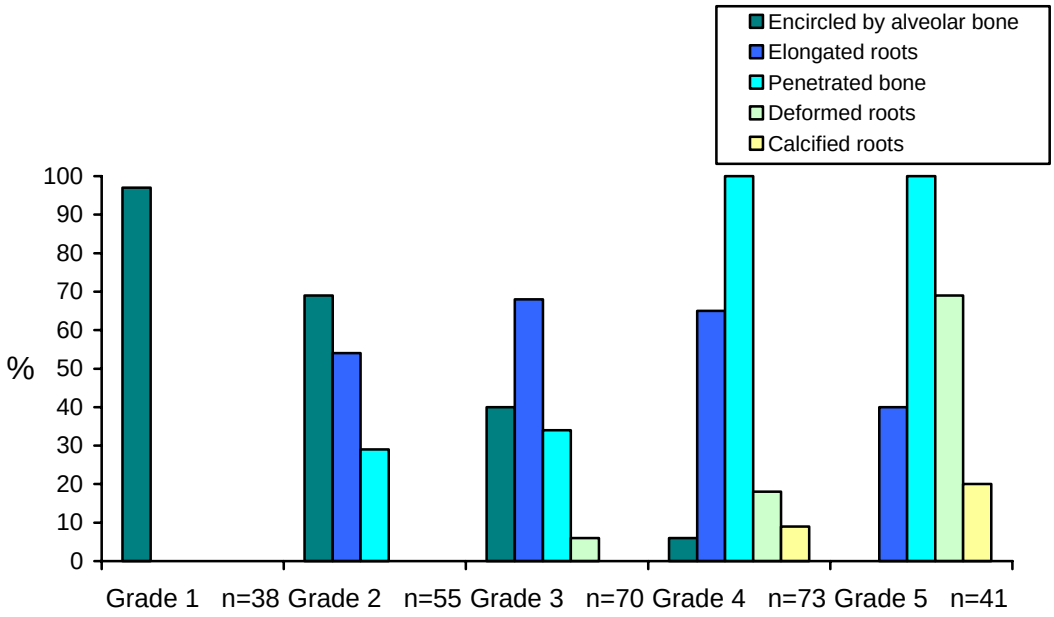

© Frances Harcourt-Brown 2006

Figure 49:
Examples of appearance on first upper premolar on dorsoventral view

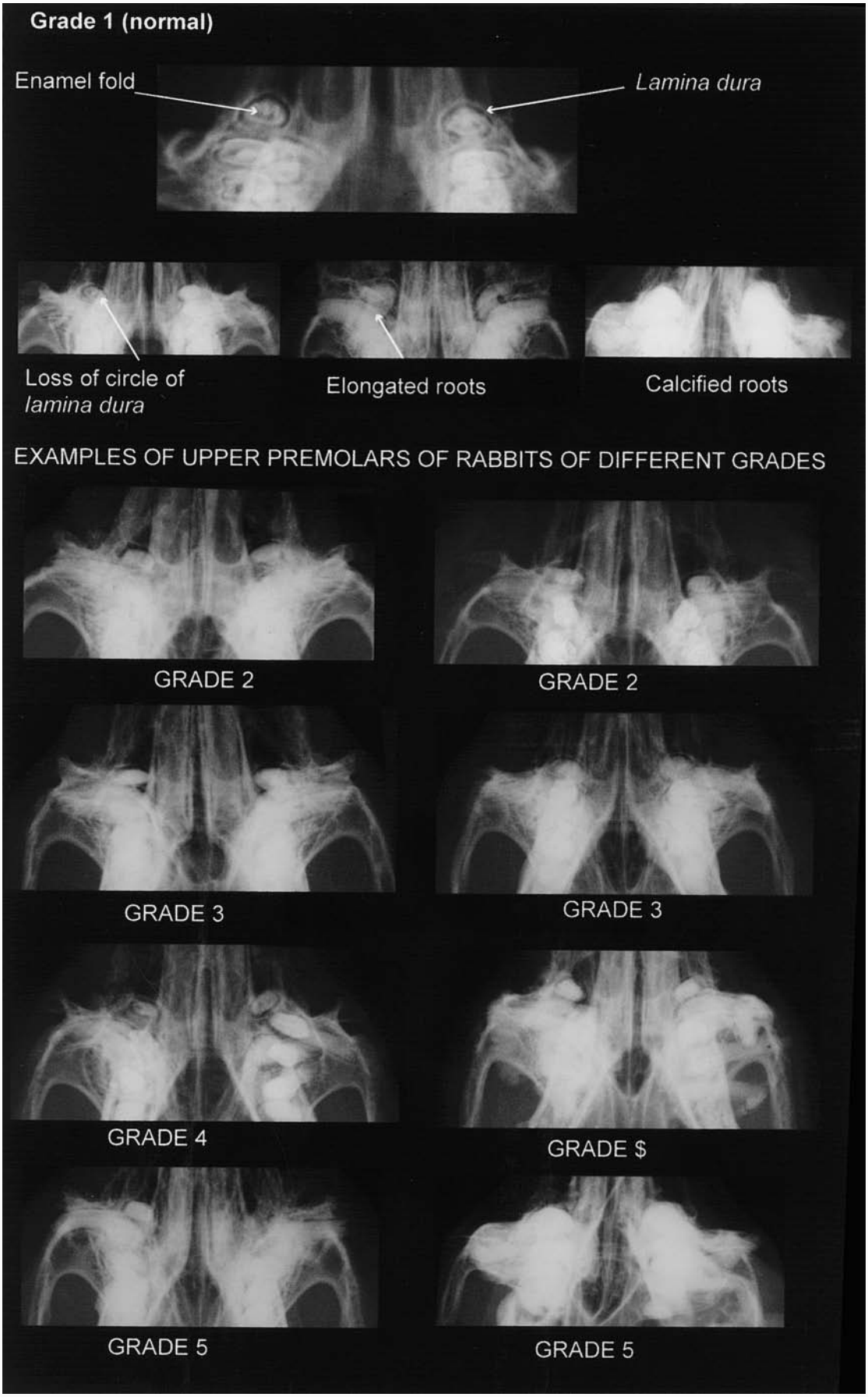

i) Periapical abscesses

Many radiographs showed evidence of periapical abscesses (Figure 50). This was to be expected as one of the main indications for skull radiography is as part of the diagnostic workup of facial abscesses. Out of the 315 rabbits that were radiographed, 55 had periapical abscesses. The diagnosis of abscessation for these cases was confirmed either during surgery or at *post-mortem* examination. Shortening teeth with clippers is cited as a cause of periapical abscess in rabbits so the case records of these rabbits were examined for details of dental treatment (Table 1).

Table 1: History of dental treatment of rabbits with periapical abscesses

Number of rabbits with a history of trimming molars with long handled clippers	5
Number of rabbits with history of burring molars	7
Number of rabbits with unknown history of dental treatment	17
Number of rabbits that had no history of previous dental treatment	26
TOTAL	55

Graph 27 shows that the incidence of abscesses increased as dental disease advanced. Periapical abscesses involving the lower cheek teeth were more common than those involving upper cheek teeth. The lower first, second and fourth cheek teeth molar were the teeth that were most commonly involved. Radiographic evidence of osteomyelitis involving the whole mandible was seen in rabbits with advanced dental disease (Grade 4 and 5). The results indicate that the incidence of periapical abscesses is linked with the severity of the changes that have occurred in the teeth and surrounding bone, rather than the method of tooth trimming.

Graph 27: Incidence and distribution of abscesses on lateral skull radiographs

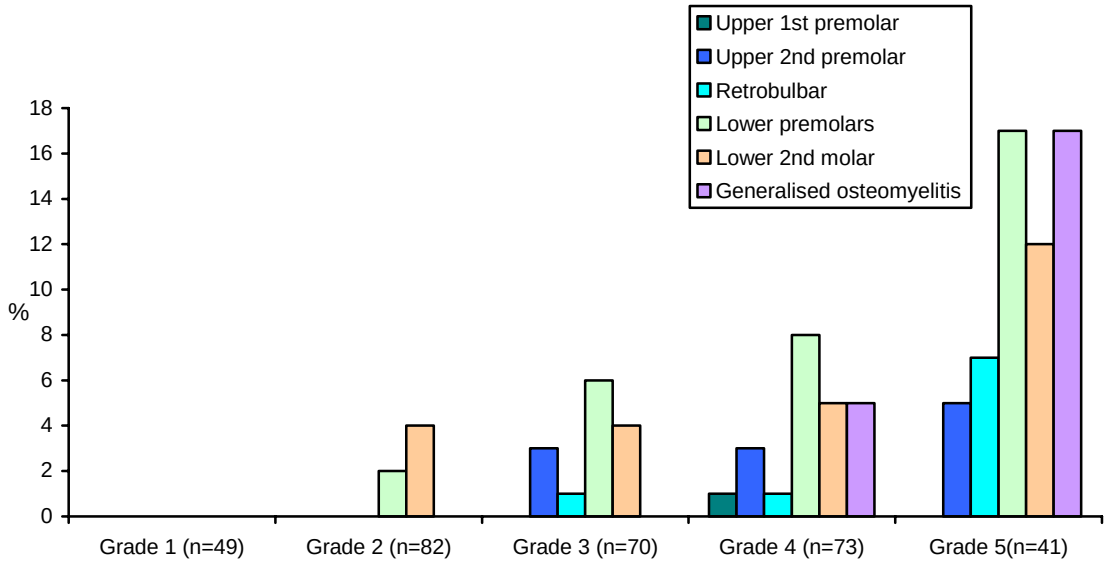

© Frances Harcourt-Brown 2006

Figure 50:
Radiographic appearance of abscesses

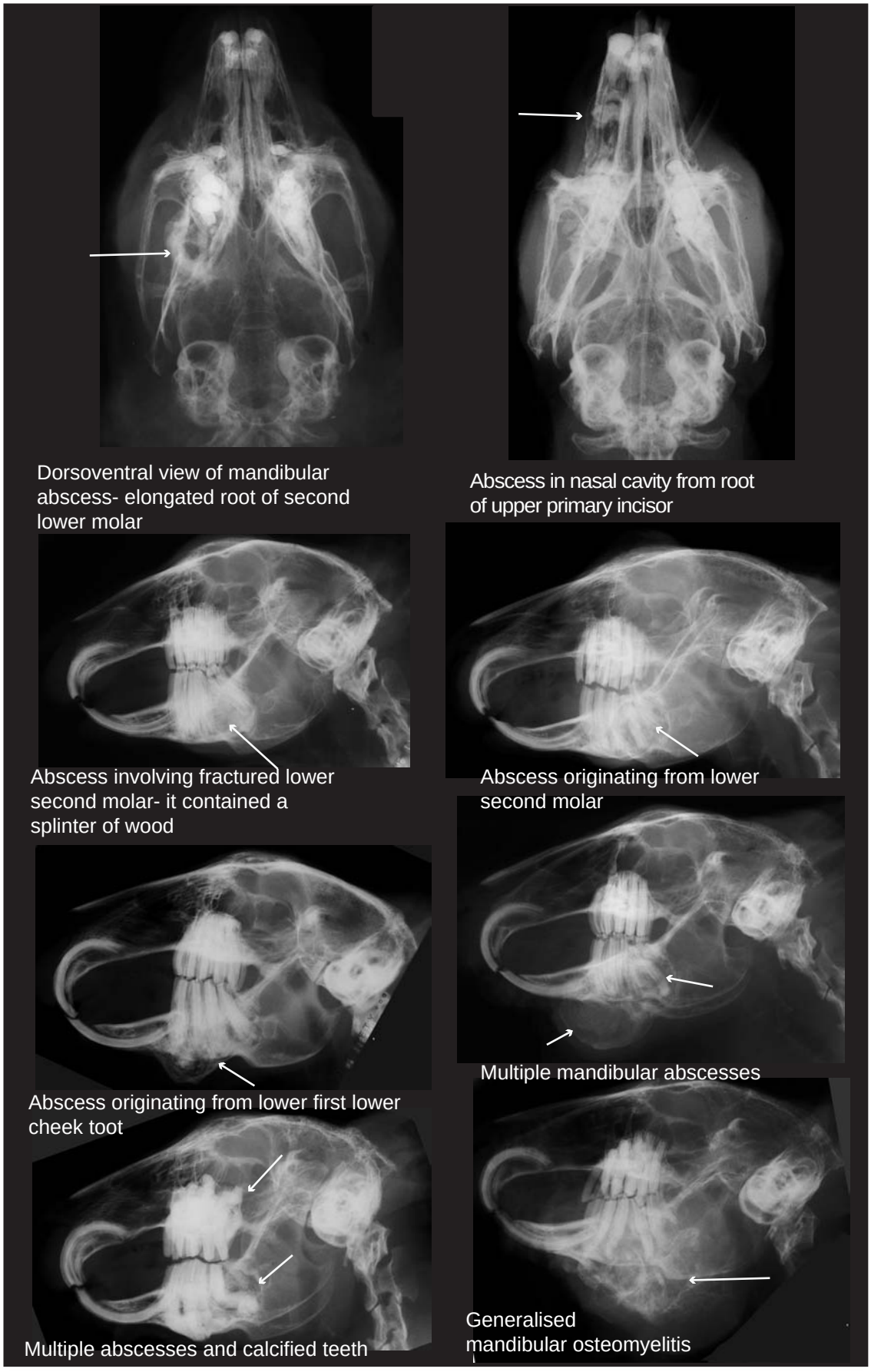

Section 3.6: Summary of results of the study of radiological features of skulls of rabbits with and without dental disease

Graph 28:
Radiological features of the skulls of 49 Grade 1 rabbits

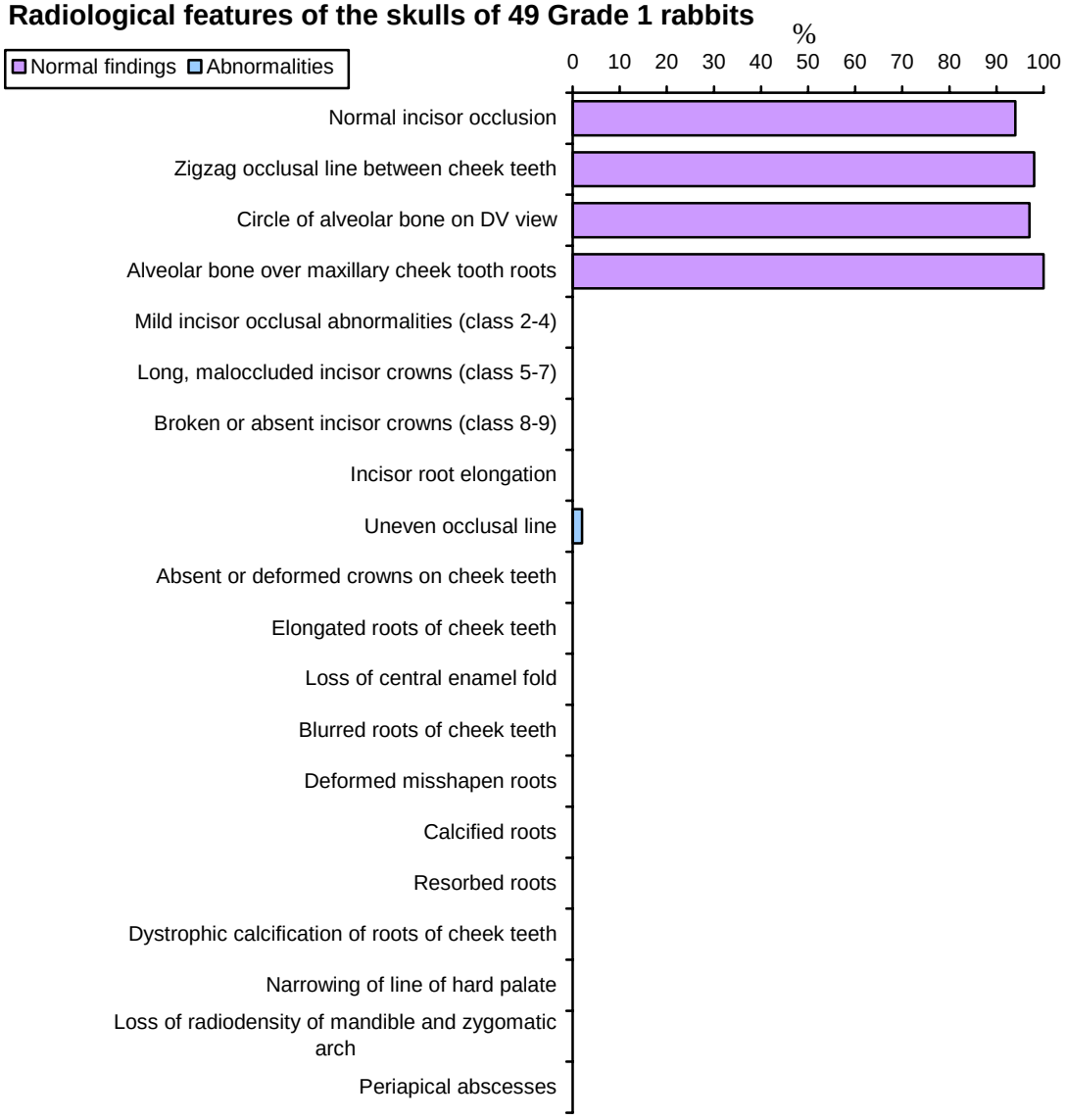

© Frances Harcourt-Brown 2006

Figure 51:
Examples of lateral views of skulls of wild and Grade 1 pet rabbits

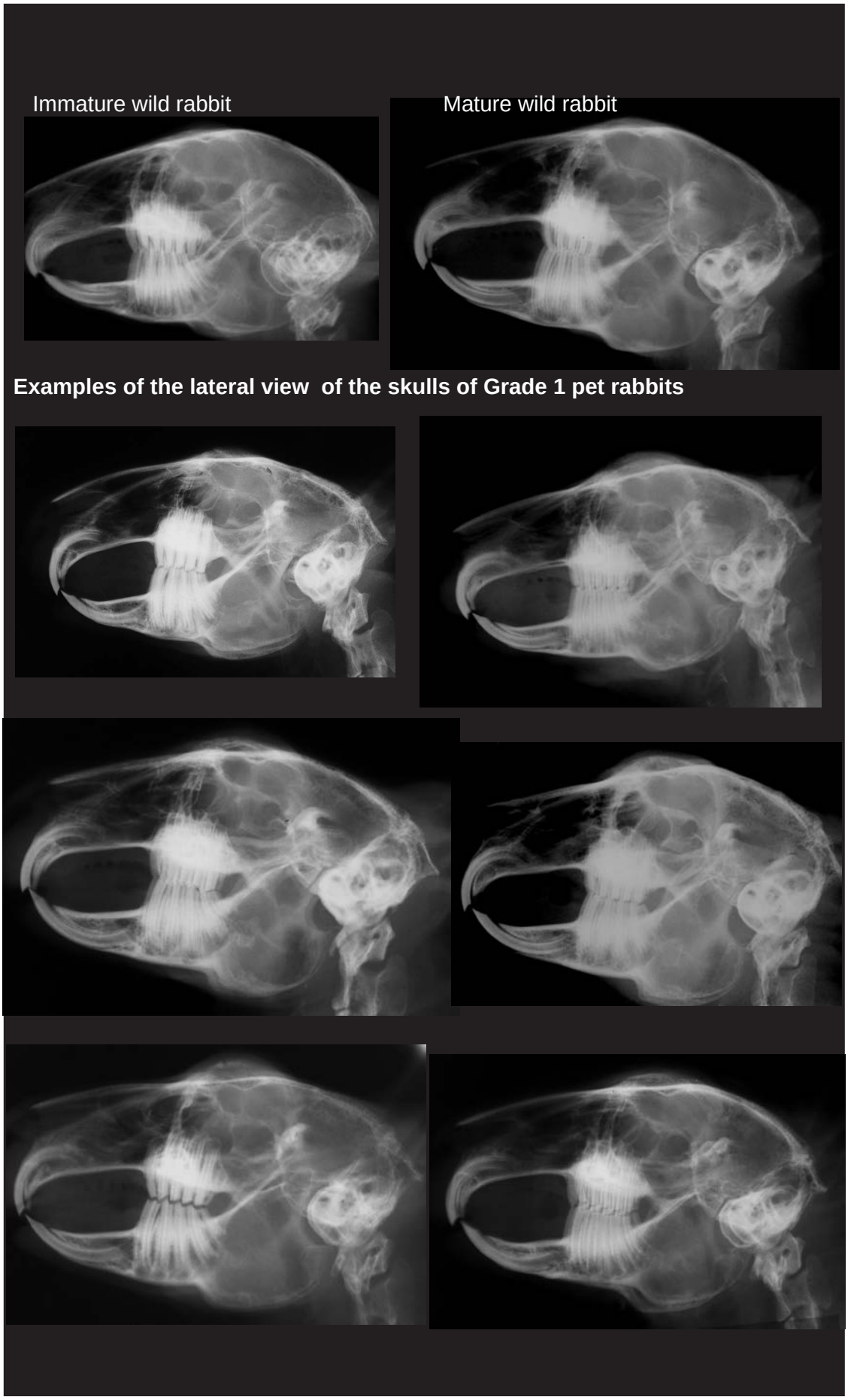

Graph 29:
Radiological features of the skulls of 82 Grade 2 rabbits

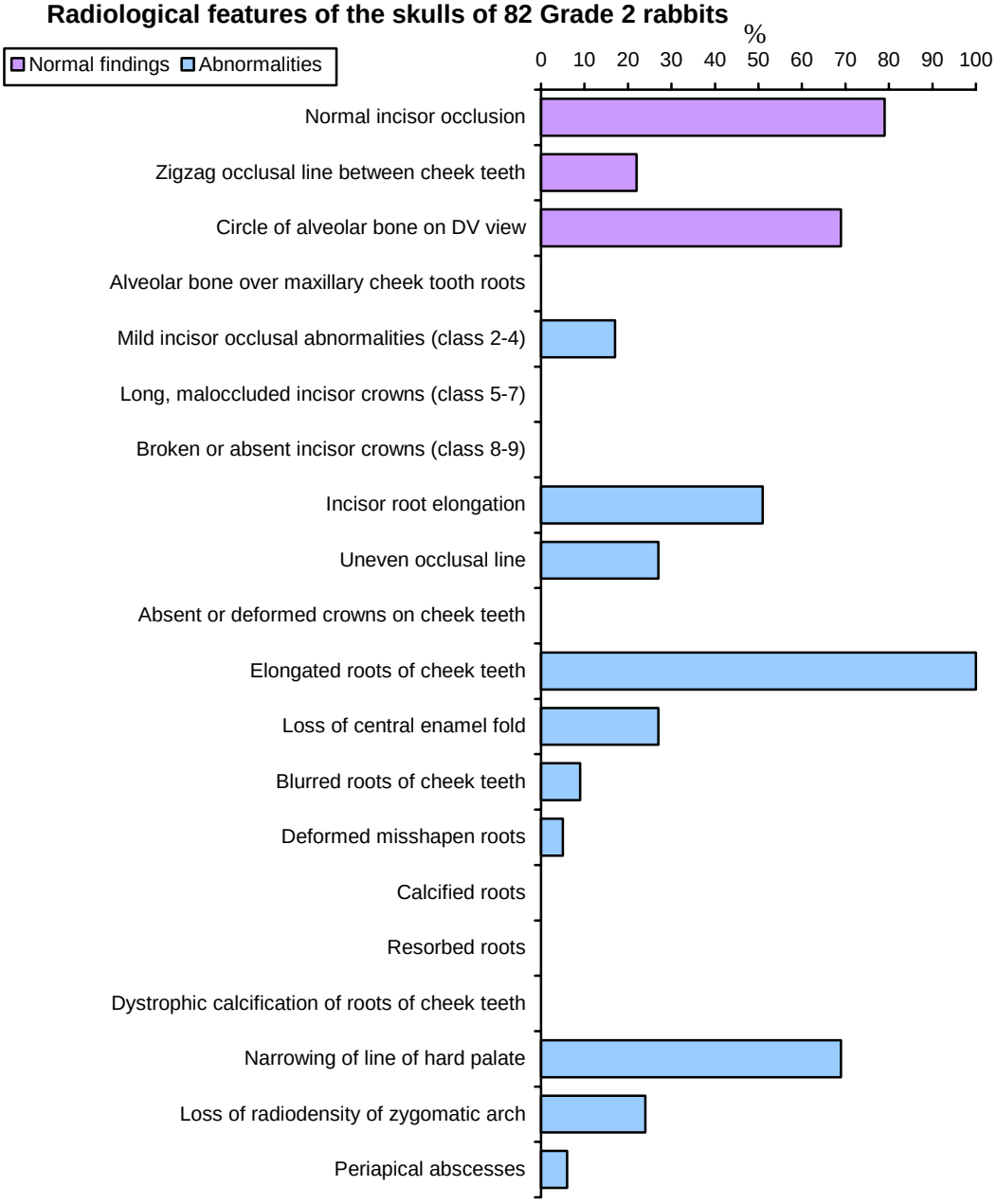

© Frances Harcourt-Brown 2006

Figure 52:
Examples of radiographs of skulls of Grade 2 pet rabbits

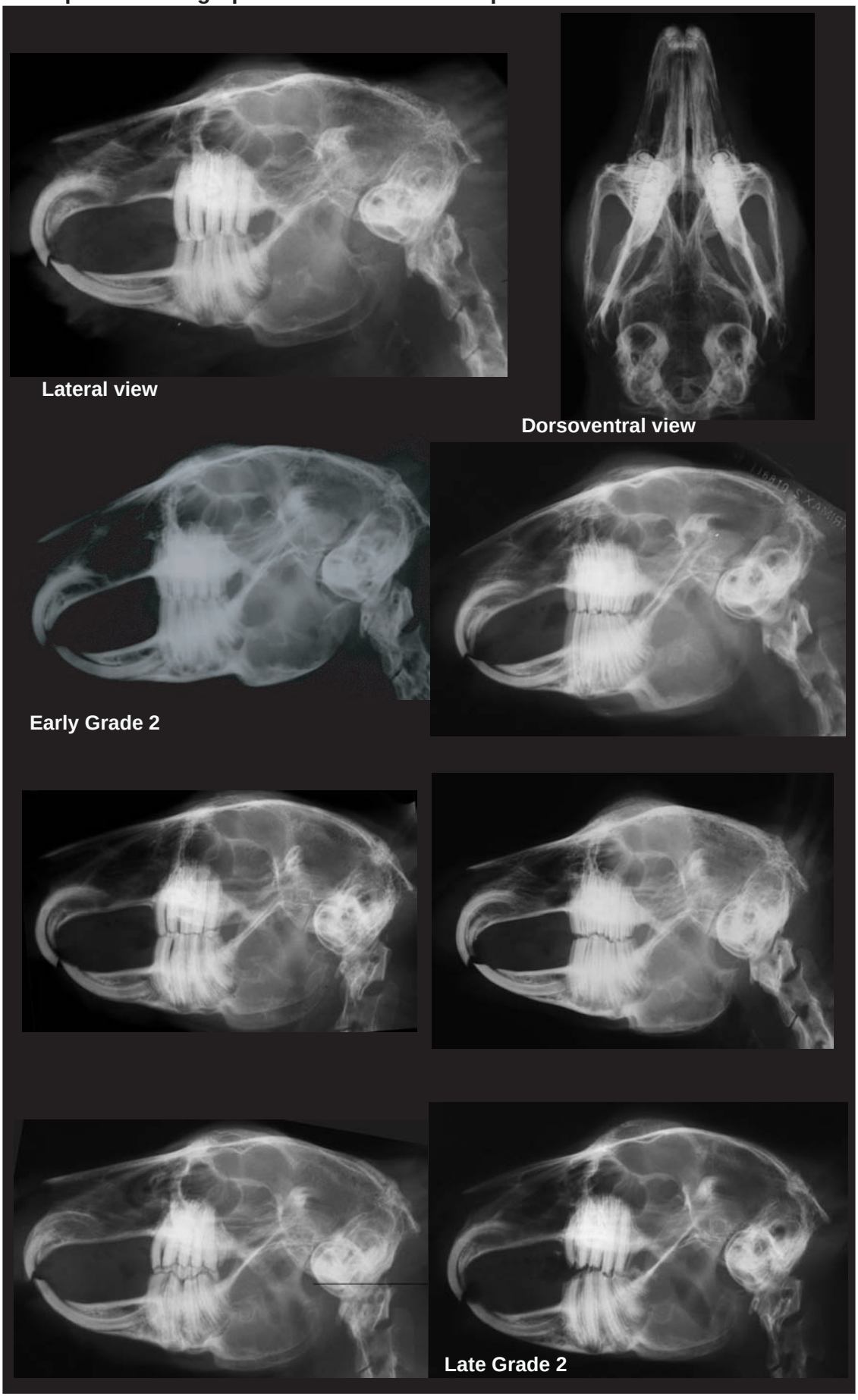

Graph 30:
Radiological features of the skulls of 70 Grade 3 rabbits

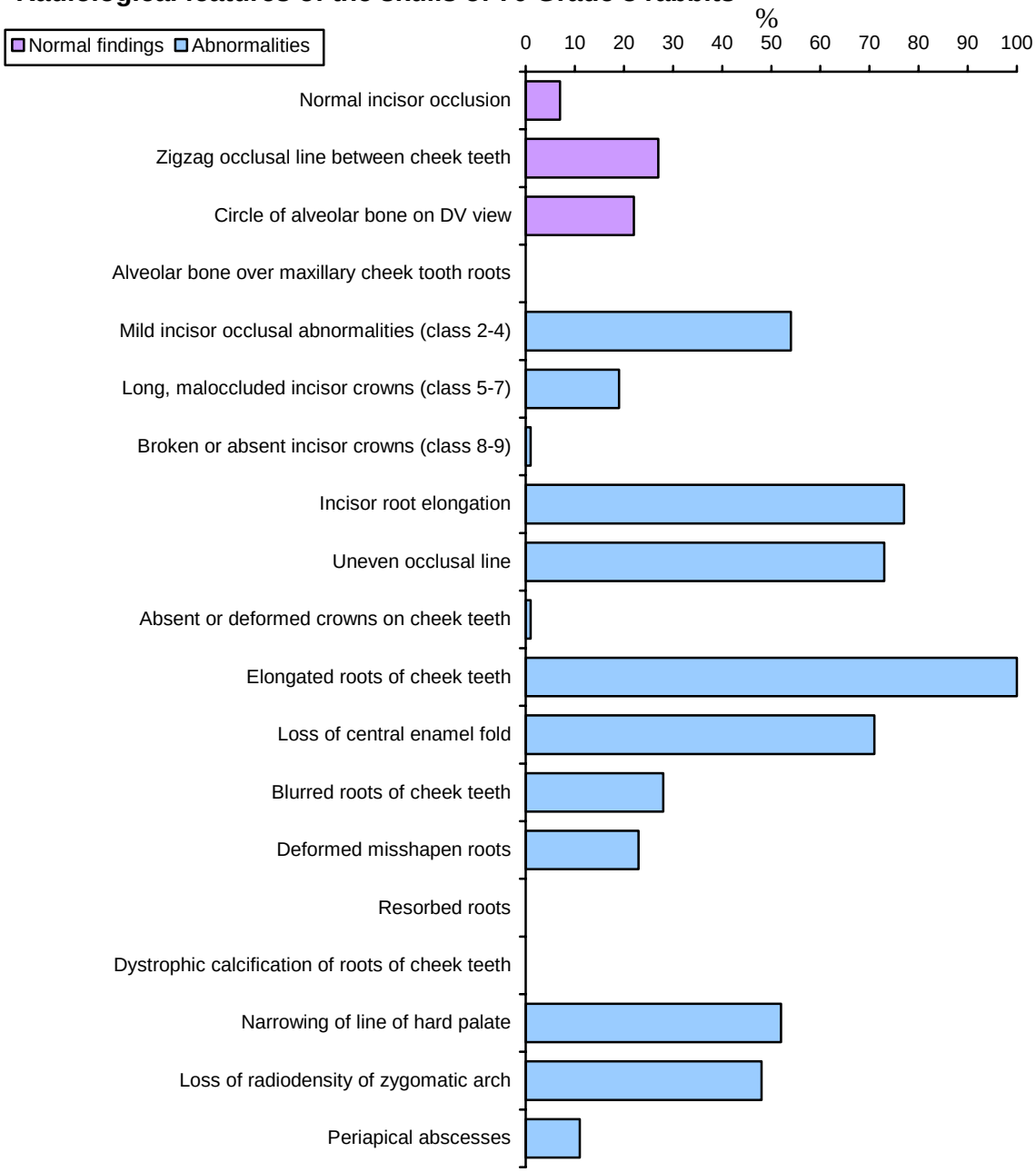

© Frances Harcourt-Brown 2006

Figure 53:
Examples of lateral views of skulls of Grade 3 rabbits
ACQUIRED MALOCCLUSION

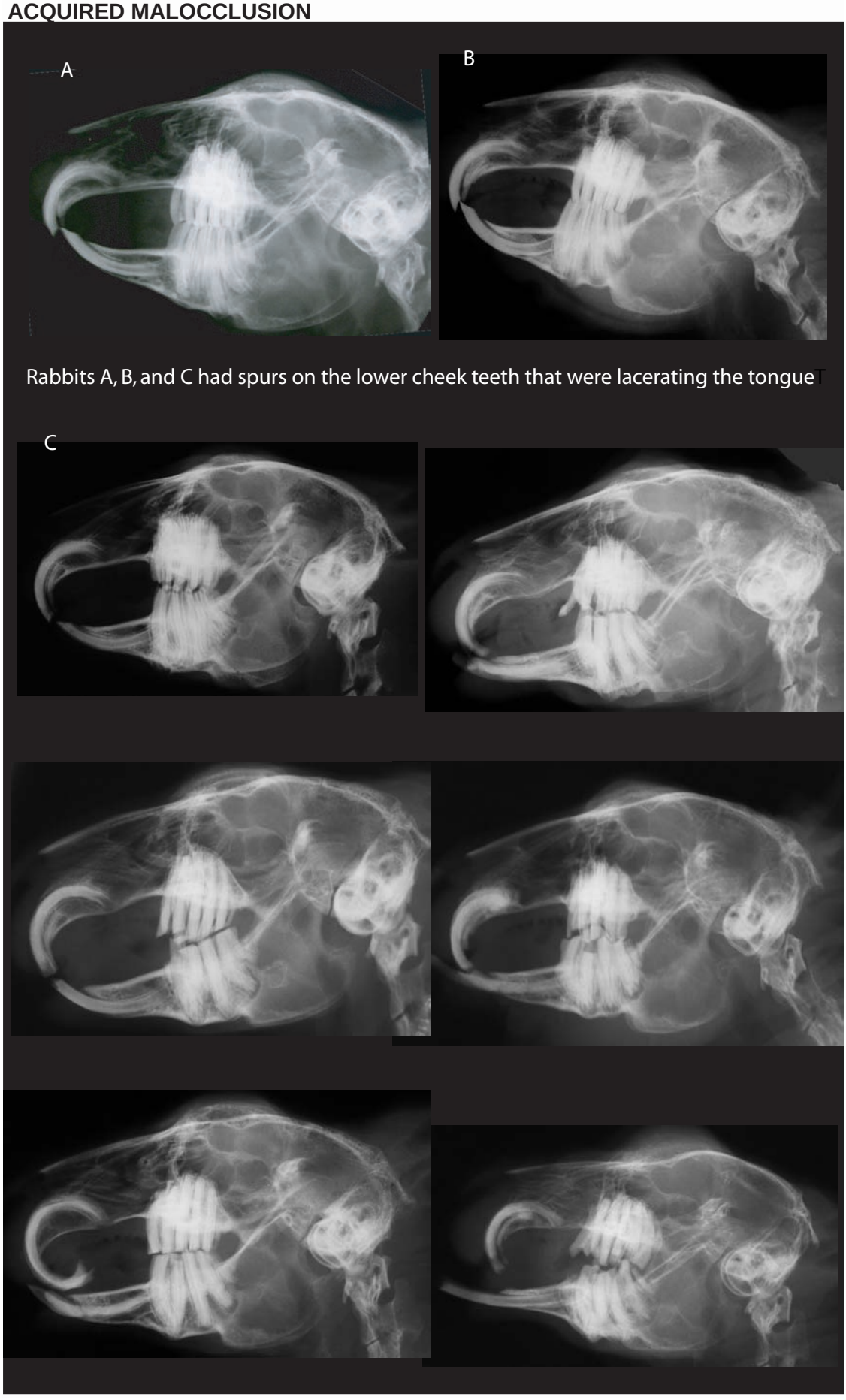

Graph 31:
Radiological features of the skulls of 73 Grade 4 rabbits

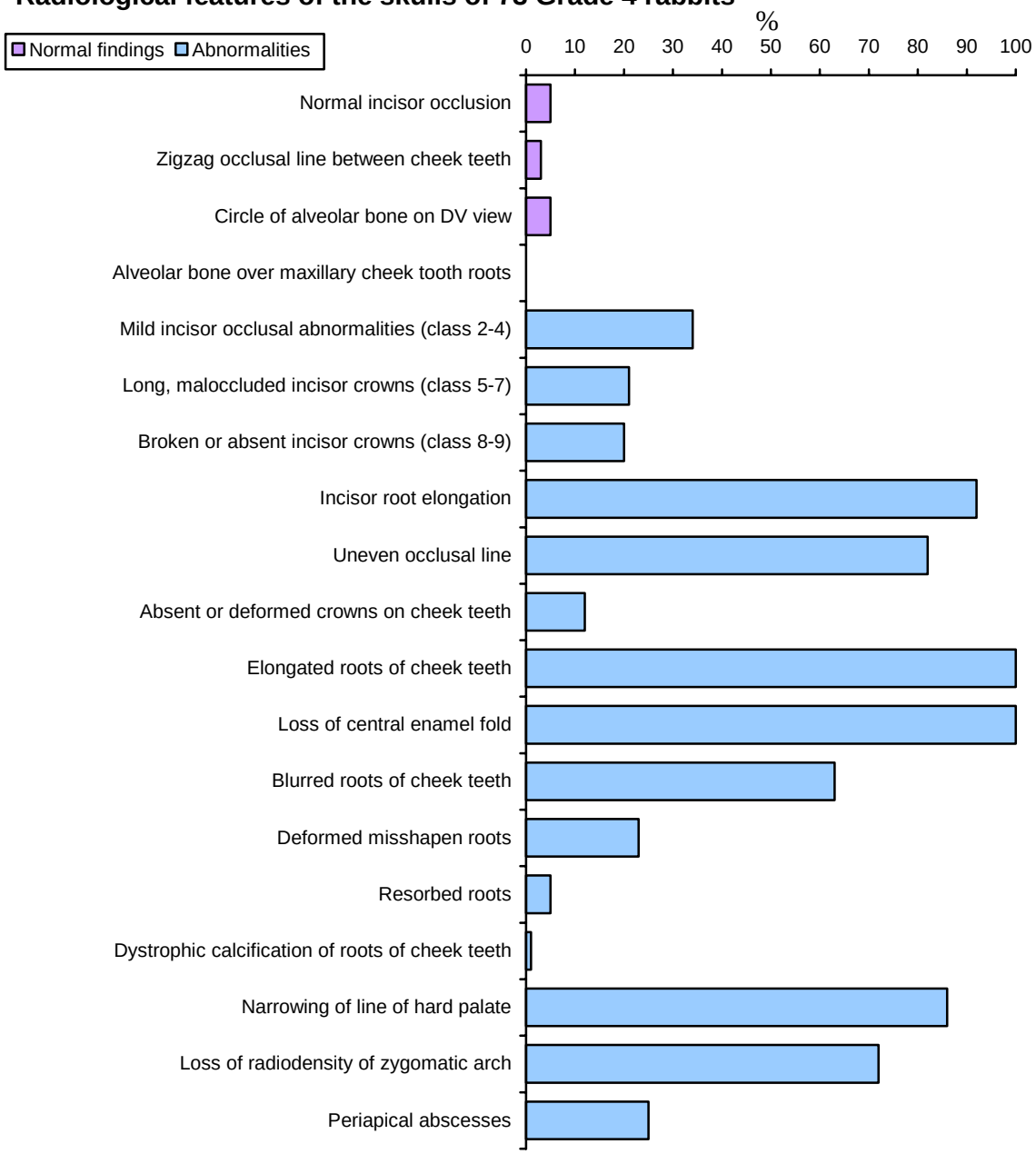

© Frances Harcourt-Brown 2006

Figure 54:
Examples of lateral and dorsoventral views of skulls of Grade 4 pet rabbits
CESSATION OF TOOTH GROWTH



Graph 32:
Radiological features of 41 skulls of Grade 5 rabbits

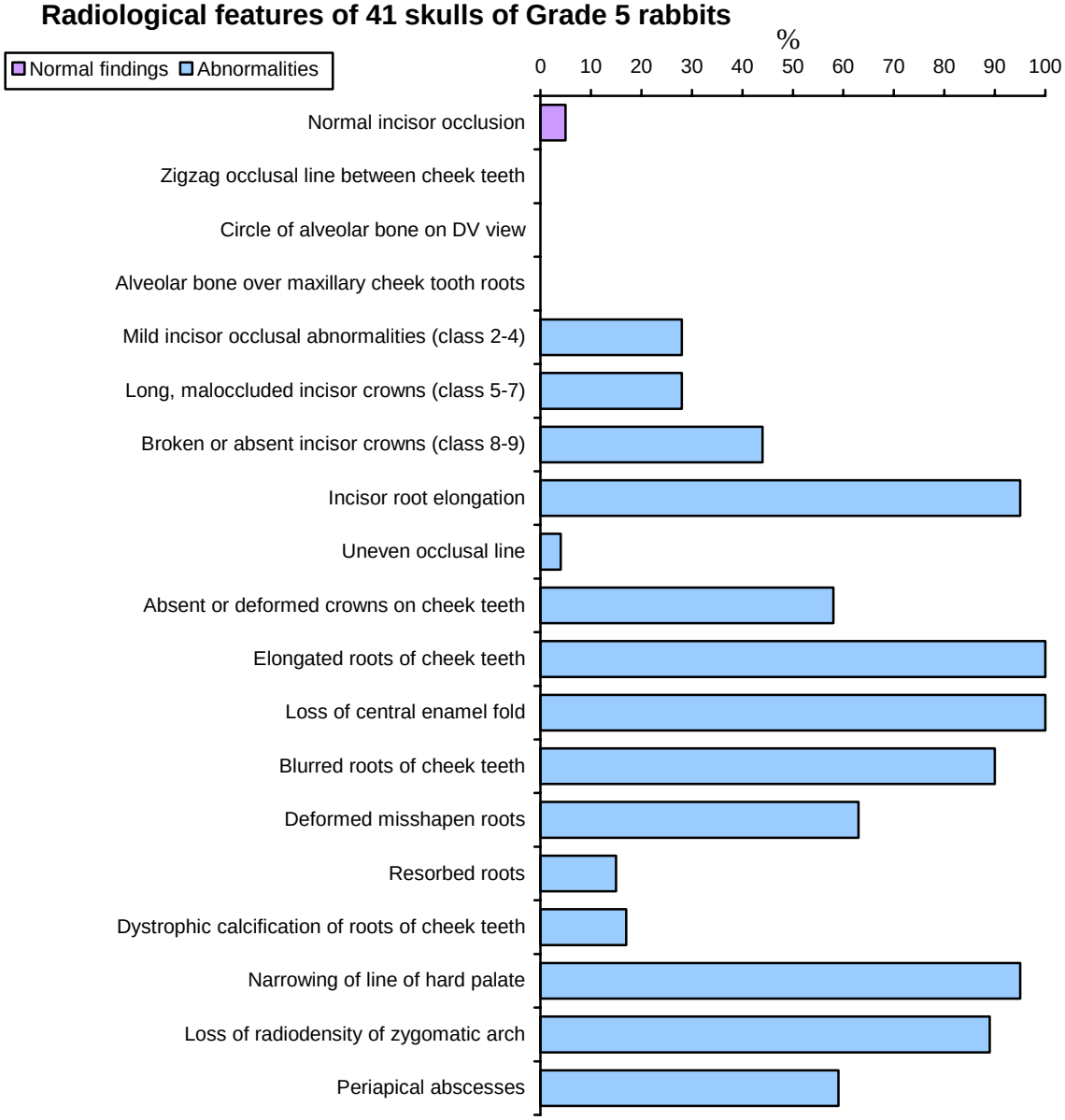

© Frances Harcourt-Brown 2006

Figure 55:
Examples of lateral views of skulls of Grade 5 pet rabbits
ENDSTAGE DENTAL DISEASE

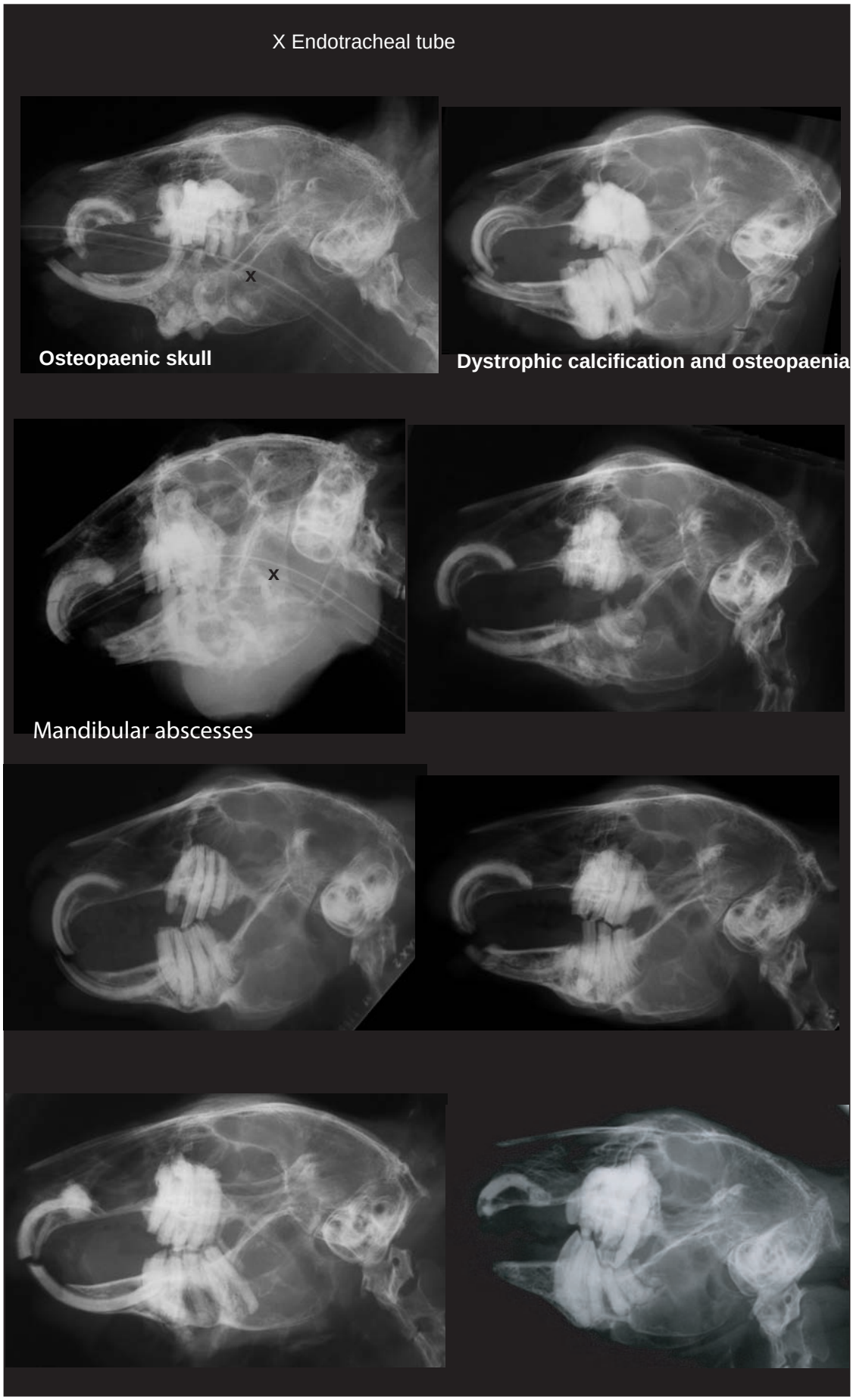

Section 3.7: Results of the comparative radiological study of the vertebral column of rabbits with and without dental disease

Whole body radiographs of rabbits of each grade of dental disease were examined for differences in the appearance of the lumbar vertebrae. The lumbar section of the vertebral column was chosen as a site for comparison as it the place that shows most bone mineral density loss in laboratory investigations of osteoporosis in rabbits.

The main radiographic feature of osteopaenia is described by Dennis (1989) as:

- Loss of radiodensity
- The bones appear 'ghost-like' with wide medullary cavities and thin shell-like cortices
- The vertebral endplates are relatively spared producing marked contrast with the osteopaenic spinous processes, neural arches and vertebral bodies.

These features were looked for on lateral views of the lumbar vertebrae and could be identified on many of the radiographs, especially of those rabbits with advanced dental disease. But there were so many variables that it was difficult to draw any definite conclusions. Variables included X-ray exposure, weight, size, age and activity of the animal.

Examples of the radiographic appearance of lumbar vertebrae are shown in Figure 56.This illustration demonstrates the difficulty in reproducing the original radiographic images. Fine detail is lost during scanning and printing. Despite manipulation of the images to highlight any changes, they were much clearer on the original radiographs.

© Frances Harcourt-Brown 2006

Figure 56:
Examples of lumbar vertebrae of rabbits with and without dental disease

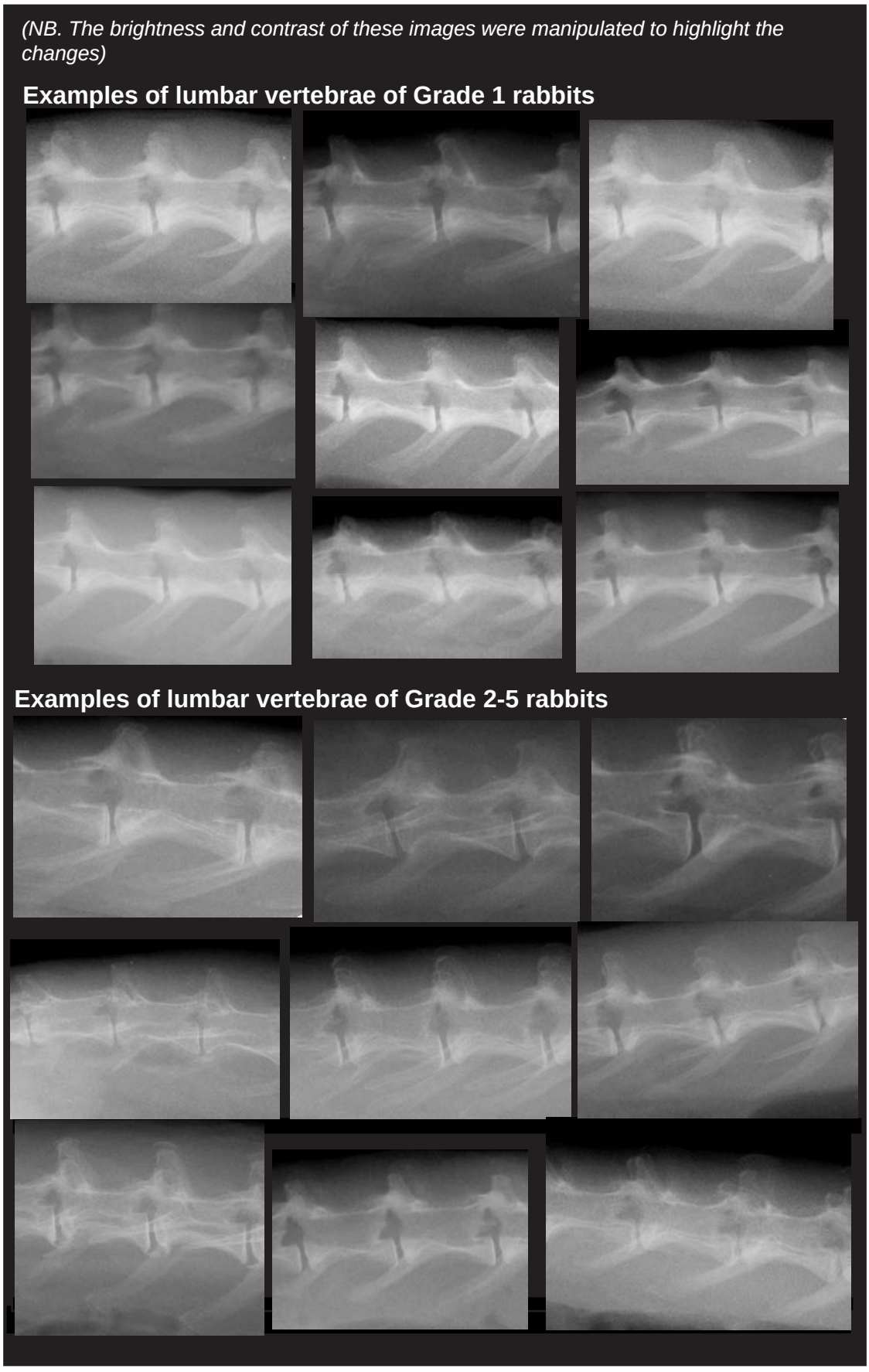

Section 3.8: Results of data analysis of rabbits presented for veterinary treatment

Comparison of gender and breed of 1254 rabbits presented for veterinary treatment.

Gender and breed details of 1254 rabbits presented veterinary treatment were statistically analysed. The rabbits were divided into two groups: (a) those requiring dental treatment and (b) those not requiring dental treatment. The data are presented in Appendices 2.6.

Breed distribution of 1254 rabbits

Not all rabbits were identified as a particular breed. Some were defined as mixed or unknown breed (236 rabbits [19%]). Of the breeds that could be identified, the Dwarf lop was by far the most popular (437 [35%]rabbits), followed by English (133 [11%] rabbits), Netherland Dwarf (114 [9%] rabbits), Dutch (102 [8%]) rabbits and Minilop (61 [5%]) rabbits. Other breeds were represented by smaller numbers of rabbits (Graph 29).

Graph 33: Breed distribution of 1254 rabbits presented for veterinary treatment

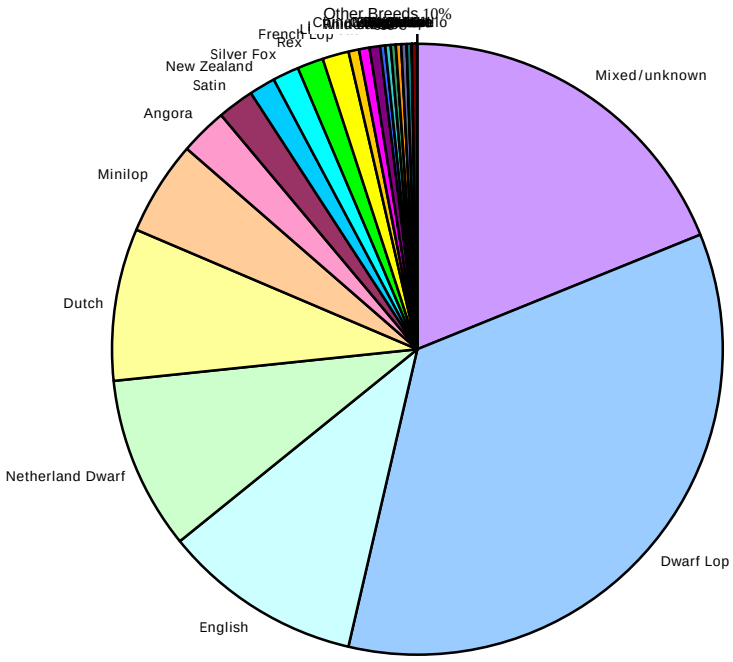

© Frances Harcourt-Brown 2006

Comparison of breeds treated for dental disease and not treated for dental disease

A total of 465 out of 1254 rabbits (37%) received treatment for dental disease. A comparison of the breed distribution of rabbits that were treated for dental disease and those that were not treated for dental disease is shown in Graphs 33. Statistical analysis using Chi Square test showed no significant relationship between breed and treatment for dental disease, although there was a trend towards a greater prevalence of Dwarf Lops and Dutch rabbits in the group requiring treatment for dental disease

Graph 34a: Breed distribution of 465/1254 rabbits requiring dental treatment

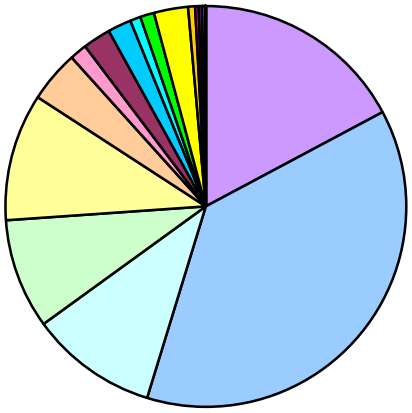

Graph 34b: Breed distribution of 789/1254 rabbits not requiring dental treatment

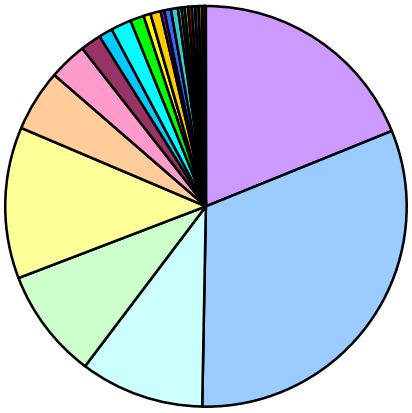

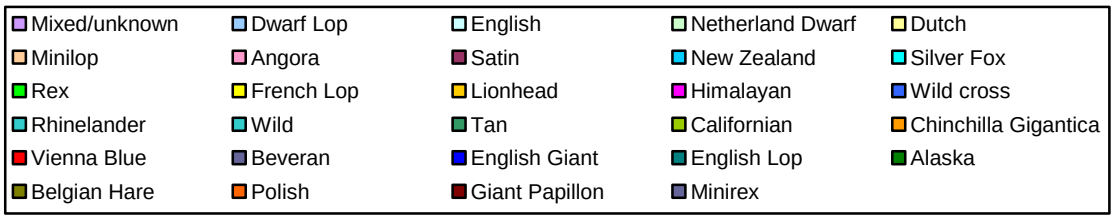

© Frances Harcourt-Brown 2006

Dwarf breeds are reputed to be more prone to dental disease so a comparison of Dwarf breeds (Netherland Dwarf, Dwarf Lop and Minilop) with non-Dwarf breeds was made. Statistical analysis using Chi Square test showed no significant relationship between Dwarf breeds and treatment for dental disease. See Graph 34.

Graph 35: Comparison of incidence of rabbits treated for dental disease in Dwarf and non-Dwarf breeds

Statistical analysis using Chi Square test shows no significant relationship between Dwarf breeds and dental disease

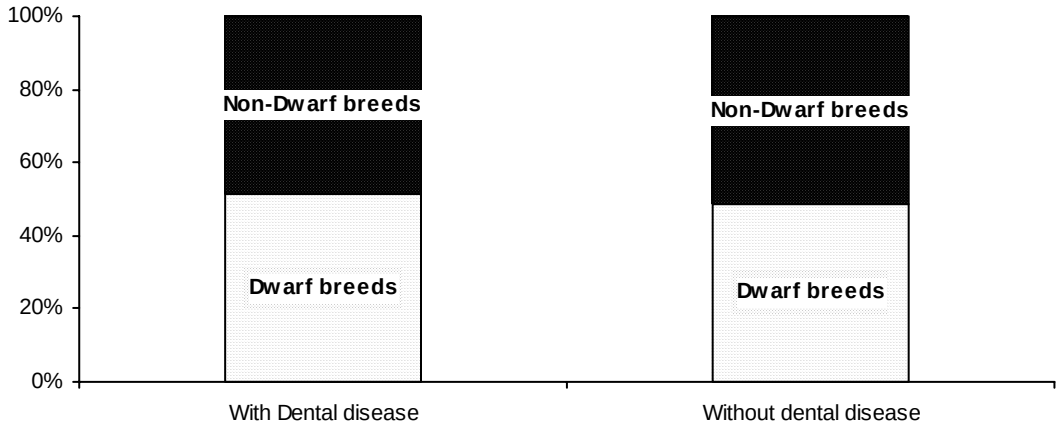

Breakdown of the breed incidence in the five most popular breeds of pet rabbit showed that breeds with a head shape similar to wild rabbits (Dutch or English) were as likely to be treated for dental disease as those breeds with a short maxilla (Dwarf Lop or Netherland Dwarf) (Graph 35).

Graph 36: Relative proportions of rabbits of five most popular breeds with and without dental disease

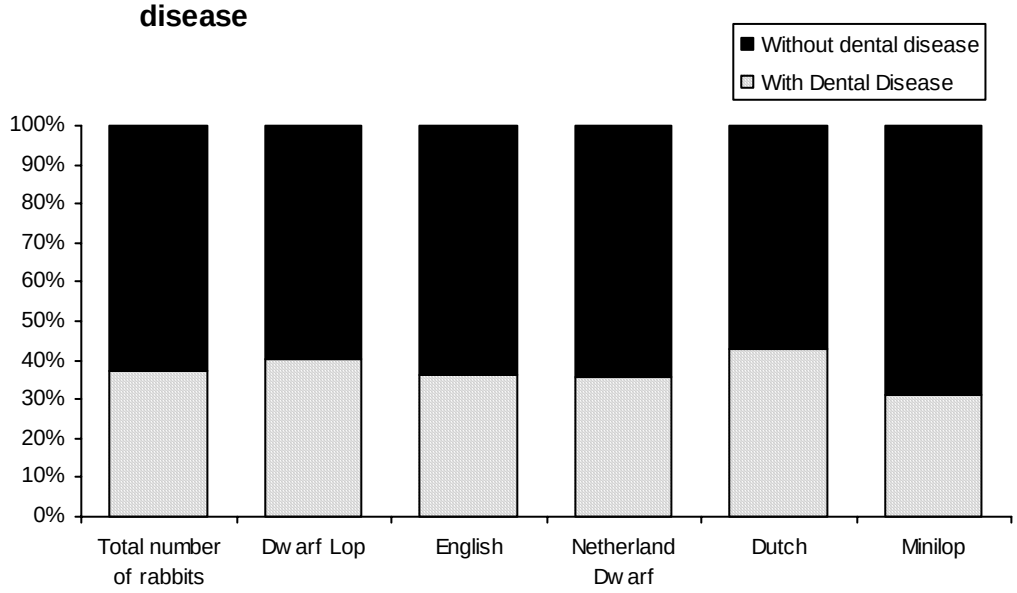

© Frances Harcourt-Brown 2006

Gender of rabbits with and without dental disease

The gender of rabbits treated and not treated for dental disease is given in Table 2. Statistical analysis showed a strong link between gender and dental disease. Males were more susceptible (see Graph 33)

Table 2: Gender of rabbits with and without dental disease

	Male	Female	Total
With dental disease	322	143	465
Without dental disease	396	393	789
Total	718	536	1254

Graph 37: Gender distribution of rabbits with and without dental disease

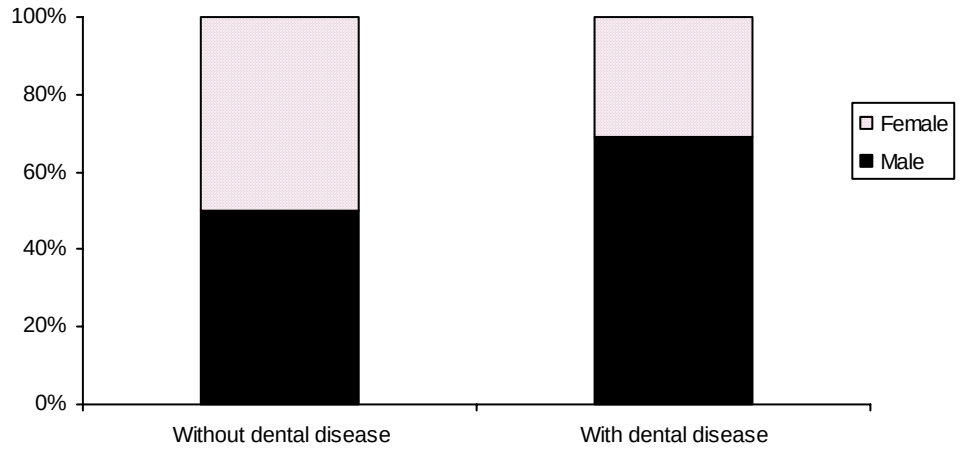

Statistical analysis using the Chi square test shows significantly more male rabbits than female rabbits suffered from dental disease ($p<0.001$).

© Frances Harcourt-Brown 2006

Section 3.9: Results of examination of skulls at Natural History Museum

In total, 337 skulls were examined at the Natural History Museum. The skulls had been prepared by a variety of methods, including weathering, burial, flesh removal by *Dermestid* spp beetles, maceration and stewing. These methods did not include routine degreasing. A few skulls had been treated with peroxide although this is now considered unacceptable because it damages DNA. The method of preparation for each individual skull was not recorded and it was not possible for the curator to say how a skull had been prepared by looking at it. None of the 337 skulls showed the thin bone that is evident in pet rabbit suffering from PSADD.

A detailed examination of 100 complete skulls from wild rabbits was conducted. These skulls originated in Spain and the Balearic Islands, Tunisia, Egypt, Algeria, all parts of Great Britain, Jersey, Chile and other parts of South America, Germany and France. The results are as follows:

- None of the skulls showed abnormalities of the exposed crowns of the teeth such as curvature, misalignment or defects such as horizontal ribs on the upper first incisors.
- Only one skull showed evidence of bone penetration by the roots of the cheek teeth. This was at the apex of the root of an upper second premolar. The roots of the other teeth had not penetrated the bone
- 98/100 skulls showed Class 1 incisor occlusion. The remaining 2 showed Class 2 with the tips of the lower incisors in occlusion with the upper first incisor. This was evident from the wear facet of the upper first incisors
- 37/100 skulls either had glue in the sockets or had skins in the collection, suggesting the skulls had been prepared at the Museum. In these cases, the teeth would have been repositioned in the sockets so they might not occupy the exact position they were in during life.
- 49/100 skulls could be positioned with the cheek teeth and incisors in occlusion at the same time.
- All the skulls were opaque rather than transparent. Their colour varied from white to yellow, cream, orange or brown. Seven skulls looked oily.
- 53/100 skulls had a spongy, osteoporotic appearance of the parietal bone. 75/100 skulls had a hole in the ramus of the mandible near the angular process.
- No skulls showed evidence of abscesses.
- Asymmetry of the foramen magnum was seen in 7/100 skulls. A further 6/100 skulls showed two or more holes at the site of the optic foramen.

Examples of skulls from the collection at the Natural History Museum are shown in Figure 57.

© Frances Harcourt-Brown 2006

Figure 57:
Examples of skulls held at Natural History Museum



CHAPTER 4: DISCUSSION

Dental disease is a major cause of health problems in the pet rabbit population. This was exemplified in the data analysis part of this thesis. Thirty seven percent of rabbits presented to the authors practice between 1998 and 2002 required dental treatment.

Cause of dental disease in pet rabbits

There are a number of potential causes of dental disease in pet rabbits. Breeders attribute dental problems to 'bad breeding', faulty diet, sudden changes in food, lack of sunlight or cold and damp hutches (Pollock, 1951, Sandford, 1996). But, despite these explanations, the exact aetiopathogenesis remains unclear.

Odontodystrophies caused by nutritional, metabolic or toxic insults, such as fluoride poisoning, are described as causes of acquired dental disease in several species. These are reviewed by Jubb and others (1985a). Vitamin A deficiency can affect the differentiation and organising ability of ameloblasts, which results in enamel hypoplasia and hypomineralisation, cellular vascularised dentine and retarded or obviated eruption. This is reported in other species but not rabbits.Viral infections, such as distemper in dogs, can cause hypoplastic enamel. But, few viral infections affect pet rabbits. Myxomatosis and viral haemorrhagic disease (VHD) are the most common. Neither is reported to cause dental abnormalities. They are usually fatal.

Developmental defects, such as missing teeth, occur in rabbits. Absent secondary upper incisors or lower molars were incidental findings on the radiographs that were examined for this thesis (Figure 21). Prognathism is a recognised cause of dental disease. In *The Biology of the Laboratory Rabbit, 2nd Edition* (1994) Lindsey and Fox cite mandibular prognathism as the cause of incisor malocclusion and describe it as "*the most common of the known inherited diseases in the rabbit, as few laboratory or commercial breeding stocks are free of the problem*". In the literature, there are several descriptions of prognathism affecting rabbits (Huang 1987, Chai, 1970, Fox and Crary 1971, Goto and others 1987). In veterinary practice, prognathism is sporadically seen in pet rabbits, usually Dwarf breeds that present with incisor malocclusion at an early age (under 6 months).

Neoplasia or traumatic skull injuries can displace teeth and cause malocclusion in pet rabbits (Figure 21) but these cases are rare in comparison with the progressive, acquired syndrome of dental disease (PSADD) that is described in this thesis. The cause of this syndrome is unclear and controversial. In the literature relating to laboratory rabbits, apart from incisor malocclusion due to prognathism, there are few case reports of dental problems (Ireson 1968, Zeman and Fielder 1968). Root elongation is a characteristic feature of PSADD yet this is scarcely reported in laboratory rabbits. A paper by Weisbroth and Ehrman (1967) recognised that ectopic tooth roots could penetrate the bones of the skull of laboratory rabbits and result in abscessation. The authors made a request for *'reasons, suggestions or comments by interested persons'* on the development, pathology and inheritance of malocclusion in rabbits. In 1969, Zeman and Fielder wrote '*the nature of premolar and molar malocclusion seems to defy at this time any positive determination of the cause*'.

Several authors offer explanations for the prevalence of dental problems in pet rabbits. Most are vague and none have evidence to support them. For example, cheek tooth malocclusion is attributed to abnormal wear caused by incisor malocclusion (Jenkins, 1997) or diseases of the temporomandibular joint (Wiggs and Lobprise, 1995). Brown (1992) cites inflammation of the molar roots as a cause of primary molar malocclusion, leading to secondary incisor malocclusion.

© Frances Harcourt-Brown 2006

Jenkins (1997) also suggests aging as a cause of acquired dental disease in rabbits. This is logical, because the teeth of other herbivores, such as cattle and horses, deteriorate with age. But these species have fully formed teeth that continue to erupt, but not grow, through life. Their teeth change in shape and length with age. The teeth of lagomorphs continue to both erupt and grow through life, so the comparison with other herbivores is not valid. Most rabbits do not live long enough to show age changes in their dentition although the author has owned six rabbits that survived until their tenth year without visible or radiological changes in their dentition. An example is shown in Figure 27.

Currently, the most popular and plausible theories for the cause of dental disease in pet rabbits are: (i) lack of abrasive food (ii) genetic predisposition or (iii) underlying metabolic bone disease due to calcium and/or vitamin D deficiency.

(i) Lack of abrasive food

Lack of hard or abrasive food and reduced dental wear is often cited as a cause of overgrown teeth and malocclusion in pet rabbits (Westerhof and Lumeij, 1987). Many handbooks and leaflets on the care of pet rabbits suggest that twigs and branches should be given for rabbits to gnaw on to wear their teeth down although there is little published evidence that this is necessary. There is a study by Bucher (1994) who investigated the relationship between hardness of food and dental wear. Twenty four rabbits were divided into 6 groups that were fed on: 1) pellets only, 2) mixed rations only, 3) mixed rations and hay, 4) mixed rations and wood for gnawing, 5) mixed rations and limestone or 6) pellets plus green forage. The length of the investigation was eight months and the rates of growth and attrition of the incisors were measured by marking the incisors. At the end of the investigation, the author concluded that genetic influences and the level and method of feed intake have more influence on dental growth and wear than the hardness of the food.

An indication that lack of abrasive food might not cause dental problems in rabbits is the dearth of reports in the scientific literature. Laboratory and commercial rabbits are often fed on a complete pelleted ration and nothing else. This diet is not abrasive, yet tooth elongation is scarcely reported despite the many million laboratory rabbits that are studied worldwide. There is even evidence that a fibrous diet is not necessary to prevent malocclusion. A group of laboratory rabbits was maintained for a whole year on a complete liquid diet without any mention of dental problems (Latour and others, 1998). Another group was maintained on a complete purified diet based on agar gel for up to two years with no gross or histopathological lesions attributable to nutritional disease being observed during autopsy (Hunt and Harrington, 1974).

A proposed mechanism for the development of malocclusion due to inadequate and abnormal tooth wear is described in many recent publications, i.e. chapters in textbooks, or conference proceedings, written by Crossley (Crossley and others 1998, Crossley 2000, Crossley 2000a, Crossley, 200b, Meredith and Crossley 2002, Crossley 2003a, Crossley 2003b). The proposed mechanism (Figure 58) is based on the premise that a force that impedes eruption of continually growing teeth will cause intrusion and root elongation. Intrusion, but not root elongation, has been demonstrated in laboratory studies (Terajima, 1989, Steedle and others 1983, Proffitt and Sellers, 1986). An example of Crossley's theory (Crossley, 2003a) is as follows: '*Rabbits who receive commercial foods are prone to inadequate and abnormal tooth wear. The affected teeth continue to erupt until pressure from contact with the opposing teeth at rest prevents further eruption; the force that is necessary is small. By this stage, the jaws have usually been pushed into the same alignment as seen when healthy rabbits have their mouths wide open, causing a secondary incisor malocclusion. Reduced eruption of continuously growing teeth causes changes in the apical germinal tissues; the tooth growth rate reduces to a minimum of about one eighth of normal and continues at this rate even when eruption ceases. Tooth curvature increases and adds to the tendency for incomplete attrition and the development of 'spikes'.*

© Frances Harcourt-Brown 2006

Figure 58: A proposed mechanism for the development of cheek teeth malocclusion due to lack of dental wear and abnormal chewing patterns

(Summary and diagrams abridged and redrawn from Meredith and Crossley (2002) and Crossley(2003a))

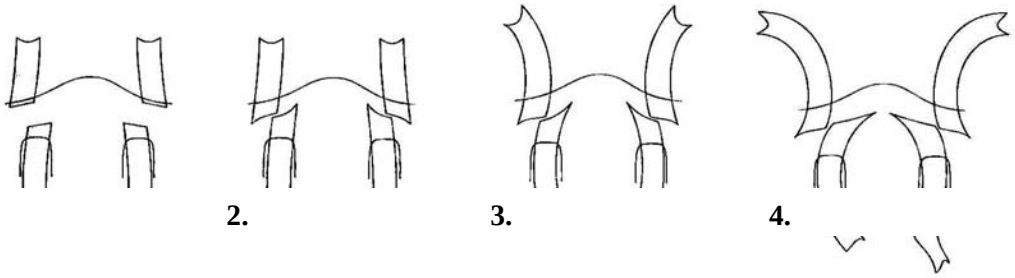

Proposed sequence of events:

1. *" Normal cheek teeth: chewing wears the whole occlusal surface evenly and rapidly, this being matched by tooth growth and eruption"*
2. "*Early elongation of the exposed crown: reduced attrition and uneven wear with continued growth and eruption elongate one side of the exposed crowns".* This leads to " *Altered occlusal contact; the chewing action changes altering the forc*es *applied to the teeth.*
3. *"Increased lateral and occlusally directed forces impede eruption affecting the germinal tissues resulting in increased curvature and, in extreme cases tipping of the teeth"*
4. *"Spikes form at the occlusal surfaces that interfere with chewing and further reduce attrition. Increased occlusal contact reduces eruption but tooth growth continues, resulting in root elongation and intrusion"*

In his hypothesis, Crossley makes the assumption that the cheek teeth are held out of occlusion at rest. But Crossley's description of the resting occlusal position of the jaws is open to question. He describes the resting position of the jaws as follows; '*When resting, rabbits normally hold the mandible at or near the middle of its rostrocaudal movement range, with the tips of the mandibular incisor teeth positioned between the first and second maxillary incisors and with the midlines of the maxilla and mandible aligned. With the jaw in this position, the cheek teeth are held slightly apart, so there is no resistance to occlusal pressure'* (Crossley, 2003a). This description of resting occlusion is not in agreement with other authors who have conducted detailed anatomical and cinematoradiographic studies (Ardran and Kemp, 1958, Hirschfield and others, 1973, Weijs and Dantuma, 1981). Rather than anatomical dissections, Crossley illustrates his description of resting occlusion with computer generated diagrams or with photographs of a prepared skull from a wild rabbit. Skull preparation may account for the difference between Crossley's description and that of other authors. Teeth often fall out during skull preparation and it is difficult to replace them in the exact position they occupied during life. The position of the teeth may also change as the skulls dry out. A small difference (<1mm) in the position of the incisors completely alters their occlusal relationship (Figure 59). Detailed examination of 100 prepared skulls of wild rabbits at the Natural History Museum showed that approximately half the skulls could be positioned with the cheek teeth and incisors in occlusion at the same time (Figure 57) indicating that Crossleys' description of resting occlusion is incorrect.

Some other findings of this thesis also cast doubt on Crossley's hypothesis.:

1) According to Crossley's hypothesis, increased crown height leads to increased occlusal pressure between the upper and lower teeth, which supposedly causes intrusion and root elongation. The height of a crown is the distance between the gingival bone and the occlusal surface of the tooth. But, as illustrated in Figure 26, it is impossible to evaluate or measure crown length on the skulls or on radiographs. Crown elongation was not a feature of prepared skulls and radiographs of the skulls of rabbits with PSADD (Figures 29, 34-39, 51-55).

© Frances Harcourt-Brown 2006

Figure 59:
Differing descriptions of resting occlusion,

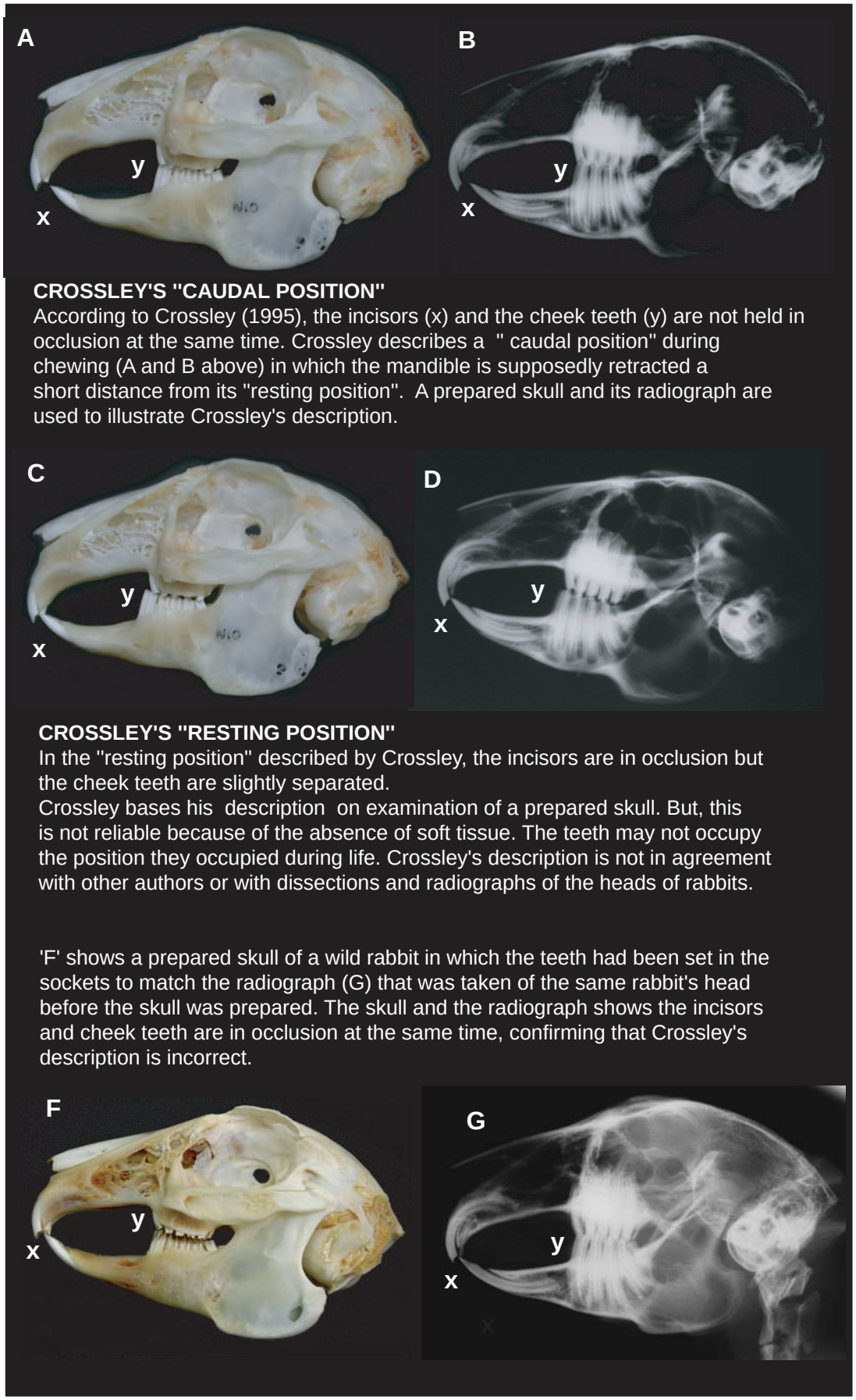

2) **All** the skull radiographs of rabbits with dental disease (Graph 22, Figures 51-55) showed elongation of the roots. In some Grade 2 rabbits, root elongation was the only abnormality that was evident, suggesting that it is the first change to take place in PSADD. But, according to Crossley's proposed mechanism for the development of malocclusion, root elongation should be a late change that follows abnormalities of the crowns (Figure 58, drawing 4.)

3) If root elongation is due to increased intraocclusal pressure, then it should not be evident on the upper first incisor that is not in occlusion with opposing teeth at rest. But, in this thesis, the upper first incisor was one of the teeth that most often showed root elongation both on the prepared skulls (Graph 6) and lateral skull radiographs (Graph 18, Figures 44 and 52).

4) In Crossley's hypothetical sequence of events , elongated crowns force the mouth open so the resting angle between the palate and the rostral mandible is no longer convergent (A) and becomes almost parallel (B) 'non-convergent' (Figure 59). This means the '*palatal and mandibular profiles become more parallel'* (Crossley, 2000b). But, the results of this thesis showed that 'non-convergence' of the resting angle between the palate and the rostral mandible is not a universal indicator of dental problems (Graph 17). Some rabbits with dental disease showed 'convergence' and some rabbits without dental disease showed 'no convergence' (Figure 43).

ii) Genetic predisposition

There is evidence that some prognathic skull traits and resultant malocclusion have a genetic predisposition. Genetic studies in laboratory rabbits show prognathism to be an inherited autosomal recessive trait (Fox and Crary, 1971). Huang (1987) took skull measurements to show statistically that incisor malocclusion was due to a shortened maxilla and elongated mandible. According to Goto and others (1987), variations in mandible measurements can make it possible to identify individual strains within a particular breed.

Genetic predisposition is cited as a cause of acquired dental diseases in pet rabbits, which is often attributed to head shape. For example, Meredith and Crossley (2002) say that '*the incidence of dental disease is low in rabbits with conformation similar to those in the wild but approaches 100% in extreme dwarf and lop breeds*', although they do not cite a source of this information. This view is not supported by the findings of this thesis. Data analysis of 1254 case records of pet rabbits requiring and not requiring dental treatment showed no significant relationship between Dwarf breeds and treatment for dental disease (Graph 32). No breed incidence was found in this analysis. Rabbits with a head shape similar to wild rabbits (Dutch or English) showed a similar incidence of dental disease to breeds with a head shape that is different from wild rabbits (Dwarf Lop, Minilop, Netherland Dwarf). See Graph 31.

Although data analysis showed no breed disposition towards treatment for dental disease, it did show a strong link between gender and dental disease. Males were more susceptible (see Graph 33). This link could signify sex linked genetic predisposition to dental problems in male rabbits or dental disease could be linked with sex hormones, or both. In humans, osteoporosis is a major health problem. Its aetiology appears to be multifactorial, involving hormones, bodyweight, activity, lifestyle and diet. Genetic predisposition is an important factor. One study showed that in half the human population, variation in bone density could be attributed to a single gene locus (Morrison, Cheng Qi and others, 1994). So, although it is possible that genetic predisposition could explain the gender difference in susceptibility to dental disease in rabbits, it could also to be linked with hormonal differences between male and female rabbits. Oestrogen is known to enhance calcium absorption and this may explain why female rabbits are apparently less susceptible to PSADD than males. In laboratory rabbits, it has been shown that ovariectomy results in loss of mandibular bone (Cao and others, 2001) so it is also possible that ovariectomising female pet rabbits could have a deleterious effect on the teeth of rabbits that are on a low calcium diet.

© Frances Harcourt-Brown 2006

In this thesis, it was not possible to investigate the effect of neutering on the incidence of dental disease by data analysis. Whether the individual could be classified as neutered or not was impossible because (i) many cases were included in the data analysis when they were presented for neutering or shortly afterwards and (ii) it was impossible to determine whether dental problems had started in relation to the time of neutering.

(iii) *Underlying metabolic bone disease due to calcium and/or vitamin D deficiency.*

The purpose of this thesis was to explore the possibility that metabolic bone disease causes PSADD in pet rabbits. This idea is a novel concept in rabbit medicine even though metabolic bone disease is recognised a cause of dental problems in other species.

Metabolic bone disease as a cause of dental disease in other species

In veterinary medicine, renal secondary hyperparathyroidism can cause loosening of the teeth in dogs (Carmichael and others, 1995). Nutritional secondary hyperparathyroidism has been described as a cause of alveolar socket bone loss in a number of species. In *Zoo and Wild Animal Medicine 2nd Edition*, Fowler (1986) illustrates loss of alveolar bone in monkeys. Loss of alveolar bone in a kitten is illustrated in *Pathology of Laboratory Animals* (Jubb and others, 1985), who also describe loosening of the teeth in pigs suffering from nutritional osteodystrophy. Tooth loss is described as a clinical feature of fibrous osteodystrophy in horses in *Veterinary Pathology* (Woodward, 1997).

Duckworth and others (1961) describe acquired malocclusion in a group of 130 sheep that grazed on a hill on which the soil was deficient in calcium and phosphorus. Detailed studies, including radiography, blood sampling and *post mortem* examination showed generalised skeletal changes and low blood calcium and phosphorus levels. Skull radiographs showed '*extremely poor*' bone quality with thin, irregularly mineralised bone on the horizontal ramus and disappearance of the alveolar bone supporting the teeth. The shape of the mandible was abnormal and the cheek teeth did not occlude correctly. Following this discovery, an investigation of the effects of a diet deficient in calcium, phosphorus and vitamin on the skeleton and teeth of growing sheep was conducted (McRoberts and others, 1965). The study confirmed that the dietary deficiencies influenced the structure of the teeth although the effects varied according to the stage of tooth development. The authors also found that, in general, a deficiency of calcium depressed enamel formation more than that of dentine while a deficiency of phosphorus and vitamin D depressed dentine formation. Deficient diets induced a disparity of the length of the upper and lower jaw and resulted in malocclusion, which was related to poor mineralisation and deformity of the mandible.

Laboratory studies have shown that alveolar bone is particularly susceptible to metabolic bone disease (Shoji and others, 2000). It is the first area of bone loss in calcium deficiency in rats and results in displacement of the teeth (Myer, 1998). In horses, loss of alveolar socket bone is an early change in nutritional secondary hyperparathyroidism and occurs before other skeletal changes (Krook and Lowe, 1964).

It is not always clear whether alveolar bone loss is a primary or secondary event. Periodontal infection erodes alveolar bone and bacterial infection and periodontitis is a known cause of acquired dental disease in several species. Dental plaque leads to gingivitis and periodontal infection. There is loss of collagen in the periodontal ligament as well as loss of alveolar bone. The teeth loosen and may exfoliate. This syndrome is common in dogs and cats. In human medicine, tooth loss due alveolar bone loss is generally attributed to periodontitis although osteoporosis has been implicated (Ortega and others, 1998). The subject is reviewed by Wactawski-Wende (2001) who describes a potential mechanism for tooth loss in osteoporotic patients. Osteopaenia results in loss of bone mineral density throughout the body, including the maxilla and mandible, which would '*set the stage for more rapid alveolar crestal loss than in the non-osteopaenic individual*'.

© Frances Harcourt-Brown 2006

In veterinary medicine, periodontal disease and tooth loss occurs in sheep. The condition is known as 'broken mouth' and is associated with alveolar bone loss. The exact aetiopathogenesis is unclear. Both primary bacterial infection and mineral deficiencies have been implicated. There is evidence that tooth loss in sheep can be delayed by regular pasture liming (Suckling and others, 1974). Early tooth loss in sheep was the subject of an FRCVS thesis by carried out by Spence (1982) who conducted a study of the pathological changes that take place in the periodontal tissues in over 200 sheep with and without dental problems. The conclusion of the investigation was that '*a number of environmental factors act together to disrupt the normal balance between host defences and bacteriological assault and thereby precipitate disease*'. In a subsequent paper describing the skeletal and biochemical characteristics of sheep with and without broken mouth, Spence says '*focal deterioration of alveolar bone close to the tooth and its association with local gingivitis remains an area worthy of future investigation'* (Spence and others, 1985).

The problems in determining the aetiopathogenesis of broken mouth in sheep mimic those associated with the present study of dental disease in pet rabbits. Spence and others (1985) describe their investigations as '*complex and tedious'* because it involves comparisons during a time course of several years. '*Clinical signs may be the end result of episodes of degeneration with intervening recovery. Some affected animals do not show overt clinical signs.'* This is also true in rabbits.

A early feature of PSADD is the appearance of horizontal ribs on the upper first incisors (Figure 30.) In *Colyer's Variations and Diseases of the Teeth of Animals,* vitamin D and calcium deficiency is cited as a cause of zones of hypoplastic enamel in species with continually erupting teeth.

Laboratory investigations of calcium metabolism in species with continually erupting teeth

Many laboratory studies show a relationship between calcium and/or deficiency and mandibular bone loss and/or changes in dental structure in species with continually erupting teeth. Most of these studies were conducted on the incisors of laboratory rats and mice. An exception is a series of investigations of mole-rats (*Cryptomys damarensis*). These creatures live underground in an extensive maze of burrows. They have no obvious source of vitamin D. A study of their calcium metabolism showed efficient passive absorption of calcium that was proportional to the calcium content of the diet (Buffenstein and Pitcher, 1996). Excess calcium is deposited in the bones and in the teeth. In the study, the calcium content of the incisors was increased by 33% by increasing dietary calcium from 3.17% to 6.65%. The authors observed that mole-rats (like rabbits) grind their teeth when resting. In species, such as mole rats and rabbits, that absorb calcium efficiently from the gut, dental tissue is an effective calcium reserve because it is swallowed and absorbed again from the small intestine, thereby causing a calcium cycle. This mole rat study shows a clear relationship with dietary calcium concentrations and dental structure in a species, like rabbits, with continually erupting teeth.

In rats, Gaunt and Irving (1940) showed that a diet deficient in calcium and phosphorus resulted in bands of pigmented and unpigmented enamel on the incisors and marked changes in the structure of dentine. Engstrom and Noren (1986) found enamel hypoplasia in rats after only 4 weeks of a diet deficient in calcium and vitamin D. Parathyroidectomy causes hypoplastic enamel of the incisors of rats. (Chardi and others 1998, Acevedo and others, 1996) and calcium deficiency at weaning causes a dramatic reduction in mineralisation of enamel on the continually growing incisors of rats, which can be reversed by providing a diet containing the requisite amount of calcium (Lozupone and Favia 1989, Bonucci and others 1994).

© Frances Harcourt-Brown 2006

Calcium and/or vitamin D deficiency not only affects the structure of the teeth of rats, but also affects the supporting bone (Kiliaridis 1989, Kiliaridis and others 1996, Bielaczyc and Golebiewska 1997, Morimoto and others 2000). In rats fed on a low calcium diet, 80% of the alveolar bone is lost over a 20 day period (Ohya and others, 1992). Mandibular bone is more susceptible than other bones to demineralisation due to calcium deficiency (Murray and others 1982, Petrikowski and Overton 1996, Messer and others 1981). Studies in mice suggest specific vitamin D control of alveolar bone formation by a vitamin D receptor pathway (Davideau and others, 2004).

Laboratory investigations in of calcium metabolism and dentition in rabbits

There are few laboratory investigations of the relationship between calcium metabolism and dentition in rabbits. Unfortunately, the papers that relate to skeletal changes seldom mention the bones of the skull. Excessive amounts of vitamin D were shown to cause demineralisation of bone, hyperplasia of dentine, disturbance in the arrangement of periodontal fibres, absorption of alveolar bone and reduced mineral content of the long bones of rabbits in a paper by Cai, 1992. Unfortunately, this paper was written in Chinese so it was impossible to ascertain further details.

A paper by Kato (1966) found that rickets in rabbits causes changes in the structure of teeth. There was demineralisation of the dentine. Prior to this Mellanby and Killick (1926) used rabbits in an attempt to find an animal model for dental caries in man. They kept laboratory rabbits on a vitamin D and calcium deficient diet and looked at the '*calcification of the teeth*'. This paper included radiographic examination of the skull. Histological examination of the teeth showed '*poorly calcified alveolar bone and badly formed dentine containing many interglobular spaces'*. Supplementing the diet with dandelions produced '*good calcification of the bones and teeth'*. The radiographic changes that took place in the jaw of the rabbits with rickets were very similar to those that take place in pet rabbits suffering from acquired dental disease (Figures 60 and 62)

Figure 60:
Radiographs of hemimandibles of laboratory rabbits suffering from rickets
(from Mellanby and Killick, 1926)

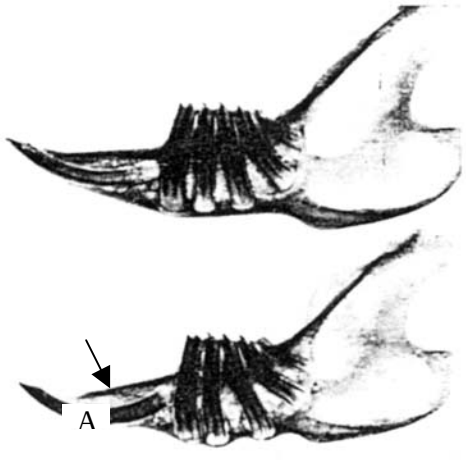

© Frances Harcourt-Brown 2006

Previous publications by the author (attached as supporting papers)

Previous publications by the author support the view that calcium and/or vitamin D deficiency is implicated in the progressive acquired dental disease in rabbits. These publications are attached as supporting papers:

1. An investigation of the diet and feeding habits of pet rabbits showed that their diet can contain calcium concentrations below the level of 0.44%. This is the level that is required for maximum bone calcification. Analysis of the food the rabbit actually eats showed levels as low as 0.26% (Harcourt-Brown, 1996). Pet rabbits are usually fed on a mixed ration containing peas, maize, oats, barley and other ingredients. To balance the deficiencies of the ration, pellets containing a vitamin and mineral supplement are also included in the mixture. Most rabbits select out their favourite ingredients. The most palatable items of these rations are peas and flaked maize, which have a very low calcium content and a marked inverse calcium; phosphorus ratio. For example, the calcium content of peas is 0.12% and 0.14% phosphorus with a 1:3 calcium to phosphorus ratio. Maize contains 0.04% calcium, and 0.28% phosphorus with a 1:11 calcium to phosphorus ratio (Harcourt-Brown, 2001). In laboratory rabbits, bone density is decreased if dietary phosphorus concentrations are greater than 1% and calcium: phosphorus ratio falls below 1:1 (Chapin and Smith, 1967a).
2. The pellets that contain the vitamin and mineral supplement are the least palatable part of the ration and are often left uneaten. Therefore, rabbits that do not eat the supplemented pellets eat a calcium deficient diet that could also be deficient in other vitamins or minerals such as vitamin A and magnesium. The pelleted part of mixed rations also contains vitamin D. So those rabbits that do not eat hay or their pellets do not consume a dietary source of vitamin D. They are not able to synthesise their own vitamin D if they are kept indoors or housed in garages or sheds. In a small study of vitamin D levels of pet rabbits kept outside under free range conditions compared with those kept in hutches, a significantly lower vitamin D level was found in the housed rabbits. Some had undetectable levels, especially in the spring (Fairham and Harcourt-Brown 1999*).
3. In another study to investigate the possibility that metabolic bone disease may play a part in the aetiopathogenesis of acquired dental disease, blood samples were collected from pet rabbits presented for clinical examination (Harcourt-Brown and Baker, 2001*). PTH, haematological and biochemical parameters were measured in rabbits with and without dental disease. The results showed total serum calcium values that significantly higher in rabbits without dental problems and kept outside in comparison with those rabbits that were suffering from advanced dental disease. Analysis of the PTH results showed significantly lower mean PTH concentrations in the free range rabbits in comparison with those suffering from advanced dental disease, which indicated that the rabbits suffering from acquired dental disease were also suffering from hyperparathyroidism.

* *attached as a supporting paper*

© Frances Harcourt-Brown 2006

Visual and radiographic osteopaenia.

A striking feature of skulls of rabbits suffering from the PSADD is the thin, translucent appearance of the bone. This osteopaenic appearance is more marked in the skulls of rabbits with advanced dental disease (Figures 34-39) and is highly suggestive of metabolic bone disease. Metabolic bone disease is called '*paper-bone disease*' in some texts (Fowler, 1986) and this description fits the appearance of the skulls with advanced dental disease.

Bone ash analysis is a technique that might offer a means of quantifying mineral loss. At the outset of the study, samples of bone were submitted for ash analysis but interpretation of the results was impossible because of the variable factors that affect bone density. Examples include age, weight, activity and reproductive status of the animal. But, according to Jubb and others (1985), bone ash analysis is only useful in controlled experiments. When values from an individual animal are low enough to appear significant, the abnormality is apparent without ashing. This was the case in this study.

Disuse atrophy caused by insufficient chewing and lack of dental exercise had been suggested as the cause of the visible osteodystrophy of the skulls of pet rabbits affected by dental disease (Crossley, 1995a). But, this suggestion does not fit with the visual, radiological or biochemical findings in rabbits with acquired dental disease. Disuse osteoporosis occurs in bone that is not subjected to stress or strain. It can be the result of weightlessness (astronauts in space) or prolonged immobilisation of bone e.g. after a fracture. Bone resorption results in hypercalcaemia and reduced levels of circulating PTH (Yang and Stewart, 1996). This is the exact reverse of the findings of pet rabbits suffering from acquired dental disease, which is associated with low serum calcium levels and elevated PTH (Harcourt-Brown and Baker, 2001*). Also, visual osteopaenia was evident in all areas of the skull, including the cribriform area of the maxilla (Graph 9, Figure 32). This area of the skull is not subjected to forces incurred by chewing.

In other species, osteopaenia mainly affects those bones with a large component of cancellous tissue such as the vertebral bodies, flat bones of the skull, scapula, ilium and metaphyseal trabeculae of the long bones (Jubb and others, 1985). Age affects the distribution of lesions. In growing animals, it is the long bones that show the most severe changes, whereas the skull is affected in adults. Cortical bone resorption results in thin cortices and wide medullary cavities (Dennis, 1989). A double cortical line is seen in some species (Lamb, 2000). The vertebral column often shows marked changes where the vertebral end plates and articular facets remain mineralised in comparison with osteopaenic spinous processes, neural arches and vertebral bodies. Radiographic examination of the vertebral column of the rabbits in this study showed an apparent decrease in bone density (Figure 48) but there were so many variables that could affect radiodensity that it was difficult to quantify the changes. Examples include X-ray exposure, weight, size, age and activity of the animal. Osteoporosis has been reported in rabbits as a consequence of intensive housing and inactivity (Drescher and Loeffler, 1991, 1992). Conrad (1997) investigated the bone mineral density of female rabbits and compared group housed and single housed does. The author concluded that pregnancy and lactation, as well as inactivity, had a considerable influence on bone density.

* *attached as a supporting paper*

© Frances Harcourt-Brown 2006

Proposed mechanism for development of cheek teeth malocclusion due to metabolic bone disease.

The prepared skulls and radiographs that were examined for this thesis show a progressive sequence of changes. Based on these changes, a mechanism for the progression of dental disease is proposed and illustrated with radiographs of prepared hemimandibles (Figure 61).

1: In a normal rabbit, the roots of the teeth are supported by a layer of alveolar bone. This alveolar bone is seen as a radiodense line, the *lamina dura* on lateral radiographs. The line of the *lamina dura* can be seen supporting the apex of the root of the tooth. The apices of the roots of the teeth do not extend into the ventral mandibular cortex.

2: Alveolar bone loss is an early feature of PSADD. Alveolar bone loss is a feature of metabolic bone disease in other species and it is proposed that metabolic bone disease causes alveolar bone loss and PSADD in pet rabbits. The initial changes are likely to take place in young growing rabbits when calcium demand is high. In the early stages of PSADD, the line of the *lamina dura* becomes thin. The line supporting the apex of the root of the tooth is the first to disappear. This allows the tooth to elongate at the apex of the root.

3: Elongated roots extend into the ventral mandibular cortex and impinge on the nerve supply that enters the tooth at its apex. This causes discomfort during mastication and results in reluctance to eat hard food such as hay. Owners of rabbits with dental problems often comment that their rabbit has never eaten hay.

4: Insufficient calcium leads to loss of enamel and a change in the structure of the dentine. Horizontal ribs may be seen across the enamel of the upper first incisors. Loss of the central enamel fold of the cheek teeth may be seen radiographically. Loss of the central enamel fold weakens the teeth and leads to loss of the enamel ridges and therefore loss of the zigzag occlusal line. Instead, there is an uneven occlusal line. Elongated roots may grow through the ventral mandibular cortex, which are also be weakened by metabolic bone disease.
Forces generated during mastication tend to tip the crowns of the lower cheek teeth towards the tongue and the upper teeth towards the cheek. Alveolar bone in rabbits is subjected to considerable strain during chewing (Weijs and De Jongh, 1977). These forces lead to increased curvature and the teeth and distortion of the surrounding bone. Curvature of the cheek teeth results in cheek teeth malocclusion

5: Loss of alveolar bone leads to widening of the periodontal space, which can result in secondary periodontal infections, osteomyelitis and periapical abscesses. The teeth may loosen and rotate so their position within the socket alters. Loss of enamel and deterioration of dental structure weakens the teeth so they fracture easily. The teeth often break just below the gingival margin where they are no longer supported by bone.

6: Root elongation affects the nerve and blood supply to the tooth. Eventually the germinal tissue at the apex of the tooth is destroyed so continual growth ceases. This reduces the demand for dietary calcium. At this stage, the teeth are grossly misshapen, which affects the occlusal relationship with opposing teeth. Alveolar bone loss continues, so sockets merge together. Chronic inflammation may lead to dystrophic calcification of the periodontal tissues.

7: Further deterioration of dental structure leads to disintegration of any remaining crowns. Residual roots can resorb within the jaw.

© Frances Harcourt-Brown 2006

Figure 61: Proposed mechanism for development of acquired dental disease due to metabolic bone disease.

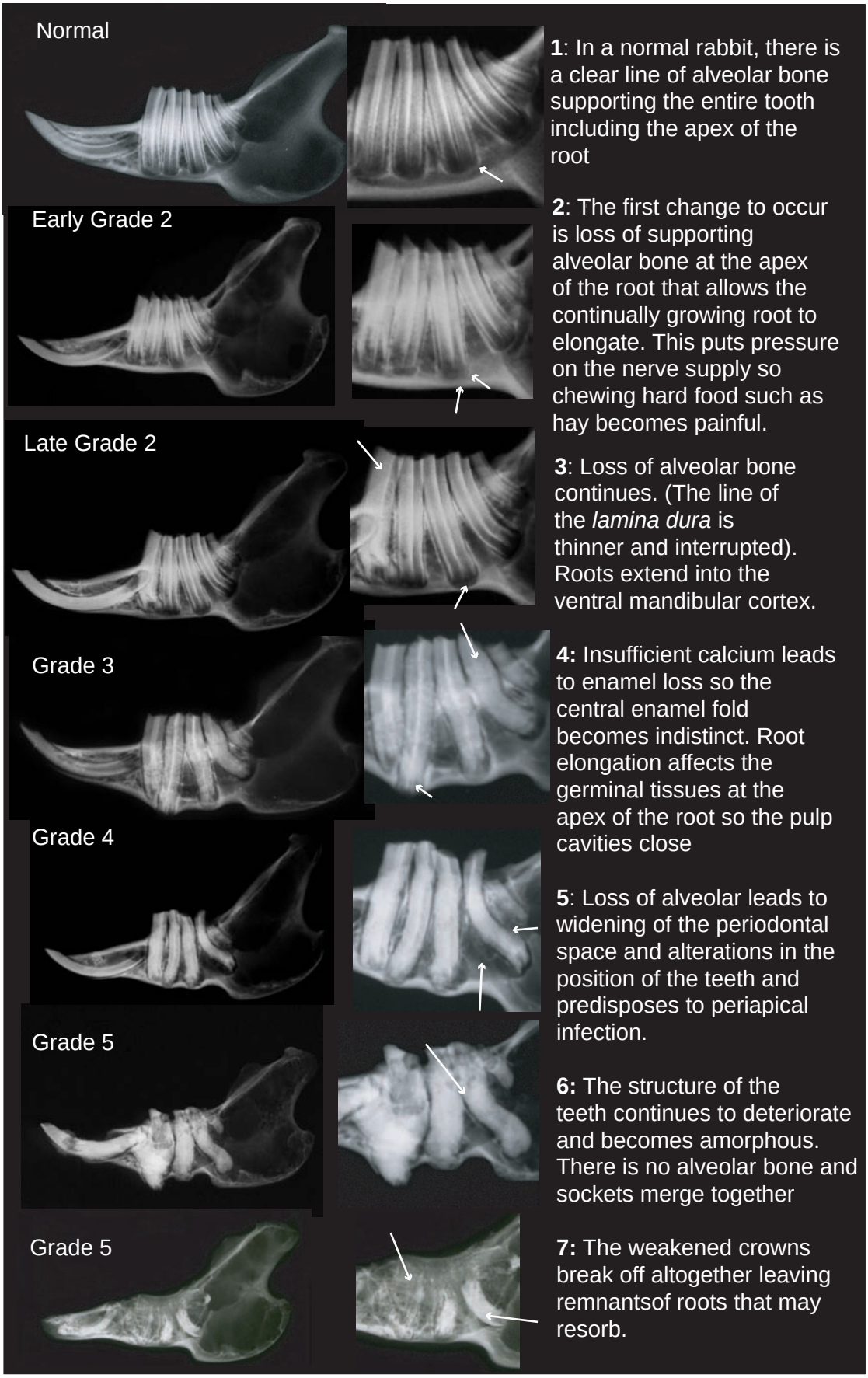

Periapical abscesses

A finding of this thesis was a high incidence of periapical abscesses in rabbits with PSADD. The incidence of abscesses increased as dental disease advanced (see Graph 23). According to Wactawski-Wende (2001) in humans '*loss of bone density may lead to more rapid resorption of alveolar bone following insult by periodontal bacteria'*. This could account for the increased incidence of abscesses in rabbits showing loss of bone density.

Crossley (2003a) attributes mandibular abscesses to iatrogenic abscesses following tooth clipping and says that this is '*probably the most common cause of abscessation'*. The findings of this thesis do not support this view. Examination of the case records of 55 rabbits showing radiographic evidence of abscesses showed that 26 had no history of dental treatment (Table 1). Of the 12 rabbits that had received dental treatment, 7 had their teeth shortened using a dental burr and only 5 with clippers. Also, it is not only the mandibular teeth that are affected by periapical abscesses. The upper molars can also be affected and these are seldom shortened, either with burrs or clippers.

Treatment for rabbits with the progressive syndrome of acquired dental disease

Those authors who believe cheek teeth malocclusion is due to lack of an abrasive diet advocate reducing the height of the crowns to '*approximate the wear that would normally be experienced'* every 3-8 weeks until '*normal occlusion is re-established, or in some cases indefinitely*' (Wiggs and Lobprise, 1997). A more drastic approach is recommended by Crossley (2002), who describes reduction of crown height of **all** the cheek teeth down to gingival level. The idea is that the occlusal surfaces will return to a more normal pattern if they are taken out of occlusion. Radiographs showing 'non-convergence' are used as an indication for this treatment. In the past, crown removal was also the author's approach (Harcourt-Brown, 1997*) but an improved understanding of the anatomy and physiology of lagomorph dentition and an insight into the aetiopathogenesis and progression of acquired dental disease has resulted in a complete reversal of this opinion. Examination of prepared skulls and radiographs show that it is not possible to restore normal shape or structure to diseased teeth. Substantial changes have taken place by the time clinical signs are evident. Crown reduction removes the dense atubular dentine from the occlusal surface of the teeth and potentially exposes innervated dentine that is nociceptive. Occluding cheek teeth are required to grind food, especially if it is fibrous, and it impossible for rabbits to eat hay, grass or vegetables if all the crowns are removed. Crossley (2002) notes that "*supportive care is required for a while following occlusal adjustments as it takes time for the rabbit to adjust its chewing pattern"*. If the rabbit has reached the stage of PSADD when the teeth are no longer growing, removing all the crowns to gum level will result in permanent crown loss and impairment of the ability to chew fibrous food (Figures 63).

It seems illogical to remove the crowns of all the cheek teeth when a simpler approach of only trimming off elongated spurs that are penetrating surrounding soft tissues restores appetite and ability to chew immediately on recovery from anaesthesia. This is the author's current approach (Figures 63 and 64). A parallel can be drawn with equine dentistry where it is recommended that '*great care must be taken to ensure that only the hook is positioned between the jaws of the tool. Long hooks may be reduced in two or three stages to avoid exposing the pulp canal*' (Tremaine, 1997). In rabbits, spurs can be removed from cheek teeth using long handled tooth clippers designed for rabbit and rodent dentistry. A diamond rasp is used to smooth off any jagged edges that remain. Again an analogy with equine dentistry can be made where the advice is '*Excessive rounding of the edges of the cheek teeth and flattening of their occlusal surfaces reduces their efficiency for mastication, because enamel ridges are integral to mechanical breakdown of fibrous material; these practices are therefore undesirable although they can increase the interval between raspings*' (Tremaine, 1997).

* *attached as a supporting paper*

© Frances Harcourt-Brown 2006

Figure 62:
Treatment of rabbits with PSADD:

TOOTH TRIMMING

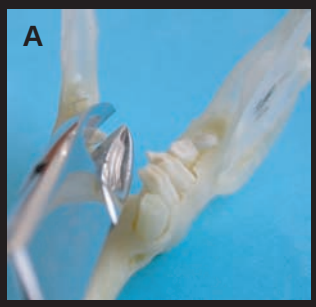

As a result of the findings of this thesis, the author's approach to tooth trimming is to only remove the spurs (A) on affected teeth rather than remove all the crowns down to gum level, which is advocated by some authors.

The rabbit illustrated in Figure B has undergone 'generalised coronal reduction' i.e all the crowns were burred down to the gum. The teeth are no longer growing so the rabbit is left permanently without functional cheek teeth.

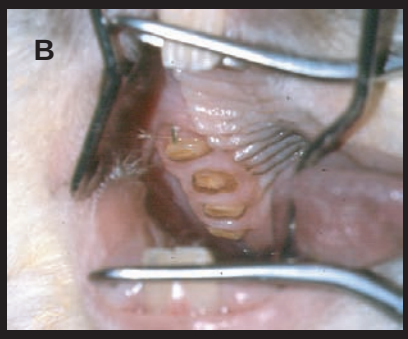

IMPROVING DIET AND HUSBANDRY

Although root elongation and changes in the position of diseased teeth are irreversible, improving the diet to include sufficient calcium can bring about an improvement in enamel quality and dental structure if dietary modification takes place while teeth are still growing. These images show the incisors of the same rabbit before (C) and after (D) dietary modification. No other dental treatment was performed

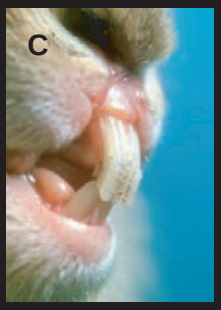





The provision of a fibrous diet of grass, garden weeds, vegetables and hay, supplented by a small amount of concentrated food in the form of an extruded or compressed pellet provides a balanced diet that provides dental wear, prevents boredom and gastrointestinal disturbances associated with insufficient fibre.



Allowing exposure to natural daylight and sunshine enables the rabbit to synthesise its own vitamin D according to metabolic need. Access to outdoor conditions also permits the rabbit to graze and browse which is both mentally and physically beneficial .



Mixed rations appear to play a major role in the development of the progressive syndrome of acquired dental disease (PSADD) in pet rabbits and should always be avoided.

Figure 63: Different approaches to removing spurs from cheek teeth

Illustration from Harcourt-Brown, 2002. Drawn by N Harcourt-Brown from a cross section of a decalcified skull.

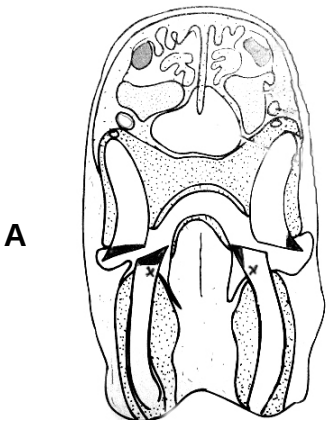

Removing all the exposed crowns down to gum level is sometimes recommended as treatment for cheek tooth malocclusion (illustrated on side A of drawing).

The author's simpler approach of just removing spurs is illustrated on side B.

This diagram shows it is erroneous to believe that shortening teeth down to gum level will increase the time for the spur to regrow. Assuming the rate of growth is the same, whichever method of trimming is used, the part of the tooth that is destined to become a spur (x) will take the same time to grow. In reality, it may take longer if only the spur is removed. Laboratory investigations in rabbits have shown that taking teeth out of occlusion can increase their rate of growth by up to twice that of a control group. (Terajima, 1989).

In pet rabbits, the number of times that teeth require trimming depends on the rate of growth and the health of the teeth. Ironically, the healthier the teeth, the more times they require trimming. Misshapen, crumbling teeth with little or no enamel require trimming on fewer occasions. Eventually diseased teeth stop growing but once one tooth stops growing, spurs may develop on a different tooth, so the rabbit may continue to require periodic treatment for some time. It is important to monitor these patients by examining their oral cavity on a regular basis.

Despite the controversy about whether acquired dental disease is due to lack of dental wear or metabolic bone disease, there is agreement that the majority of dental problems can be prevented by a diet of predominantly grass and/or hay supplemented with vegetables and other plants. Proponents of both the lack of dental wear theory and the metabolic bone disease theory agree that mixed cereal rations should be avoided altogether. It is regrettable that pet food manufacturers and retailers continue to ignore the link between their products and the huge problem of dental disease in pet rabbits, which causes immense suffering to the animals and financial hardship, grief and guilt to their owners.

Prognosis for rabbits with PSADD

In addition to differences in opinion about the aetiopathogenesis and treatment for rabbits with dental disease, there is also a difference of opinion about the prognosis. Crossley (2003b) says '*Unfortunately, in many rabbits, coronal abnormalities are severe before they are diagnosed, in which case euthanasia may be preferable to lifelong palliative treatment'*. This is not the authors view. In her experience, the prognosis for rabbits suffering from PSADD is not bad enough to warrant routine euthanasia, although affected rabbits may require dental treatment on several occasions. Eventually, the teeth stop growing, although the diseased teeth are not fully functional. If a rabbit is nursed through the earlier stages, its condition often improves in the later stages (Figure 65).

© Frances Harcourt-Brown 2006

Figure 64:
Prognosis for the progressive syndrome of acquired dental disease (PSADD)

The outlook for rabbits with acquired dental disease is not hopeless. If rabbits with early changes such as epiphora, spurs or dacryocystitis can be nursed through to the stage where the teeth are no longer growing and if they will eat grated or softened food, they can lead a life of a reasonable quality providing there is no soft tissue damage to the buccal mucosa from sharp spurs or chronic ulcers. Osteomyelitis and abscesses are serious complications but can be treated.



This radiograph shows a lateral view of an obese rabbit that also had advanced dental disease. There is a huge, fat-filled dewlap.
Although the owners were aware of the incisor malocclusion, they had no idea that the rabbits also had problems with the cheek teeth.



In the past, this 6 year old male Dwarf Lop rabbit has had extensive and repeated dental treatment including treatment for abscesses. When this photograph was taken He had not required any dental treatment for over two years.

Incidental findings of this thesis

The osteopaenic appearance of the prepared skulls that were examined for this thesis was sometimes accentuated by an oily texture and yellowing colour of the bone (Graph 8, Figure 31). This oily texture was not always related to dental problems and was seen in some skulls with normal dentition and thick bone. It was also evident in many of the skulls that were examined at the Natural History Museum (Figure 57). This oily texture could be related to dietary fat levels. It has been shown that tooth lipids in rabbits are in direct equilibrium with dietary fats (Das and others, 1976). The skulls from wild rabbits were all smooth and white indicating a low fat diet and sufficient dietary calcium. The yellow colour was probably related to the colour of the fat. Some rabbits have an inherited condition that results in a deficiency of a specific liver enzyme that metabolises carotenoid pigments or xanthophylls (Lindsey and Fox, 1994). The fat of these rabbits suffering is an obvious yellow.

Three of the prepared skulls appeared heavy and had a dense, chalky white appearance (Figure 31). These rabbits were known to be in chronic renal failure. Since preparing this thesis, the author has noticed that increased radiodensity of the skeleton of rabbits is a feature of chronic renal failure in some rabbits. In other species, osteopetrosis (chalk bones) may be due to a genetic disease or a chronic dietary excess of calcium or vitamin D. In rabbits, hereditary osteopetrosis is recorded but is lethal. Affected rabbits usually die before they are 3 weeks old (Popoff and Marks, 1990). The increased radiodensity of the bones that is seen in pet rabbits suffering from chronic renal failure is presumably due to the kidney's inability to excrete calcium that continues to be absorbed from the gut. In the rabbit, intestinal calcium absorption is efficient and passive absorption takes place in the absence of vitamin D. Dietary and blood phosphate levels may also play a part in this syndrome.

Rabbits also seem more susceptible than other species to the deposition of calcium salts in areas of metabolically impaired or dead tissue. This observation is made from examination of radiographs of pet rabbits. This could be due to the rabbit efficient calcium absorption and high blood levels. This could also explain the increased radiodensity of the teeth and calcification of periapical tissue of rabbits with advanced dental disease (see Figure 30, 39, 47, 55).

© Frances Harcourt-Brown 2006

Conclusion

The hypothesis of this thesis is that metabolic bone disease is a possible cause of acquired dental disease in pet rabbits. This is a novel concept in rabbit medicine. For the thesis, prepared skulls and radiographs were subjected to a detailed examination in order to study the morphological and radiological changes that take place in the bones and teeth of rabbits with a progressive syndrome of acquired dental disease (PSADD) that is common in rabbits kept as pets. Osteopaenia, affecting the bones of the skull, was evident, both visually and radiographically. There was progressive loss of alveolar bone and elongation of some or all the roots of the teeth. There were marked changes in the structure of dental tissue, including a reduction in the formation of enamel. These findings provide evidence, but not proof, to support the hypothesis that metabolic bone disease is a cause of dental disease in pet rabbits, especially when taken in conjunction with the author's previous published findings of: (i) potentially low calcium levels in the diet of pet rabbits, (ii) low blood calcium and high parathyroid hormone levels in rabbits suffering from advanced dental disease, (iii) undetectable vitamin D concentrations in the blood of pet rabbits. Loss of alveolar bone is a known feature of metabolic bone disease in other species.
The texture of the diet may also be an important contributory factor in the development of PSADD. However, the investigations in this thesis showed no evidence that PSADD is due to lack of an abrasive diet. Acquired cheek teeth malocclusion is one manifestation of PSADD and is often attributed to insufficient dental wear causing an increase in the height of the crowns, followed by curvature of the crowns, increased intraocclusal pressure with root elongation as a late change. In this thesis, an increase in the height of the crowns of the teeth was not a feature of the prepared skulls and radiographs, although it was a difficult parameter to measure because of the curvature of the teeth. Whether or not the crowns are long is an important point because crown elongation is used as justification for a commonly recommended procedure of ‘generalised coronal reduction’ i.e. removing the crowns of the cheek teeth down to the level of the gingiva. This procedure is recommended as a treatment for cheek teeth malocclusion and is performed on all the cheek teeth, not just those that have developed spurs. Some texts even recommend generalised coronal reduction every 4-8 weeks to prevent root elongation. This thesis shows that root elongation is an early feature of PSADD. It was present in all the skulls and radiographs of affected rabbits suggesting that it is the first change to take place. Therefore it is illogical to believe that coronal reduction can prevent root elongation. Instead, it removes the occlusal surfaces of the teeth and impairs the ability to chew food, especially fibrous food. It could also expose innervated dentine and pulp cavities if the procedure is performed on healthy teeth or those rabbits in the initial stages of PSADD. Generalised coronal reduction is at best, unnecessary and at worst, detrimental.

It is conceivable that a genetic predisposition to PSADD may be present. Data analysis suggested a sex predilection towards males although there was no breed disposition. But, even after the extensive investigations of this thesis, the exact aetiopathogenesis of acquired dental disease in pet rabbits remains enigmatic. In order to prove the exact cause of the condition, a controlled prospective study is required that would take several years. The influence of the abrasive properties of the diet, as well as its vitamin and mineral content, needs further investigation. Ideally, the study should also include the calcium status of the dam as well as the investigated rabbits during their period of growth as this is shown to influence alveolar bone density in other species (Shoji and others, 2000). A quantitative method of measuring bone mineral density, such as dual energy X-ray absorptiometry (DXA) or bone scanning would be needed. These methods have been evaluated in rabbits (Norris and others, 2000, Garcia and others, 1974). Sophisticated equipment and specialised software would be required for this type of investigation, which is beyond the scope of a veterinary surgeon in general practice.

© Frances Harcourt-Brown 2006

References

Acevedo, A.C., Chardin, H., Staub, J.F., Septier, D., Goldberg, M. (1996). Morphological study of amelogenesis in the rat lower incisor after thyro-parathyroidectomy, parathyroidectomy and thyroidectomy. *Cell Tissue Research,* **283,** 151-157.

Ardran, G.M., Kemp, F.H. (1958). A radiographic analysis of mastication and swallowing in the domestic rabbit: *Oryctolagus cuniculus*. *Proceedings of the Zoological Society of London,* **130,** 257-274.

Barber, P.J, Elliott, J., Torrance, A.G. (1993). Measurement of feline intact parathyroid hormone: assay validation and sample handling studies. *Journal of Small Animal Practice,* **34,** 614-620.

Barlet, J.P. (1980). Plasma calcium, inorganic phosphorus and magnesium levels in pregnant and lactating rabbits. *Reproduction, Nutrition, Development,* **20:3A**, 647-651.

Barone, R., Pavaux, C., Blin, P.C., Cuq, P. (1973). *Atlas d'anatomie du lapin.* Masson & Cie, Paris.

Barr, D.R., Sadowski D.L., Hu J., Bourdeau, J.E. (1991). Characterisation of the renal and intestinal adaptations to dietary calcium deprivation in growing female rabbits. *Mineral and Electrolyte Metabolism*, **17**, 32-40.

Bhadresa, R. (1977). Food preferences of rabbits *Oryctolagus cuniculus* at Holkhan sand dunes, Norfolk. *Journal of Applied Ecology,* **14,** 287-291.

Bielaczyc, A., Golebiewska, M. (1997). Ultrastructural changes on the root surface in "pressure zone" after experimental movement of teeth in young rats fed a low calcium and vitamin D-deficient diet. *Roczniki Akademii Medycznet w Bialymstoku,* **42,** 147-152.

Bishop, M.A. (1995). Is rabbit dentine innervated? A fine structural study of the pulpal innervation in the cheek teeth of the rabbit. *Journal of Anatomy,* **186**, 365-372.

Blood, D.C., Studdert, V.P. (1999). *Ballières Comprehensive Veterinary Dictionary,* 2nd Edition. Ballière Tindall, London.

Bohmer, E., Kostlin, R.G. (1988). Dental disease of rabbits and rodents. *Der praktische Tierarzt,* **69**, 37-50.

Bonucci, E., Lozupone, E., Silvestrini G., Favia, A., Mocetti, P. (1994). Morphological studies of hypomineralised enamel of rat pups on a calcium deficient diet, and of its changes after return to normal diet. *Anatomy Record,* **239,** 379-395.

Bourdeau, J.E., Shwer-Dymerski, D.A., Stern, P.A. and Langman, C.B. (1986). Calcium and phosphorous metabolism in chronically vitamin D-deficient laboratory rabbits. *Mineral and Electrolyte Metabolism*, **12**, 176-185.

Bourdeau, J.E., Bouillon, R., Zikos, D., Langman, C.B. (1988). Renal responses to calcium deprivation in young rabbits. *Mineral and Electrolyte Metabolism,* **14**, 150-157.

Bourdeau, J.E., Lau, K. (1992). Regulation of cystosolic free calcium concentration in the rabbit connecting tubule: a calcium absorbing renal epithelium. *Journal of Laboratory Clinical Medicine,* **119**, 650-662.

Breslau, N.A. (1996). Calcium, magnesium and phosphorus: Intestinal absorption. In *Primer on the Metabolic Bone Diseases and Disorders of Mineral Metabolism.* Ed.M.J. Favus. Lippincott-Raven, Philadelphia, pp. 49-56.

© Frances Harcourt-Brown 2006

Brommage, R., Miller, S.C., Langman, C.B., Bouillon, R., Smith, R., Bourdeau, J.E. (1988). The effect of chronic vitamin D deficiency on the skeleton in the adult rabbit. *Bone,* **9**, 131-139.

Brown, S.A. (1992). Surgical removal of incisors in the rabbit. *Journal of Small Animal Exotic Medicine,* **1,** 150-153.

Bucher, L. (1994). Effects of different feeds on growth and abrasion of the incisor teeth of dwarf rabbits (German) Doctoral Thesis, University of Berlin.

Buffenstein, R., Pitcher, T. (1996). Calcium homeostasis in mole rats by manipulation of teeth and bone calcium reservoirs. In *The ComparativeEndocrinology of Calcium Regulation.* Eds. C. Dacke, J. Danks, I. Caple, G. Flik. Journal of Endocrinology Ltd, Bristol, pp.177-181.

Burling, K., Murphy, C.J., Da Siva Curiel, J., Koblik, P., Bellhorn, R.W. (1991). Anatomy of rabbit nasolacrimal duct and its clinical implications. *Progress in Veterinary Comparative Opthalmology,* **1,** 33-40.

Brown, S.A. (1992). Surgical removal of incisors in the rabbit. *Journal of Small Animal Exotic Medicine,* **1,** 150-153.

Buss S.L., Bourdeau J.E. (1984). Calcium balance in laboratory rabbits. *Mineral and Electrolyte Metabolism,***10,** 127-132.

Byers, M.R. (1984). Dental sensory receptors. *International Review of Neurobiology,* **25**, 39-94.

Cai, J.J. (1992). Effect of vitamin D overdosage on the tooth and bone development of rabbits (Article in Chinese, English abstract). *Chung Hua Kou Chiang Hsueh Tsa Chih,* **27,** 296-299.

Canalis, E. (1996). Regulation of bone remodelling. In *Primer on the Metabolic Bone Diseases and Disorders of Mineral Metabolism, 3rd Edition.* Ed. M. J. Favus. Lippincott-Raven, New York, pp. 29-34.

Cao, T, Cao T., Shirota, T., Yamazaki, M., Ohno, K., Michi, K. (2001). Bone mineral density in mandibles of ovariectomised rabbits. *Clinical Oral Implants Research,* **12,** 604.

Caple, I.W. (1996). Endocrine control of mammalian calcium metabolism. In *The Comparative Endocrinology of Calcium Regulation.* Eds. C. Dacke, J. Danks, I. Caple, G. Flik. Journal of Endocrinology Ltd, Bristol, pp. 157-164.

Carmichael , D.T., Williams, C.A., Aller, M.S. (1995). Renal dysplasia with secondary hyperparathyroidism and loose teeth in a young dog. *Journal of Veterinary Dentistry,* **12,** 143-146.

Chai, C.K. (1970). Effect of inbreeding in rabbits. Skeletal variations and malformations. *Journal of Heredity,* **61,** 2-8.

Chapin, R.E., Smith, S.E. (1967a). Calcium requirements of growing rabbits. *Journal of Animal Science,* **26,** 67-71.

Chapin, R.E., Smith, S.E. (1967b). The calcium tolerance of growing and reproducing rabbits. *Cornell Veterinarian*, **57**, 480-492.

Chardi, H., Acevedo, A.C., Risnes, S. (1998). SEM study of the development of rat incisor enamel hypoplasia under hypocalcaemia induced by thyro-parathyroidectomy. *Connective Tissue Research,* **39,** 157-164.

Cheeke, P.R., Bronson, J., Robinson, K.L., Patton, N.M.(1985). Availability of calcium, phosphorus and magnesium in rabbit feed and mineral supplements. *Journal of Applied Rabbit Research,* **8,** 72-74.

Cheeke, P.R. (1987). *Rabbit Feeding and Nutrition.* Academic Press, San Diego.

© Frances Harcourt-Brown 2006

Cheeke, P.R., Amberg, J.W. (1973). Comparative calcium excretion by rats and rabbits. *Journal of Animal Science,* **37**, 450.

Clemens, T.L , Adams, J.S. (1996). Vitamin D metabolism. In *Primer on the Metabolic Bone Diseases and Disorders of Mineral Metabolism, 3rd Edition.* Ed. M. J. Favus. Lippincott-Raven, New York, pp. 109-114.

Conrad, J. (1997). Untersuchungen zur Knochendichte bei weiblichen ZIKA-Zuchtkaninchen an calcaneus sowie am distalen Tibiaende über einen Zeitram von mehreren Reproduktionszylen mittels peripherer Quantitativ Computertomographie (pQCT^{tm}). Doctoral Thesis. English Abstract.

Colyer, J.F. (1990). *Colyer's Variations and Diseases of the Teeth of Animals, (Revised edition).*Eds. A.E.W. Miles and C.Grigson, Cambridge University Press, Cambridge.

Crossley, D.A. (1995). Clinical aspects of lagomorph dental anatomy: The rabbit (*Oryctolagus cuniculus). Journal of Veterinary Dentistry,* **12,** 137-140.

Crossley, D.A. (1995a). Dental disease in rabbits. *Veterinary Record,* **137,** 384.

Crossley, D.A., San Roman, F., Sánchez, M. (1998). Odontologia en otras pequenas especies. In *Atlas de odontologia en pequenos animal.* Ed. F. San Roman. Gras Edicions, Madrid, pp. 243-257.

Crossley, D.A., Jackson, A., Yates, J., Boydell, I.P. (1998). Use of computed tomography to investigate cheek tooth abnormalities in chinchillas (*Chinchilla laniger). Journal of Small Animal Practice,* **39**, 385-389.

Crossley, D.A. (2000). Rabbit and Rodent Radiology. In *An Atlas of Veterinary Dental Radiology.* Iowa State University Press, Ames, pp. 247-259.

Crossley, D.A. (2000a). Dental disease in lagomorphs and rodents. In *Kirk's current Veterinary Therapy.* Ed. J.D.Bonagura, W.B.Saunders Company, Philadelphia, pp.1133-1137.

Crossley, D.A. (2000b). Rabbit and rodent oral anatomy and physiology. *Proceedings of North American Veterinary Conference,* pp. 990-992.

Crossley, D.A. (2003). Dental disease in chinchillas in the UK. *The European Journal of Companion Animal Practice,* **13,** 57-65.

Crossley, D.A. (2003a). Oral biology and disorders of lagomorphs. *The Veterinary Clinics of North America. Exotic Animal Practice.* Ed. D.A. Crossley. Saunders, Philadelphia, pp.629-660.

Crossley, D.A. (2003b). Small mammal dentistry. In *Ferrets, rabbits and rodents. Clinical medicine and surgery. 2nd Edition* . Eds, K.E. Quesenbery, J.W. Carpenter. Saunders, Missouri, pp. 370-382.

Das, S.K., Adhikary, P.K., Bhattacharyya, D.K. (1976). Effects of dietary fats on the fatty acid composition of enamel and dentinal lipids of rabbit molars. *Journal of Dental Research,* **55,** 1061-1066.

Davideau, J.L., Lezot, F., Kato, S., Bailleul-Forestier, I., Berdal, A. (2004). Dental alveolar bone defects related to vitamin D and calcium status. *Journal of Steroid Biochemistry and Molecular Biology,* **89,** 615-618.

Dennis, R. (1989). Radiology of metabolic bone disease. *Veterinary Annual,* **29,** 195-206.

De Blas, C., Wiseman, J. (1988). *The Nutrition of the Rabbit.* CABI Publishing, Cambridge.

DePalo, D., Theisen, A.L., Langman, C.B. an others (1988). Renal responses to calcium deprivation in young rabbits. *Mineral and.Electrolyte Metabolism,* **14,** 313-320.

© Frances Harcourt-Brown 2006

DeLuca, H.F. (1986). The metabolism and functions of vitamin D. *Adv. Exp. Med. Biol.,* **196,** 361-375.

Drescher, B., Loeffler, K. (1991). Einfluβ unterschiedlicher Haltungsverfahren und Bewegungsmöglichkeiten auf die Kompakta der Röhrenknochen von Versuchs- und Fleischkaninchen. *Tierärztliche Umschau,* **46,** 736-741.

Drescher, B., Loeffler, K. (1992). Einfluβ unterschiedlicher Haltungsverfahren und Bewegungsmöglichkeiten auf die Kompakta der Röhrenknochen von Mastkaninchen. *Tierärztliche Umschau,* **47,** 175-179.

Duckworth, J., Benzie D., Cresswell E., Hill R., Dalgarno A.C. (1961). Dental malocclusion and rickets in sheep. *Research Veterinary Science,* **2,** 375-380.

El Shorafa, W.M., Feaster, E., Ott, E.A., Asquith, R.L. (1979). Effect of vitamin D and sunlight on growth and bone development of young ponies. *Journal of Animal Science,* **48,** 882-886.

Emily, P. (1991). Problems peculiar to continually erupting teeth. *Journal of Small Exotic Animal Medicine,* **1**, 56-59.

Engstrom, C., Noren, J.G. (1986). Effects of orthodontic force on enamel formation on enamel formation in normal and hypocalcaemic rats (Abstract). *Journal of Oral Pathology,* **15,** 78-82.

Fairham, J., Harcourt-Brown, F.M. (1999). Preliminary investigation of the vitamin D status of pet rabbits. *Veterinary Record,* **145**, 452-454. (Attached as supporting paper)

Fekete, S. (1989). Recent findings and future perspectives of digestive physiology in rabbits: a review. *Acta Vet. Hung.*, 37, 265- 279.

Fowler, M.E. (1986). Metabolic Bone Disease. In *Zoo and Wild Animal Medicine 2nd Edition.* W.B. Saunders, Philadelphia, pp. 69-90.

Fox, R.R., Crary, D.D. (1971). Mandibular Prognathism in the Rabbit. *Journal of Heredity,* **62,** 163-169.

Garcia, D.A., Davis, M.A., Kapur, K.K., Goldbaher, P. (1974). Detection of local changes of mineral metabolism within the jaws of rabbits by bone scanning. *Journal of Dental Research,* **53,** 447-452.

Gaunt, W.E., Irving, J.T. (1940). The influence of dietary calcium and phosphorus upon tooth formation. *Journal of Physiology,* **99,** 18-29.

Genant, H.K. (1996). Radiology of osteoporosis and other metabolic bone diseases. In *Primer on the Metabolic Bone Diseases and Disorders of Mineral Metabolism, 3rd Edition.* Ed. M. J. Favus. Lippincott-Raven, New York, pp.152-163.

Gilsanz, V., Roe, T.F., Antunes, J., Carlson, M., Duarte, M.L., Goodman, W.G. (1991). Effect of dietary calcium on bone density in growing rabbits. *American Journal of Physiology*, **260**, E471-E476.

Grier, S.J., Turner, A.S., Alvis, M.R. (1996). The use of dual-energy x-ray absorpiometry in animals. *Invest. Radiol.* **1,** 50-62.

Goto, N., Watanabe, K., Umezawa, H., Yazawa, H., Kuramasu, S. (1987). Morphometrical observations on the mandible of five strains of rabbits and strain identification using mandible measurements. *Laboratory Animals,* **21,** 188-194.

Hamidur Rahman, A.S.M., Al-Mahmud, K.A., Nashiru-Islam,K.M. (1983). Dental Malocclusion in New Zealand White Rabbit. *Bangladesh Veterinary Journal,* **16,** 85-88.

© Frances Harcourt-Brown 2006

Harcourt-Brown, F.M. (1995). A review of clinical conditions in pet rabbits associated with their teeth. *Veterinary Record,* **137,** 341-346. *(Attached as supporting paper)*

Harcourt-Brown, F.M. (1996). Calcium deficiency, diet and dental disease in pet rabbits. *Veterinary Record,* **139,** 567-571. *(Attached as supporting paper)*

Harcourt-Brown, F.M. (1997). Diagnosis, treatment and prognosis of dental disease in pet rabbits. *In Practice,* **19,** 407-421. *(Attached as supporting paper)*

Harcourt-Brown, F.M., Baker, S.J. (2001). Parathyroid hormone, haematological and biochemical parameters in relation to dental disease and husbandry in pet rabbits. *Journal of Small Animal Practice,* **42,** 130-136. *(Attached as supporting paper)*

Harcourt-Brown, F.M. (2001). *Textbook of Rabbit Medicine.* Butterworth Heinemann, Oxford.

Hillson, S. (1986). *Teeth.* Cambridge University Press, Cambridge.

Hirschfield, Z., Weinrab, M.M., Michaeli, Y. (1973). Incisors of the rabbit: morphology, histology and development. *Journal of Dental Research.,* 52, 377-384.

Holick, M.F. (1990). Vitamin D and bone health. *Journal of Nutrition,* **126**, 1159S-1164S.

Horowitz, S.L., Weisbroth, S.H., Scher, S. (1973). Deciduous dentition in the rabbit (*Oryctolagus cuniculus)* a roentgenographic study. *Archives of Oral Biology*, **30,** 517-523.

How, K.L., Hazewinkel, H.A.W., Mol, J.A. (1994). Photosynthesis of vitamin D3 in cats. *Veterinary Record,,* **134,** 384.

Huang, C.M. (1987). Morphometric relationships between skull traits and malocclusion in the domestic rabbit. *Bulletin of the Institute of Zoology Academia Sinica*, **26**, 123-131.

Hunt, C.E., Harrington, D.D. (1974). Nutrition and nutritional diseases of the rabbit. In *The Biology of the Laboratory Rabbit. First Edition.* Eds. S.H. Weisbroth, R.E. Flatt and A.L. Kraus. Academic Press, San Diego, pp.403-428.

Ireson, H. (1968). A preliminary report on an abnormal dental condition in rabbits. *Journal of the Institute of Animal Technicians,* **19,** 36-39.

Jenkins, J.R. (1997). Soft Tissue Surgery and Dental Procedures. In *Ferrets, Rabbits and Rodents, Clinical Medicine and Surgery*. Eds. E.V. Hillyer and K.E. Quesenberry, W.B.Saunders Philadelphia, pp. 227-239.

Jubb, K.V.F., Kennedy, P.C., Palmer, N. (1985). Bones and Joints. In *Pathology of Domestic Animals, Volume 1.* Academic Press, London, pp. 2-131.

Jubb, K.V.F., Kennedy, P.C., Palmer, N. (1985a). The Alimentary System. In *Pathology of Domestic Animals, Volume.* Academic Press, London, p. 8.

Kamphues, V.J., Carstensen, P. Schroeder, D and others. (1986). Effect of increasing calcium and vitamin D supply on calcium metabolism in rabbits (Article in German with an English Summary). *Journal of Animal Physiology and Nutrition,* **50,** 191-208.

Kamphues, J. (1991). Calcium metabolism of rabbits as an etiological factor for urolithiasis. *Journal of Nutrition,* **121,** S95-S96.

Kardong, K.V. (1995). Cranial kinesis in hares. In *Vertebrates, Comparative Anatomy, Function, Evolution.* W. C. Brown Communications Inc., Dubuque, p. 231.

Kato, J. (1966). Effects of the administration of vitamin D2, D3, parathyoid hormone and calcium on hypocalcification of rabbit dentine and on changes in blood constituents caused by experimental rickets. *Gunma Journal of Medicine,* **15,** 174-193.

© Frances Harcourt-Brown 2006

Keil, A. (1949). Uber die Frage des naturlichen Vorkommens und der experimentellen Erzeugung echter Zahnkaries bei Tieren. **DZZ 4;S,** 694.

Kennedy, A. (1965). The urinary excretion of calcium by normal rabbits. *Journal of Comparative Pathology,* **75**, 69-74.

Kertesz, P.A. (1993). Colour Atlas of Veterinary Dentistry and Oral Surgery. Wolfe, London.

Kiliaridis. S. (1986). Masticatory muscle function and craniofacial morphology. An experimental study in the growing rat fed a soft diet. *Swedish Dental Journal Supplement,* **36,** 1-55.

Kiliaridis, S. (1989). Muscle function as a determinant of mandibular growth in normal and hypocalcaemic rat. *European Journal of Orthodontics,* **11,** 298-308.

Kiliaridis, S., Engstrom, C., Lindskog-Stokland, B., Katsaros, C. (1996). Craniofacial bone remodeling in growing rats fed a low calcium and vitamin D deficient diet and the influence of masticatory muscle function. *Acta Odontologica Scandinavia,* **54,** 320-326.

Kim, E.H., Woo, K.H., Kim, H.M., Ko, J.S. (1998). Effect of dietary calcium deficiency on osteotropic hormones and biochemical markers of bone metabolism in the rabbit. *Bone,* **23,** SA340.

Krook, L., Lowe, J.E. (1964). Nutritional secondary hyperparathyroidism on the horse. *Pathologia Veterinaria,* **1(Supplement),** 1-93.

Lamb, C.R. (1990). The double cortical line: a sign of osteopenia. *Journal of Small Animal Practice,* **31,** 189-192.

Latour, M.A., Hopkins, D., Kitchens, T. and others. (1998). Effects of feeding a liquid diet for one year to New Zealand White rabbits. *Laboratory Animal Science,* **48,** 81-83.

Legendre, L.F. (2002). Malocclusions in guinea pigs, chinchillas and rabbits. *Canadian Veterinary Journal,* **43,** 385-390.

Lindsey, J.R., Fox, R.R. (1994). Inherited Diseases and Variations. In *The Biology of the Laboratory Rabbit 2nd Edition* (P.J. Manning, D.H. Ringler, C.E. Newcomer, eds.) pp. 293-313, Academic Press.

Listgarten, M.A., Kamin, A. (1969). The development of a cementum layer over the enamel surface of rabbit molars- a light and electron microscopic study. *Archives of oral Biology,* **14,** 961-985.

Lobprise, H.B., Wiggs, R.B. (1991). Dental and oral disease in lagomorphs. *Journal of Veterinary Dentistry,* **8,** 11-17.

Lozupone, E., Favia, A. (1989). Effects of a low calcium maternal and weaning diet on the thickness and microhardness of rat incisor enamel and dentine. *Archives of Oral Biology,* **34,** 491-498.

Lowe, J.A. (1998). Pet Rabbit Feeding and Nutrition. In *The Nutrition of the Rabbit.* (Eds. C. de Blas and J. Wiseman) CABI Publishing Cambridge, pp. 304-331.

Marcus, R.M. (1996). Physical activity and regulation of bone mass. In *Primer on the Metabolic Bone Diseases and Disorders of Mineral Metabolism.* Ed.M.J. Favus. Lippincott-Raven, Philadelphia, pp. 254-256.

McRoberts, M.R., Hill R., Dalgarno A.C. (1965). The effects of diets deficient in phosphorus, phosphorus and Vitamin D or calcium, on the skeleton and teeth of growing sheep. *Journal of Agricultural Science,* **65,** 1-18.

© Frances Harcourt-Brown 2006

Mellanby, M., Killick, E.M. (1926). A preliminary study of factors influencing calcification processes in the rabbit. *Biochemical Journal,* **20,** 902-926.

Meredith, A. Crossley, D.A. (2002). Rabbits. In *BSAVA Manual of Exotic Pets, 4th Edition.* Eds A. Meredith, S. Redrobe, BSAVA, Gloucester, pp 76-92.

Messer, H.H., Goebel, N.K., Wilcox, L. (1981). A comparison of bone loss from different skeletal sites during acute calcium deficiency in mice. *Archives of Oral Biology,* **26,** 1001-1004.

Michaeli, Y., Hirschfield Z., Weinreb M.M. (1980). The cheek teeth of the rabbit; Morphology, histology and development. *Acta Anatomica,* **106,** 223-239.

Morimoto, Y., Tanaka, T., Kito, S., Morimoto, A., Haneji, T., Kimura, M.T. (2000). Quantitative radiographic changes in the mandible and the tibia in sytemically loaded rats fed a low-calcium diet. *Oral Disease,* **6,** 310-317.

Morrison, N.A., Cheng Qi, J., Tokita, A., Kelly, P.J., Crofts, L., Nguyen, T.V., Sambrook, P.N., Eisman, J.A. (1994). Prediction of bone density from vitamin D receptor alleles. *Nature,* **367,** 284-287.

Murray, E.J., Messer, H.H., Alamoudi, N. (1982). Mandibular turnover during calcium deficiency in the rat. *Journal of Dental Research,* **61,** 1107-1109.

Myer, W. (1998). Cranial vault and associated structures. In *Textbook of Veterinary Diagnostic Radiology, 3rd Ed.* Ed. D.E. Thrall, W.B.Saunders, Philadelphia, p. 47.

Ness, A.R. (1956). The response of the rabbit mandibular incisor to experimental shortening and prevention of its eruption. *Proceedings of the Royal Society,* **146,** 129-154.

Norris, S.A., Pettifor, J.M., Gray, D.A., Biscardi, A., Buffenstein, R. (2000). Validation and application of dual-energy X-ray absorptiometry to measure bone mineral density in rabbit vertebrae. *Journal of Clinical Densitometry,* **3,** 49-55.

Norris, S.A., Pettifor, J.M., Gray, D.A., Buffenstein, R. (2001). Calcium metabolism and bone mass in female rabbits during skeletal maturation: effects of dietary calcium intake. *Bone,* **29,** 62-69.

Ohya, K., Amano, H., Ogura H. (1992). Alveolar bone resorption process in molar tooth region in calcium-deficient rats (Article in Japanese, English Abstract). *Kokubyo Gakkai Zasshi,* **59,** 585-593.

Ortega, R.M., Requejo, A.M., Encinas Sotillos, A., Andres, P., Lopez Sobana, A.M., Quintas, E. (1998). Implication of calcium deficiency in the progress of periodontal disease and osteoporosis (Article in Spanish). *Nutricion Hospitalaria,* **13,** 316-319.

Owen, R. (1868). Dental system of mammalia. In *The Anatomy and Physiology of Vertebrates, Volume III*. Longmans, Green and Co.London, pp. 299-301.

Page, K.M. (1977). Bone and preparation of bone sections. In *Theory and Practice of Histological Techniques.* (Eds. J.D. Bancroft, A. Stevens). Churchill Livingstone, New York, pp. 223-248.

Petrikowski, C.G., Overton, T.R. (1996). Quantitative radiographic changes in the mandible, femur and vertebrae in lactating rats fed a low calcium diet. *Dentomaxillofacial Radiology,* **25,** 136-145.

Peyer, B. (1968). *Comparative Odontology*. University of Chicago Press, Chicago, pp.293-298.

Popoff, S.N., Marks, S.C. (1990). Relationship of abnormalities in dental and skeletal development in the osteopetrotic (os) rabbit. *Journal of Oral Pathological Medicine,* **19,** 5-12.

© Frances Harcourt-Brown 2006

Pollock S. (1951). Slobbers in the rabbit. *Journal of the American Veterinary Medical Association,* **119,** 443-444.

Proffitt, W.R., Sellers, K.T. (1986). The effect of intermittent forces on eruption of the rabbit incisor. *Journal of Dental Research,* **65,** 118-122.

Rosol, T.J., Capen, C.C. (1997). Calcium-regulating hormones and diseases of abnormal mineral (calcium, phosphorus, magnesium) metabolism. In *Clinical Biochemistry of Domestic Animals 5th Edition,* Eds. J.J. Kaneko, J.W. Harvey, M.L. Bruss. Academic Press, San Diego, pp.619-702.

Sandford, J.C. (1996). *The Domestic Rabbit, 5th Edition*. Blackwell Science, p.265.

Schwartz, G., Enomoto, S., Valiquette, C., Lund, J.P. (1989). Mastication in the rabbit: a description of movement and muscle activity. *Journal of Neurophysiology,* **62,** 273-287.

Shadle, A.R. (1936). The attrition and extrusive growth of the four major incisor teeth of domestic rabbits. *Journal of Mammology,* **17,** 15-21.

Shoji, K., Ohtsuka-Isoya, M., Horiuchi, H., Shinoda, H. (2000). Bone mineral density of alveolar bone in rats during pregnancy and lactation. *Journal of Periodontology,* **71,** 1073-1078.

Shore, R.M., Poznanski, A.K. (1996). Radiographic evaluation of bone mineral in children. In *Primer on the Metabolic Bone Diseases and Disorders of Mineral Metabolism.* Ed.M.J. Favus. Lippincott-Raven, Philadelphia, pp.119-134.

Schwartz, G., Enomoto, S., Valiquette, C., Lund, J.P. (1989). Mastication in the rabbit: A description of movement and muscle activity. *Journal of Neurophysiology*, **62,** 273-287

Smith, B.S.W., Wright, H. (1984). Relative contributions of diet and sunshine to the overall vitamin D status of the grazing ewe. *Veterinary Record*, **115,** 537-538.

Spence, J.A. (1982). Studies into the pathogenesis of early tooth loss (broken mouth) in sheep. FRCVS Thesis, Royal College of Veterinary Surgeons, London.

Spence, J.A., Sykes, A.R., Atkinson, P.J., Aitchison, G.U. (1985). Skeletal and blood biochemical characteristics of sheep during growth and breeding: a comparison of flocks with and without broken mouth. *Journal of Comparative Pathology,* **95,** 505-524.

Steedle, J.R., Proffitt, W.R., Fields, H.W. (1983). The effects of continuously axially-directed intrusive loads on the erupting rabbit mandibular incisor. *Archives of Oral Biology,* **28,** 1149-1153.

Steenkamp, G., Crossley, D.A. (1999). Incisor tooth regrowth in a rabbit following complete extraction. *Veterinary Record,* **145,** 585-586

Suckling, G.W., Cutress, T.W., Healy, W.B., Mattingley, J. (1974). Effects of liming a highly leached soil on periodontal health, serum composition and body weight of sheep. *New Zealand Journal of Agricultural Research,* **17,** 311-316.

Swan, K.C., Salit, P.W. (1941). Lens opacities associated with experimental calcium deficiency. *American Journal of Ophthalomology,* **6,** 611-614.

Tan, S.Q., Thomas, D., Wellington, J.A.O., Bourdeau, J.E., Lau, K. (1987). Surgical thyroparathyroidectomy of the rabbit. *American Journal of Physiology,* **252**, F761-E767.

Teitelbaum, S.L. (1980). Pathological manifestations of osteomalacia and rickets. *Clinics in Endocrinology and Metabolism,* **9,** 43-62.

Terajima, T. (1989). Histological studies on the controlled eruption to the rabbit incisor (Article in Japanese, abstract in English). *Nichidai Koko Kagaku,* **15,** 276-294.

© Frances Harcourt-Brown 2006

Tremaine, H. (1997). Dental care in horses. *In Practice*, **19**, 186-199.

Tvedegaard, E. (1987).Arterial disease in chronic renal failure. An experimental study in the rabbit. *Acta Pathologica, Microbiologica, et Immunologica, Scandinavica. Section A. Supplement 290*, **95**, 3-28.

Underwood J.L., DeLuca H.F. (1984). Vitamin D is not directly necessary for bone growth and mineralisation. *American Journal of Physiology*, **246**, E493-E498.

Van Foreest, A.W. (1998). Dental problems in rabbits and rodents (Article in Dutch). *Tijdschrift voor Diergeneeskunde,* **123,** 698-713.

Wactawsli-Wende, J. (2001). Periodontal diseases and osteoporosis: associations and mechanisms. *Ann Periodontol.,* **6,** 197-208.

Warren, H.B., Lausen, N.C., Segre, G.V., El-Hajj, G., Brown, E.M. (1989). Regulation of calciotropic hormones in vivo in the New Zealand White rabbit. *Endocrinology*, **125,** 2683-2689.

Wasnich, R.D. (1996). Epidemiology of osteoporosis. In *Primer on the Metabolic Bone Diseases and Disorders of Mineral Metabolism.* Ed.M.J. Favus. Lippincott-Raven, Philadelphia, pp.249-251.

Weijs, W.A., De Jongh, H.J. (1977). Strain in mandibular alveolar bone during mastication in the rabbit. *Archives of Oral Biology,* **22,** 667-675.

Weijs, W.A., Dantuma, R. (1981). Functional anatomy of the masticatory apparatus in the rabbit (*Oryctolagus cuniculus* L.). *Netherlands Journal of Zoology,* **31,** 99-147.

Weijs, W.A., Korfage, J.A.M., Langenbach, G.F. (1989). The functional significance of the position of the centre for jaw opening and closing in the rabbit. *Journal of Anatomy,* **162,** 133-148.

Weisbroth, S.H., Ehrman, L. (1967). Malocclusion in the rabbit; A model for the study of the development, pathology and inheritance of malocclusion. I. Preliminary note. *Journal of Heredity,* **58,** 245-246.

Westerhof. I., Lumeij, S.J. (1987). Dental problems in rabbits, guinea pigs and chinchillas. *Tijdschrift voor Diergeneeskunde*, **12,** 6S-10S.

Whiting, S.J., Quamme, G.A. (1984). Effects of dietary calcium on renal calcium, magnesium and phosphate excretion by the rabbit. *Mineral and Electrolyte Metabolism*, **10,** 217-221.

Wiggs, R.B., Lobprise, H. (1995). Dental Anatomy and Physiology of Pet Rodents and Lagomorphs. In *Manual of Small Animal Dentistry. 2nd Edition. (*Eds. D.A. Crossley and S. Penman). British Small Animal Veterinary Association, Cheltenham, pp. 68-73.

Wiggs, R.B., Lobprise, H. (1995a). In Oral diagnosis in Pet Rodents and Lagomorphs. In *Manual of Small Animal Dentistry. 2nd Edition. (*Eds. D.A. Crossley and S. Penman). British Small Animal Veterinary Association, Cheltenham, p.79.

Wiggs, R.B., Lobprise, H. (1997). Dental and oral disease in rodents and lagomorphs. In *Veterinary Dentistry Principles and Practice.*Eds. R.B.Wiggs, H. Lobprise. Lippincott-Raven, Philadelphia, pp. 518-539.

Woodward, J.C. (1997). Skeletal system. In *Veterinary Pathology.* Eds T.C. Jones, R.D. Hunt, N.W. King. Williams & Wilkins, Baltimore, pp. 873-898.

Wu, D.D., Boyd, R.D., Fix, T.J., Burr, D.B. (1990). Regional patterns of bone loss and altered bone remodelling in response to calcium deprivation in laboratory rabbits. *Calcified Tissue International,* **47,** 18-23.

© Frances Harcourt-Brown 2006

Yang, K.H., Stewart, A.F. (1996). Miscellaneous causes of hypercalcaemia. In *Primer on the Metabolic Bone Diseases and Disorders of Mineral Metabolism.* Ed.M.J. Favus. Lippincott-Raven, Philadelphia, pp. 213-217.

Yamada, Y., Yamamura, K. (1996). Possible factors which may affect phase durations in the natural chewing rhythm. *Brain Research,* **706,** 237-242.

Zeman W.V., Fielder F.G. (1969). Dental malocclusion and overgrowth in rabbits. *Journal of the American Veterinary Medical Association,* **155,** 1115-1119.

© Frances Harcourt-Brown 2006

GLOSSARY

Diagram to illustrate nomenclature of direction

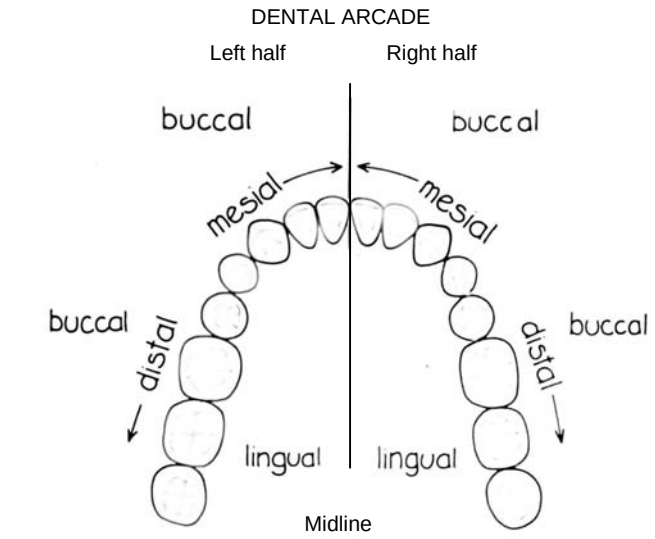

`

Schematic view of crown (from above i.e. occlusal view) to show nomenclature of surfaces of teeth

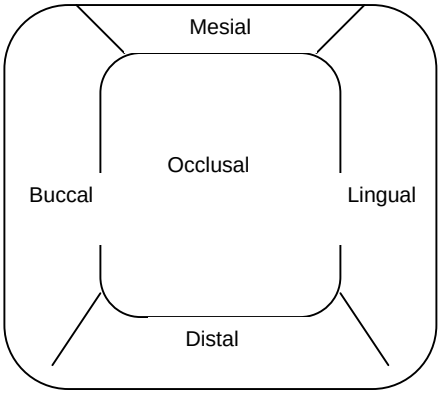

There are five surfaces of the crown: occlusal, buccal, lingual, mesial, and distal. These terms refer to the direction that the surface is facing and are usually self-explanatory e.g. the buccal surface faces towards the buccal mucosa lining the cheek or lips. However, some texts refer to this surface as the 'vestibular surface' or 'labial surface'.

© Frances Harcourt-Brown 2006

Definition of terms

Alveolus: Bony socket in the jaw in which the tooth is embedded.

Ameloblast: Enamel forming cell.

Amelogenesis: Formation of enamel.

Apex: The extremity of the tooth that is embedded in the bone.

Buccal surface: The surface of the crown that faces towards the lips or cheek. Also known as buccal or vestibular surface.

Calcifediol: (25-hydroxycholecalciferol, 25(OH)D, 25-dihydroxyvitamin D): a metabolite of vitamin D that is formed and stored in the liver. There is a negative feedback controlling the conversion of provitamins (vitamin D_2 and D_3) to 25(OH)D

Calcitriol: ($1,25(OH)_2D$, 1,25-dihydroxycholecalciferol, 1,25-dihydroxyvitamin D): The active metabolite of vitamin D that is formed in the kidney from 25(OH)D under the influence of parathyroid hormone (PTH) that is released in response to low serum calcium concentrations.

Cementum: A bone like connective tissue that helps to anchor the tooth in the socket.

Crown: The part of the tooth that protrudes into the mouth.

Dacryocystitis: Inflammation of the lacrimal sac

Dental arcade: The entire row of teeth that are aligned in the shape of arch. There is a lower arcade and upper arcade.

Distal: Away from the midline of the dental arcade

Distal surface: The surface of the tooth that faces away from the midline of the dental arcade.

Enamel: Compact crystalline substance that is very hard.

Enamel hypoplasia: A defect of matrix production that results in enamel that contain lines, grooves or pits on its surface.

Ergosterol: A sterol that occurs in plants. It is converted to vitamin D_2 under exposure to ultraviolet light.

Hemimandible: One of two bones that are mirror images of one another that are joined by a symphysis to form the lower jaw or mandible.

Howship's lacunae: Microscopic indentations in the surface of bone that contain osteoblasts.

Hydroxyapatite: Hydrated calcium phosphate ($Ca_{10}(PO_4)_6OH_2$. A crystalline substance that imparts rigidity to bone and teeth.

Incisive bone: The bone bearing the incisors. May also be called the premaxilla.

Incisors: The central teeth of the dental arcade that are used for incising or cutting.

Labial surface: The surface of the crown that faces towards the lips. Also known as buccal or vestibular surface.

Lamina dura: Layer of dental alveolar bone containing more than usual amounts of highly calcified cementing substance, associated with periodontal fibres in the bone. It causes a line of increased radiodensity in dental radiographs.

Lingual surface: The surface of the tooth that faces towards the tongue.

Mandible: Horseshoe-shaped bone that forms the lower jaw. It consists of two hemimandibles joined at the midline by a symphysis.

Maturation (of enamel): Part of enamel production where amelogenin is removed from the organic matrix and replaced with apatite to produce heavily mineralised mature enamel.

© Frances Harcourt-Brown 2006

Maxilla: One of two identical bones that form the upper jaw. The maxillae form the floors of the orbits, the sides and lower walls of the nasal cavities and the hard palate. The upper cheek teeth are embedded in the lower border of the maxillae.

Maxillary sinus: An air filled space in the maxilla.

Mesial: Towards the midline of the dental arcade

Mesial surface: The surface of the tooth that faces towards the midline.

Molariform teeth: The cheek teeth. Because of the similarity between premolars and molars, the cheek teeth are sometimes referred to as the 'molariform teeth'.

NLD: nasolacrimal duct.

Nutritional secondary hyperparathyroidism: High levels of circulating parathyroid hormone (PTH) triggered by a fall in blood calcium levels due to nutritional disorders. Dietary calcium deficiency or impaired absorption due to inadequate vitamin D are causes. Imbalances of calcium and phosphorus in the diet will also case nutritional secondary hyperparathyroidism.

Occlusion: refers to the manner in which teeth from the upper and lower dental arcades meet each other.

Occlusal surface: The surface of the crown that meets the opposing tooth.

Odontoblast: Dentine forming cell

Osteoblast: Bone cells that produce osteoid and regulate its mineralisation

Osteoclast: Bone cells that resorb mineralised osteoid.

Osteocyte: An osteoblast that has lost its secretory capacity and has become embedded within the bone matrix.

Osteodystrophy: diseases of bone in which there is failure of normal development or abnormal metabolism in bone that is already mature.

Osteomalacia: softening of the bones of adult animals, resulting from impaired mineralisation, with excess accumulation of osteoid.

Osteoid: The organic matrix of bone. It is mainly composed of collagen

Osteopaenia: reduced bone mass due to a decrease in the rate of osteoid synthesis to a level insufficient to compensate for normal bone lysis.

Osteopetrosis: massive, diffuse increase in radio-opacity of the skeleton.

Osteoporosis: a pathological loss of bone but the remaining bone is structurally normal.

Parathyroid hormone (PTH): A hormone produced by the parathyroid glands that stimulates osteoclastic activity and the resorption of bone to release calcium.

Periodontal ligament: A complex of fibres, composed of connective tissue, that are embedded in the cementum and alveolar bone and anchor the tooth within the socket.

Peg teeth: Small pair of second upper incisors situated immediately caudal to the large first maxillary incisors.

Premaxilla: The incisive bone that contains the upper incisor teeth.

PSADD: A progressive syndrome of acquired dental disease that affects pet rabbits.

Pulp cavity: A cavity in the centre of the tooth that contains the nerve and blood supply.

Root: The part of the tooth that is embedded in the jaw.

Vestibular surface: The surface of the tooth that faces towards the *vestibulum oris*, i.e. the space between the teeth and cheek or lips. Also known as buccal or labial surface.

Vitamin D: A group of closely related steroids with anti-rachitic properties.

© Frances Harcourt-Brown 2006

Vitamin D_2: (Ergocalciferol, calciferol): An exogenous provitamin formed from ergosterol in plants when they are exposed to ultraviolet light. Vitamin D_2 is converted to 25(OH)D in the liver.

Vitamin D_3: (Cholecalciferol): An endogenous provitamin that is converted to 25(OH)D in the liver.

25(OH)D: (25-hydroxycholecalciferol, calcifediol, 25-dihydroxyvitamin D): a metabolite of vitamin D that is formed and stored in the liver. There is a negative feedback controlling the conversion of provitamins (vitamin D_2 and D_3) to 25(OH)D

25-dihydroxyvitamin D: See 25(OH)D

25-hydroxycholecalciferol: See 25(OH)D

1,25$(OH)_2$D: (1,25-dihydroxycholecalciferol, calcitriol, 1,25-dihydroxyvitamin D): The active metabolite of vitamin D that is formed in the kidney from 25(OH)D under the influence of parathyroid hormone (PTH) that is released in response to low serum calcium concentrations.

1,25-dihydroxycholecalciferol: See 1,25$(OH)_2$D

1,25-dihydroxyvitamin D: See 1,25$(OH)_2$D

7-dehydrocholesterol: A derivative of chlolesterol that is metabolised to vitamin D_3 in skin exposed to ultraviolet light

© Frances Harcourt-Brown 2006

Appendix 1: Grading system for the progression of clinical signs in rabbits suffering from the progressive syndrome of acquired dental disease (PSADD)

Grade 1: Clinically healthy

Grade 2: Rabbits presented for reasons other than dental disease but in which dental abnormalities were detected, such as palpable root elongation of the lower cheek teeth, epiphora due to elongation of the upper first incisors, minor irregularities of the occlusal surfaces of the teeth or horizontal ribbing of the incisors.

Grade 3: Rabbits presented because of malocclusion of the incisors or because of problems relating to sharp spurs that were present on the cheek teeth. Problems included anorexia, eating difficulties, salivation or grooming problems.

Grade 4: Rabbits with discoloured, misshapen crowns and evidence that most or all the teeth were no longer growing from repeated visual examination or from radiological evidence that pulp cavities were closed. In many cases, these rabbits were eating well although some had grooming difficulties because of absent or non-occluding incisors. There may have been longstanding epiphora or dacryocystitis.

Grade 5: These rabbits had few or no functional crowns on their teeth although there may have been remnants of exposed crowns. Affected rabbits were usually thin and could only eat softened food.

© Frances Harcourt-Brown 2006

Appendix 2: Classification of Incisor Occlusion

Class 1: Normal:

The tip of the lower incisor rests against the upper peg tooth but is not in contact with upper primary incisor

Class 2: Contact between primary incisors

The tip of the lower incisor rests against the upper primary incisor preventing full closure of the mouth

Class 3: Edge to edge contact

The occlusal surfaces of the upper primary incisor are in full contact with lower incisor

Class 4: Slight protusion of lower incisors

The anterior surface of the lower incisor is no longer in contact with the upper primary incisor

Class 5: Partial overgrowth of lower incisor

The whole occlusal surface of the lower incisor is no longer in wear and develops a sliver that continues to grow

Class 6: Overgrowth of both upper and lower incisors but still in contact

The upper incisors are in contact but are elongated and curled

Class 7: Complete malocclusion

The upper and lower incisors are no longer in contact so the upper teeth curl outwardly and the lower teeth grow forward

Class 8: Cessation of tooth growth and broken crown

Eventually the teeth stop growing. The crowns may break off or may be trimmed to leave stumps

Class 9: Root resorption

In extreme cases, the remnants of the crowns break off altogether and the roots resorb

Unclassified: Incisors have been removed

Surgical removal of incisors may be carried out because of congenital or acquired malocclusion

Measurements of hemimandibles of 19 wild rabbits

	A: Length of hemimandible	B: Height of condyle	C: Width of mandibular body
1	55.7mm	35.8mm	4.8mm
2	52.8mm	35.1mm	4.7mm
3	62.5mm	40.5mm	6.6mm
4	57.1mm	33.5mm	4.1mm
5	57.0mm	32.6mm	4.8mm
6	57.9mm	34.9mm	4.9mm
7	58.3mm	34.7mm	4.0mm
8	54.4mm	34.4mm	5.0mm
9	59.7mm	35.1mm	4.0mm
10	55.0mm	35.8mm	4.2mm
11	49.7mm	31.5	4.0mm
12	56.1mm	33.8mm	4.3mm
13	44.8mm	3.8mm	3.8mm
14	58.8mm	36.1mm	4.6mm
15	52.2mm	32.5mm	3.7mm
16	55.00mm	35.0mm	4.8mm
17	50.00mm	31.4mm	4.1mm
18	56.1mm	34.0mm	4.4mm

© Frances Harcourt-Brown 2006

Bone ash analysis results

	Number	Age	Grade	Bone Ca%	Bone P%	Bone Mg%	Bone Ash%
MANDIBLE							
	1[a]	6	1	36.4	21.36	1.09	72.4
	2[b]	11	1	36.4	21.09	0.88	72.4
	3[c]	5	3	41.28	19.7	1.00	71.74
FEMUR							
	1[a]	6	1	43.68	20.81	0.66	67.8
	2[b]	11	1	43.92	20.25	0.66	67.7
	3[c]	5	3	40.08	19.94	0.61	61.91
	4	5	4	34.92	15.54	0:0	66.65
	5	1	1	46.56	21.74	0.66	65.01
	6	?	5	25.68	13.38	0.41	68.46
	7	11	5	35.76	17.09	0.53	68.98
	8	5	5	25.92	12.82	0.41	74.07
	9Wild	<1	1	35.04	17.65	0.71	73.9
	10	5	1	36.24	16.91	0.61	67.75
	11	6	1	39.84	17.28	0.61	66.64
	12	?	4	30.48	13.94	0.58	62.61
	13	?	1	54.48	23.23	0.95	62.77
	14	4	1	41.04	21.37	0.66	63.46
	15	?	3	36.48	18.77	0.24	69.83
	16	2	1	35.28	17.47	0.58	67.78
	17	9m	1	37.2	18.77	0.73	67.86
	18	2	1	33.12	15.98	0.56	74.89
	19	1	1	33.36	15.98	0.54	71.11
	20	10m	2	28.56	14.12	0.44	71.84
	21	18m	4	36.72	17.47	0.66	63.8
	22	18m	4	36.96	17.09	0.66	67.61
	23	5	1	35.52	16.35	0.56	70.8
	24[d]	3	5	34.32	16.16	0.61	60.18
AXIS							
	1[d]	3	5	32.16	14.86	.51	60.63
	2	?	1	9.36	18.2	.66	64.04
	3	1	3	40.8	20.1	.53	56.4
	4	2	5a	45.1	18.0	.53	67.2
	5	?	5a	48.2	19.7	.51	62.7
	6	2	5	39.1	15.6	.56	67.9
	7	3	1	42.7	18.8	.68	66.8
	8	6	4	38.16	19.14	.58	58.33
	9	2	3	35.28	17.84	.41	55.81
	10	4	1	38.6	16.2	.51	70.3

Superscript letter denotes samples taken from same rabbit

Calcium, magnesium and phosphate figures are percentage of bone ash

© Frances Harcourt-Brown 2006

Grade of acquired dental disease along with breed, age and gender details of rabbits from which skulls were prepared

	Total	Without Dental Disease	With Dental Disease	Wild	Grade 1	Grade 2	Grade 3	Grade 4	Grade 5
TOTAL NUMBERS	172	55	117	19	36	40	23	33	21
Gender									
Unknown	60	20	40	12	8	13	8	14	5
M	64	16	48	4	12	14	12	12	10
F	50	19	29	3	16	13	3	7	6
Breed:									
Unknown	34	2	32		2	11	8	10	3
Known	138	53	85		34	29	15	23	18
Wild	19	19		19					
Mixed	19	4	15		4	5	1	7	2
Dwarf Lop*	40	8	32		8	15	5	7	5
Neth Dwarf*	20	9	11		9	2	2	3	4
Dutch	17	8	9		8	3	1	2	3
Angora	3		3			1		2	
English	8	1	7		1	2	2	2	1
Himalayan	1	1			1				
Satin			1						1
Rex	2		2			1	1		
New Zealand	6	3	3		3			1	2
Giant	1		1				1		
French Lop	2		2				2		
Dwarf breeds		17	43						
Non dwarf		17	43						
Age:									
Unknown				6	14	11	5	11	3
<1yo				13	2	4			
1y					4	13	1	1	
2y					3	6	3	6	1
3y					2	2	7	6	3
4y					3	4	4	4	4
5y					3			2	6
6y					2			3	2
7y							1		
8y					1		1		
9y									
> 10y					1		1		2

© Frances Harcourt-Brown 2006

Results of morphological examination of prepared skulls

* Congenital malocclusion
DO: Double optic foramen (see Figure 23)
FB Foreign body
FM: Abnormal foramen magnum
CRF: Rabbits with chronic renal failure

	Wild	Grade 1	Grade 2	Grade 3	Grade 4	Grade 5
Total: 172	19	36	40	23	33	21
Loose teeth (wide interdental space)	0	5	30	19	33	12
Alignment:						
Straight	19	35	15	2		
Curved		1	14	4	10	
Misaligned			11	17	15	6
Deformed					8	15
Ribbed incisors	0	0	20	15	14	
Changes to roots:						
Elongation	0	7	20	9	3	4
Penetration	0	3	13	15	19	14
Dystrophic calcification	0	0	0	0	1	10
Root elongation:						
Upper 1st incisors		1	20	5	3	2
Upper 1st premolar				1		
Upper 2nd premolar			4	9	3	4
Upper 3rd premolar		6	1	5	1	3
Upper 1st molar		7	5	2	2	4
Upper 2nd molar			2		1	3
Lower incisor		1	1	4	3	1
Lower 1st premolar						2
Lower 2nd premolar			2	3	1	2
Lower 1st molar			7	4		2
Lower 2nd molar			8	4		
Lower 3rd molar						
Root penetration:						
Upper 1st incisors			5	2	12	14
Upper 1st premolar				7	4	1
Upper 2nd premolar		2	5	6	8	8
Upper 3rd premolar		1	4	13	17	6
Upper 1st molar			9	15	19	8
Upper 2nd molar			11	14	15	6
Lower incisor		1	2	4	6	4
Lower 1st premolar		1	8	12	10	3
Lower 2nd premolar		1	1	8	10	7
Lower 1st molar			2	8	17	10
Lower 2nd molar		3	13	14	12	10
Lower 3rd molar					8	4

© Frances Harcourt-Brown 2006

	Wild	Grade 1	Grade 2	Grade 3	Grade 4	Grade 5
Total: 172	19	36	40	23	33	21
Root calcification:						
Upper 1º incisors					1	2
Upper 1st premolar						7
Upper 2nd premolar					1	10
Upper 3rd premolar					1	9
Upper 1st molar					1	6
Upper 2nd molar						1
Lower incisor						
Lower 1st premolar						
Lower 2nd premolar						4
Lower 1st molar						4
Lower 2nd molar						2
Lower 3rd molar						2
Incisor occlusion:						
1	19	36	22	3	11	1
* cheek teeth and incisors not in occlusion together	(17)	(6)	(2)			
2			8	3	5	1
3			3	4	4	3
4			4	6	3	1
5			3			
6				2	2	3
7				2	4	4
8				3	4	5
9						4
Porosity of parietal bone	1	12	14	7	12	9
Hole near angular process	18	25	25	18	13	9
White bone	17	15	5	6	3 (CRF)	2 (CRF)
Yellow/oily bone	2	21	35	17	30	19
Visible thinning of bone around upper incisor	0	2	14	7	19	17
Visible thinning of bone around lower incisor	0	2	10	5	14	15
Thin cribriform bone	0	7	29	23	12	10
Dilated nasolacrimal canal	0		21	13	11	17
Thin incisive bone	0		18	11	19	21
Thin bone on condyle	0	3	18	20	30	20
Abscess		1(FB)	4	2	8	6
Abnormal foramina					3 (DO)	3 (DO) 2 (FM)

© Frances Harcourt-Brown 2006

Results of examination of skull radiographs

Hemimandibles without teeth

	Wild **13**	**Grade 1** **11**	**Grade 2** **16**	**Grade 3** **12**	**Grade 4** **7**
Line of lamina dura at apical end of socket	13	5	0	0	0
Socket extending into ventral mandibular cortex- none through	0	1	15	11	5
One or more sockets extending through ventral mandibular cortex	0	0	0	1	2
Blurred indistinct line of lamina dura	1	1	3	12	7
Merged sockets	0	0	0	3	3
Generalised radiolucency	0	0	0	3	4

Dorsoventral view of skull without mandibles or teeth

	Wild **4**	**Grade 1** **5**	**Grade 2** **8**	**Grade 3** **5**	**Grade 4** **4**
Defined line of lamina dura showing notch in which the longitudinal groove in the tooth fits	4	3	1	0	0
Blurred indistinct line of lamina dura	0	2	3	4	4
Merged sockets	0	1	2	3	4

© Frances Harcourt-Brown 2006

Hemimandibles with teeth

	Wild (17)	Grade 1 (15)	Grade 2 (12)	Grade 3 (10)	Grade 4 (9)	Grade 5 (14)
Well defined longitudinal enamel fold in centre of teeth	17	15	1	0	0	0
Line of lamina dura at apical end of socket	17	5	0	0	0	0
Teeth extending into ventral mandibular cortex (none through)	0	4	4	5	6	14
One or more teeth extending through ventral mandibular cortex	0	9	0	5	3	4
Blurred indistinct line of lamina dura	0	4	8	9	9	14
Blurred indistinct line of longitudinal enamel fold (none with waves or with no enamel fold)	0	2	9	4	1	0
Waves or bends in the line of the longitudinal enamel fold (none with no enamel fold)	0	2	1	3	2	3
No longitudinal enamel fold	0	0	0	3	6	14
Deformed bent teeth	0	1	1	7	9	14
Remnants of roots without crowns	0	0	0	0	0	5
Closed pulp cavities	0	0	0	2	9	14
Generalised radiolucency	0	0	0	1	2	14

© Frances Harcourt-Brown 2006

Skull radiographs

Breakdown of examination of radiographs of skulls of 315 pet rabbits(230 cases with 2 views: lateral and dorsoventral, 85 cases of lateral view only)

	Grade 1		**Grade 2**		**Grade 3**		**Grade 4**		**Grade5**	
	Number of radiographs examined		Number of radiographs examined		Number of radiographs examined		Number of radiographs examined		Number of radiographs examined	
	Lateral (49)	+DV (39	Lateral (82)	+DV (55)	Lateral (70)	+DV (50)	Lateral (73)	+DV (57)	Lateral (41)	+DV (29)
Total number of radiographs examined	49	39	82	55	70	50	73	57	41	29
Convergance on lateral	12		9		12		4		2	
Incisor occlusion										
Grade 1	46		65		7		4			
* cheek teeth and incisors not in occlusion together	(0)		(0)		(0)		(0)			
Grade 2			14		21		15		5	
Grade 3					16		14		3	
Grade 4			1		2		5		3	
Grade 5					3		4		6	
Grade 6					4		4		2	
Grade 7	3				11		7		3	
Grade 8					1		10		8	
Grade 9							10		10	
Surgically removed			2		5				1	
Upper Prim Incisor:	0		42		54		67		39	
Root elongation	0		20		23		29		10	
Ribbing	0		10		3		1		0	
+ root elongation	0		0		0		0		10	
- root elongation	0		6		19		33		22	
Calcif/deformd roots										
Closed pulp cavity										
Occlusal line of cheek teeth on lateral view:										
Zig Zag	48		60		19		2		0	
Uneven	1		22		50		60		4	
Broken deformed crowns	0		0		1		2		24	
Calcified							7		7	
Visible spurs									6	
Crown elongation of cheek teeth (impression)	0		20		18		9		0	

© Frances Harcourt-Brown 2006

	Grade 1		**Grade 2**		**Grade 3**		**Grade 4**		**Grade5**	
	Number of radiographs examined		Number of radiographs examined		Number of radiographs examined		Number of radiographs examined		Number of radiographs examined	
	Lateral (49)	+DV (39	Lateral (82)	+DV (55)	Lateral (70)	+DV (50)	Lateral (73)	+DV (57)	Lateral (41)	+DV (29)
Cheek teeth roots										
Elongated roots	0		82		70		73		41	
Loss of parallel line effect	0		22		50		73		41	
Blurred roots	0		7		20		51		37	
Deformed misshapen roots	0		4		16		46		26	
Calcified roots	0						1		7	
Resorbed roots	0						4		6	
Appearance of rostral surface of first premolars:										
Smooth	49		73		41		23		2	
Ribbed			3		5		4		4	
Spurs			1		5		6			
Caries			2		6		8		2	
Broken			3		7		25		30	
Deformed					5		3		8	
Calcified					1		1		2	
Root of upper premolar 2 on DV:		38		38		22		3		0
Encircled by alveolar bone		0		30		34		37		11
Elongated		0		16		17		57		29
Penetrated bone		0		0		3		10		20
Deformed		0		0		0		5		6
Calcified										
Alveolar bulla:										
Clear line of bone	25		0		0		0		0	
Inconclusive	24		57		44		2		0	
Elongated roots	0		5		0		0		0	
Penetrated roots	0		20		31		43		17	
Penetrated and elongated	0				4		24		27	
Calcified roots					3		13		13	
Apex of lower 1st molar root										
Lucency of bone	3		56		49		49		26	
Loss of contrast:										
Thin incisive bone	3		26		37		63		39	
Density ↓-condyle	0		13		17		49		23**	
Density ↓-zygoma		0		13		24		41		26

© Frances Harcourt-Brown 2006

	Grade 1		**Grade 2**		**Grade 3**		**Grade 4**		**Grade5**	
	Number of radiographs examined		Number of radiographs examined		Number of radiographs examined		Number of radiographs examined		Number of radiographs examined	
	Lateral (49)	+DV (39	Lateral (82)	+DV (55)	Lateral (70)	+DV (50)	Lateral (73)	+DV (57)	Lateral (41)	+DV (29)
Abscessation:	0		5		8		18		24	
History:										
Tooth clipping							3		2	
Tooth burring							3		4	
Not known							6		11	
UPM1							1			
UPM2					2		2		2	
Retrobulbar					1		1		3	
LPM1/2			2		4		6		7	
LM2			3		3		4		5	
Generalised mandibular							4		7	

** 4 skulls showed increased density of condyle (see Figures **). All these rabbits showed increased mineralisation of the skeleton (see Figures**). One was a suspect Vitamin D toxicity. The other 3 showed signs of chronic renal failure. (increased blood urea and creatinine. Confirmed by histopath)

© Frances Harcourt-Brown 2006

Breeds of rabbits with and without acquired dental disease

BREED	With dental disease	Without dental disease	Total
Dwarf Lop	176	261	437
Dutch	48	54	102
New Zealand	9	9	18
Silver Fox	4	13	17
English	48	85	133
Netherland Dwarf	41	73	114
Tan		2	2
Minilop	19	42	61
Rex	6	10	16
Wild		3	3
Wild cross		5	5
Californian		2	2
Himalayan	2	3	7
English Giant		1	1
French Lop	12	4	16
English Lop		1	1
Chinchilla Gigantica	1	1	2
Vienna Blue		2	2
Beveran		2	2
Angora	7	25	32
Alaska		1	1
Belgian Hare		1	1
Polish		1	1
Giant Papillon		1	1
Minirex		1	1
Lionhead	3	7	10
Rhinelander	1	4	5
Satin	10	15	25
Mixed/unknown	80	158	236
TOTAL	465	789	1254

TOTAL: 1254

© Frances Harcourt-Brown 2006

Supporting papers:

(previous publications by the author relevant to this thesis)

1) Harcourt-Brown, F.M. (1995). A review of clinical conditions in pet rabbits associated with their teeth. *Veterinary Record,* **137,** 341-346. (* **** This paper was given the 1996 BVA's William Hunting award for the best paper by a general practitioner published in the Veterinary Record during 1995-1996).***

2) Harcourt-Brown, F.M. (1996). Calcium deficiency, diet and dental disease in pet rabbits. *Veterinary Record,* **139,** 567-571.

3) Harcourt-Brown, F.M. (1997). Diagnosis, treatment and prognosis of dental disease in pet rabbits. *In Practice,* **19,** 407-421.

4) Fairham J., Harcourt-Brown F.M. (1999). Preliminary investigation of the vitamin D status of pet rabbits. *Veterinary Record*, **145**, 452-454.

5) Harcourt-Brown, F.M., Baker, S.J. (2001). Parathyroid hormone, haematological and biochemical parameters in relation to dental disease and husbandry in pet rabbits. *Journal of Small Animal Practice,* **42,** 130-136. ***(** This paper was given the 2002 BSAVA's Dunkin award for the best paper by a general practitioner published in the Journal of Small Animal Practice during 2000-2001.)***

© Frances Harcourt-Brown 2006